



1966

## A Method of Physical Assessment of the Translatory Movement of a Posterior Tooth of a Rhesus Monkey

Jerry F. Lerch  
*Loyola University Chicago*

Follow this and additional works at: [https://ecommons.luc.edu/luc\\_theses](https://ecommons.luc.edu/luc_theses)



Part of the [Medicine and Health Sciences Commons](#)

---

### Recommended Citation

Lerch, Jerry F., "A Method of Physical Assessment of the Translatory Movement of a Posterior Tooth of a Rhesus Monkey" (1966). *Master's Theses*. 2090.

[https://ecommons.luc.edu/luc\\_theses/2090](https://ecommons.luc.edu/luc_theses/2090)

This Thesis is brought to you for free and open access by the Theses and Dissertations at Loyola eCommons. It has been accepted for inclusion in Master's Theses by an authorized administrator of Loyola eCommons. For more information, please contact [ecommons@luc.edu](mailto:ecommons@luc.edu).



This work is licensed under a [Creative Commons Attribution-Noncommercial-No Derivative Works 3.0 License](#).  
Copyright © 1966 Jerry F. Lerch

A METHOD OF PHYSICAL ASSESSMENT OF THE TRANSLATORY  
MOVEMENT OF A POSTERIOR TOOTH OF A RHESUS MONKEY

by

Jerry F. Lerch

A Thesis Submitted to the Faculty of the Graduate School  
of Loyola University in Partial Fulfillment of  
the Requirements for the Degree of  
Master of Science

JUNE

1966

LOYOLA UNIVERSITY MEDICAL CENTER

## LIFE

Jerry F. Lerch was born in Chicago, Illinois, May 9, 1929. He was graduated from Harrison High School in Chicago, Illinois in June, 1947. He began his pre-dental studies at the University of Illinois, Navy Pier, Chicago in September, 1947, and completed one year. He enlisted in the U.S. Navy in August, 1948, and served four years. He continued his studies at Loyola University, Chicago in September, 1952.

He entered the Loyola University School of Dentistry, Chicago in September, 1954, and received the Degree of Doctor of Dental Surgery in June, 1958.

He practiced general dentistry in Downers Grove, Illinois for six years. He began graduate studies in the Department of Oral Biology at Loyola University, Chicago in June, 1964.

## ACKNOWLEDGEMENTS

I wish to express my sincere appreciation to all those who have contributed to the making of this thesis, particularly to the following:

To Joseph R. Jarabak, D.D.S., Ph.D., Professor in Orthodontics, Loyola University, my teacher and advisor, for his guidance in preparing this thesis.

To James A. Fizzell, B.S. in E.E., my teacher in analytical mechanics and advisor, for his personal interest and the many hours he spent in designing and guiding the investigation for this thesis.

To Joseph Gowgiel, D.D.S., Ph.D., my thesis advisor, for his technical assistance in handling and sacrificing the experimental animals.

To Harold Arai, D.D.S., my classmate and thesis partner, without whose assistance this investigation would have been immeasurably more difficult.

To Dorothy, my wife, for her patience, understanding and clerical assistance in preparing this thesis.

## TABLE OF CONTENTS

Chapter	Page
I. INTRODUCTION AND STATEMENT OF THE PROBLEM:	
A. Introductory Remarks. . . . .	1
B. Statement of the Problem. . . . .	2
II. REVIEW OF THE LITERATURE. . . . .	4
III. METHODS AND MATERIALS:	
A. Animal Selection. . . . .	11
B. Animal Housing and Care . . . . .	12
C. Animal Handling . . . . .	12
D. General Anesthesia. . . . .	13
E. Selection of Teeth for Movement . . . . .	13
F. Stereotaxic Instrument for Radiographic Records . . . . .	16
G. Preparation of the Experimental Animal. . . . .	19
H. Force System Design and Force Magnitude Determination . . . . .	23
I. Appliance Design. . . . .	24
J. Appliance Construction. . . . .	25
K. Appliance Cementation and Activation. . . . .	32
L. Animal Sacrifice and Perfusion. . . . .	32
M. Analysis of the Force System. . . . .	35
N. Method of Assessing Tooth Movement. . . . .	41
IV. FINDINGS:	
A. Reducing the Data . . . . .	48
B. Testing the Stability of the Anchor Unit Points. . . . .	48
C. Gross Interpretation of the Data. . . . .	51
D. Analysis of Variance. . . . .	58
E. Gross Interpretation of the Radiographs . . . . .	68
V. DISCUSSION. . . . .	77
VI. SUMMARY AND CONCLUSIONS:	
A. Summary . . . . .	86
B. Conclusions . . . . .	87
VII. BIBLIOGRAPHY. . . . .	89

## LIST OF FIGURES

Figure	Page
1. FRONTAL VIEW (A) AND LATERAL VIEW (B) OF A DRY SKULL OF A RHESUS MONKEY. . . . .	14
2. ANIMAL HEADHOLDER AND X RAY ORIENTING DEVICE FOR LATERAL RADIOGRAPHS (A) AND OCCLUSAL RADIOGRAPHS (B) . . . . .	18
3. INTRADRAL PHOTOGRAPHS OF THE FRONTAL VIEW (A) AND LATERAL VIEW (B). . . . .	20
4. ANIMAL PREPARED FOR EXPERIMENT - RIGHT SIDE (A) AND LEFT SIDE (B) . . . . .	21
5. ANESTHETIZED ANIMAL POSITIONED IN STEREOTAXIC INSTRUMENT. . . . .	22
6. PASSIVE COMPONENT OF THE APPLIANCE ON WORKING MODEL . . . . .	26
7. DIAGRAM OF THE ACTIVE ELEMENT WITH DIMENSIONS IN MILLIMETERS . . . . .	28
8. LOAD-DEFLECTION TESTING APPARATUS . . . . .	30
9. LOAD-DEFLECTION CHARACTERISTIC. . . . .	31
10. DEACTIVATED APPLIANCE . . . . .	33
11. ANIMAL WITH THE MITTEN-LIKE RESTRAINTS. . . . .	34
12. FREE BODY DIAGRAMS. . . . .	37
13. DIAGRAM WITH DIMENSIONS FOR THE DETERMINATION OF THE MAGNITUDE OF THE COUPLE $F_t - F_t$ . . . . .	40
14. PHOTOGRAPHS OF THE OCCLUSAL RADIOGRAPHIC RECORDS (A) AND LATERAL RADIOGRAPHIC RECORDS (B). . . . .	43
15. GRAPH PAPER, VERNIER CALIPER, PHONOGRAPH NEEDLE PROBE, AND MAGNIFYING LENS. . . . .	44

Figure	Page
16. DATA ON GRAPH PAPER FROM AN OCCLUSAL RADIOGRAPH (A) AND A LATERAL RADIOGRAPH (B). . . . .	45
17. DISTAL MOVEMENT OF THE MANDIBULAR SECOND PREMOLAR TEETH . . . . .	53
18. ROTATION OF THE MANDIBULAR SECOND PREMOLAR TEETH AROUND LONG AXES. . . . .	55
19. HORIZONTAL MOVEMENT OF THE MANDIBULAR SECOND PREMOLAR DISTAL ROOT APICES . . . . .	56
20. VERTICAL MOVEMENT OF THE MANDIBULAR SECOND PREMOLAR DISTAL ROOT APICES . . . . .	57
21. INTERACTION - ANIMALS x SIDES . . . . .	62
22. INTERACTION - ANIMALS x EXAMINATIONS. . . . .	63
23. INTERACTION - ANIMALS x POINTS. . . . .	64
24. INTERACTION - SIDES x EXAMINATIONS. . . . .	65
25. INTERACTION - EXAMINATIONS x POINTS . . . . .	67
26. INTERACTION - OPERATORS x SIDES . . . . .	70
27. INTERACTION - SIDES x EXAMINATIONS. . . . .	71

LIST OF TABLES

Table	Page
I. COORDINATE MEASUREMENTS FROM THE OCCLUSAL RADIOGRAPHS - MONKEY M-2. . . . .	49
II. COORDINATE MEASUREMENTS FROM THE LATERAL RADIOGRAPHS - MONKEY M-2. . . . .	50
III. ANALYSIS OF VARIANCE - OCCLUSAL RADIOGRAPHS . . . .	60
IV. ANALYSIS OF VARIANCE - LATERAL RADIOGRAPHS. . . .	69



## CHAPTER I

### INTRODUCTION AND STATEMENT OF THE PROBLEM

#### A. Introductory Remarks:

"Of what nature must the forces be, in order to achieve the surest and quickest result in an orthodontic treatment."

Sandstedt (1904)

This question was asked by Sandstedt 60 years ago. He was the first to study the influence of forces on the teeth and their environment. Since then, many clinical estimates have been made of the most desirable forces for tooth movement. Recently, Storey and Smith reopened the question of optimal forces. They concluded that there was an optimal force per unit area of root surface that would yield desirable physiologic tooth movement. Yet, further investigation of the problem is needed which will require a thorough understanding of the biophysics of tooth movement.

Basic tooth movements include tipping, translation, and rotation. The literature abounds with data that the respective force system for each elicits a totally different response in the periodontal ligament. The periodontal ligament itself is a complex biologic organ with its system of

fiber groups and other microscopic elements. Portions of the periodontal ligament may be stressed simultaneously in compression, tension, or shear. The stresses on the fibers in the periodontal ligament blend into one another with no line of demarcation because the root of a tooth is fundamentally a truncated cone. These three stresses are collectively termed "pressure." References are made to the projected root surface area of a tooth. A reliable method of determining the total root surface area of the average tooth is yet to be found. This is a prerequisite to the determination of the optimal force for tooth movement. In view of the foregoing, the following problem will be undertaken.

#### B. Statement of the Problem:

The purpose of this study is to design a method of physically assessing the translatory movement of a mandibular second premolar tooth of a Macaque rhesus monkey in an environment in which the tooth is out of normal occlusion. An appropriate continuous force system will be designed to translate this tooth distally into the first molar extraction site. The reciprocal action of the translatory force on the second premolar tooth will be distributed to the remaining teeth in the arch. They will be tied together as an anchor unit. A bite plane cemented to the maxillary incisor teeth will keep the posterior teeth out of occlusion

and eliminate the influence of occlusion on tooth movement.

The assessment of tooth movement will be made from radiographic data. A stereotaxic instrument will be used to position the head and jaws of the animal in the same spatial relationship for the radiographs. Occlusal radiographs and mandibular lateral periapical radiographs will be taken at the beginning of the experiment, during and upon termination of the experiment. Measurements from the radiographs will be used to obtain numerical data. The animal will be sacrificed and its tissues prepared for a histologic study on completion of the experimental procedure.

## CHAPTER II

### REVIEW OF THE LITERATURE

Sandstedt (1904) studying the biologic aspects of orthodontic tooth movement found that tipping occurred "somewhere in the center of the root." The tooth acted like a "two-armed lever."

Talbot (1903) sought to determine the force magnitude to time ratio at which pathologic changes occurred in the alveolar periodontal environment when teeth were moved orthodontically. Earlier, Farrar (1876) found that physiologic tooth movement was in the range of 1/240 inch every 12 hours. The work of both investigators is significant because of their deliberate effort to regulate tooth movement on a unit time and unit distance relationship.

Oppenheim (1911) ligating the teeth to an expansion arch found that light forces moved teeth most expediently and that the tipping axis was at the apex.

Johnson, Appelton and Rittershofer (1926) using rhesus monkeys studied the effect of labial tipping of the maxillary central incisor teeth with forces not exceeding 2 ounces. They, like Sandstedt, demonstrated a method of applying a force of known magnitude to a tooth and found that the tipped

tooth "...acted like a two-armed lever..."

Herzberg (1932) reported on the histologic changes of bone occurring in man resulting from orthodontic tooth movement. He compared these findings with the tissue changes in laboratory animals under similar conditions of tooth movement. He found that the tissues behaved in the same manner in both.

Schwarz (1932) attempted to correlate the force magnitude used to move teeth with the response of the tissues in dogs. He found that forces no greater than the pressure in the capillaries, 20 to 26 gm./cm.<sup>2</sup>, were most favorable for physiologic tooth movement.

Marshall (1933) using monkeys sought to determine the nutritional factors and force magnitudes causing root resorption. He found that excessive pressures and dietary factors influenced root resorption.

Orban (1936) studying factors influencing "traumatic occlusion" observed that excessive forces crushed the periodontal ligament. He concurred with Schwarz that there is a biologic optimum for tooth movement.

Breitner (1940) attempted to determine the histologic changes taking place in the temporomandibular articulation when the mandible was positioned forward by various orthodontic devices. He found that apposition occurred on the

posterior surface of the condyle and resorption on its anterior surface. Coincident with these changes were those of remodeling in the gonial region.

Sicher and Weinmann (1944) studying tooth movement in the albino rat, found that the normal tooth drift in the albino rat was distally. They ascertained this by superimposing successive radiographic tracings.

Moyers and Bauer (1950) observed that few appliances are capable of producing true bodily movement. They concluded that any translatory force over 25 gm./cm.<sup>2</sup> was excessive and would induce pathologic changes in large areas because the vascular supply to the periodontal ligament was interrupted.

Storey and Smith (1952) sought to determine the optimal force that would produce canine tooth movement without damage. They found that the optimal force was 150 to 200 gm. They also observed the anchor unit would slip mesially if the force was in the range of 300 to 500 gm. They also found that the tipping axis was 1/3 of the root length from the apex. Storey (1953) studying bone changes associated with tooth movement radiographically confirmed the above.

Huettner and Young (1955) studying the effects of orthodontic forces on endodontically treated teeth in rhesus monkeys found there was no difference in tissue response between vital and devitalized teeth. They also found that some

tipping accompanied the bodily movement of these teeth.

Reitan (1957) studied tipping and translation. He found that the force exerted per square millimeter of root surface area was greater in tipping than in translation when equally strong forces were applied to the teeth. He suggested 250 gm. of force for the continuous movement of a canine tooth.

Huettner and Whitman (1958) using various edgewise appliance force systems on the teeth of ten monkeys demonstrated that the light continuous forces produced maximal tooth movements.

Wentz, Jarabak and Orban (1958) studying the influence of "jiggling" or a back and forth movement of a tooth on the periodontal environment observed that alveolar bone and cementum destruction and repair occurred simultaneously.

Reitan (1960) described a method to measure tooth movement accurately. He suggested using a divider to gauge the distance between reference points in amalgam fillings placed into the teeth. He suggested this approach for humans as well as animals.

Jarabak (1960) wrote about the biologic response to orthodontic forces and attempted to define the terms light and heavy forces. He suggests a light force to be one in the range of 28 to 110 gm. and an intermediate force to be from 150 to 180 gm. All values of force beyond this are excessive.

Meyers and Wyatt (1961) using a simple reciprocal coil spring appliance producing 120 gm. of force which caused the teeth to tip studied the histologic changes resulting from the application of continuous forces to the molar teeth of hamsters.

Alexander (1962) studied the influence of a light and a heavy force on the first molar teeth of a rhesus monkey. The object was to translate these teeth. He observed a light force of 83 gm. produced no movement because there was too much friction in the elements of the appliance. The heavy force of 444 gm. caused bodily movement and tipping of the opposite molar.

Burstone (1962) discussed bodily movement as follows; "...as a tooth translates, a relatively uniform stress distribution along the root is found...the center of rotation for translation is at infinity...a single force acting through the center of resistance of a root effects pure translation of a tooth." He considers the center of rotation at infinity in pure translation and at centroid in pure rotation. These are the two basic types of tooth displacement. Other movements are merely combinations of these two basic movements and they all have some intermediate centers of rotation.

Jarabak and Fizzell (1963) writing on the biophysics of tooth movement defined translation as follows; "...when a



tooth is moved without any change in its axis orientation, it is experiencing bodily motion or translation. The basic force system necessary to produce translation in any direction... has been described as the force and couple."

The ultimate answer to the physiologic movement of a tooth is the pressure per square millimeter of effective root surface area of that tooth. They state that "...the most effective pressures at the root surface are likely between 2 and 2.5 gm./cm.<sup>2</sup> of projected area..." Only the forces applied to the crown of the tooth can be measured and determined but the exact root pressures are not known.

Willian (1963) studying the effects of applying continuous lingual root tipping forces to the maxillary central incisor teeth of monkeys found that excessive moments of force caused the greatest root damage while lighter moments of force were less destructive.

Atta (1964) using monkey material tipped the maxillary incisor teeth with light and heavy forces. He concluded that light continuous forces caused a higher rate of tooth movement than heavy forces but heavy forces caused more root resorption.

Jeffry (1965) and Kostiwá (1965) using monkeys designed a method to biophysically assess a reciprocal vertical force system on the posterior teeth in normal functional occlusion and out of occlusion, respectively. They found that their

indirect method of assessing tooth movement was accurate and precise. They concluded that a tooth out of occlusion extruded readily while a tooth in occlusion showed evidence of "jiggling" when extruded.

CHAPTER III  
METHODS AND MATERIALS

A. Animal Selection:

Two Macaque rhesus monkeys were selected for this study. This species of monkey for experimental discipline such as this has been well documented in the literature. It is a hardy laboratory animal with a high tolerance for experimental procedures. Female animals were chosen because they are more docile.

Preliminary experimental design required that the animals have a full complement of permanent teeth except for the third molars. At this stage of dental development, the animals range in age from 3 years 8 months to 5 years 10 months. The second premolar teeth which are next to the last permanent teeth to erupt appear at 3 years 8 months and the third molar teeth at 5 years 10 months. Tooth and bone development of these animals at the mentioned age levels correspond favorably with children ranging from 10 to 12 years. The animals were selected at Shamrock Farms in Middletown, New York, by this investigator. One animal used in this study weighed 10 pounds 6 ounces and its age was estimated at 5 years 6 months. It was labelled M-2 for identification. The other animal

weighed 5 pounds 10 ounces and its age was estimated at 4 years 6 months. It was labelled M-2A.

#### B. Animal Housing and Care:

The animals were housed at the Franklin Boulevard Community Hospital Animal Research Center, Chicago, Illinois. The animal research facility is maintained by the Department of Stomatology.

The animals were kept in separate cages in this colony. Routine daily care was provided by a full-time diener. Indoor conditions were maintained as near optimal as possible for the animals. Their diet consisted of a daily ration of Rockland Laboratory Primate Diet in biscuit form, water, and an orange. The diet was altered for the animals after the mandibular first molar teeth were extracted and during the appliance treatment period. Ripe bananas were substituted for the oranges and the biscuits were moistened with water and transformed into a soft mash. This was done to prevent damage to the orthodontic appliances.

#### C. Animal Handling:

A colonization period of two weeks was observed before any experimental procedures were begun. All handling of the animals was done using an isolation technique. Face masks, surgical scrub suits, and rubber gloves were worn at all

times for the mutual protection of the animals and operator. The "squeeze cage technique" was used to restrain the animals during handling. Heavy leather gloves were also worn to protect the hands.

#### D. General Anesthesia:

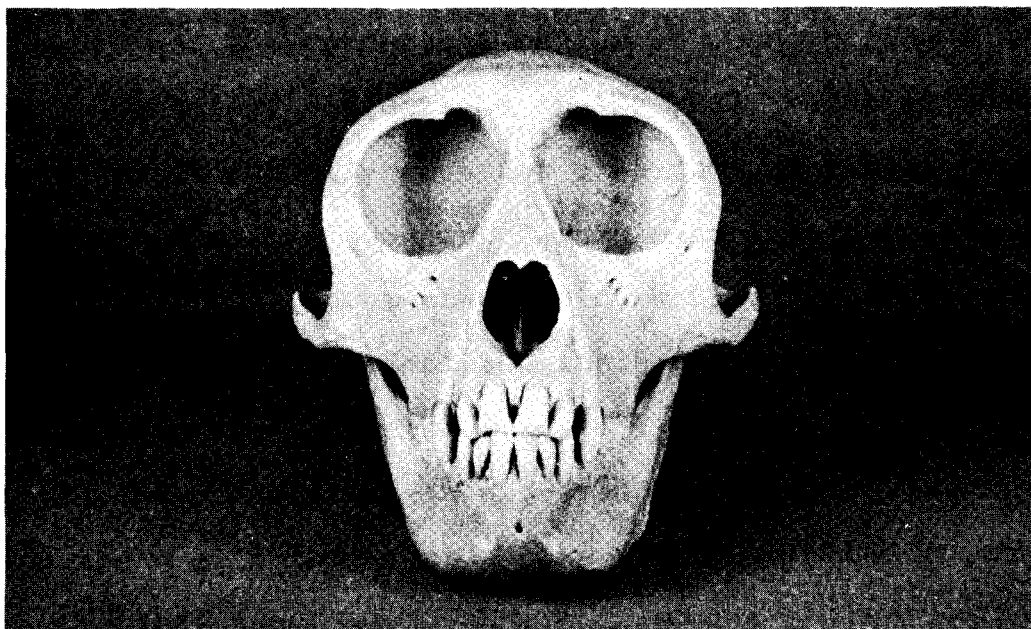All intraoral procedures were performed while the animal was under anesthesia. Prior to the administration of the anesthetic the animal was weighed in the squeeze cage. The weight of the cage was subtracted from the total to ascertain the net weight of the animal. Sodium Nembutal was injected into the saphenous vein at the rate of 50 mg. per 5 pounds of body weight.

The anesthetized animal was immediately taken from the squeeze cage to the operating table. A suture was threaded through the tip of the tongue enabling the operator to pull the tongue forward to maintain an open airway. Butyn Sulfate and Metaphen ophthalmic ointment was placed into each eye to prevent drying and post-operative infection. Precautionary restraints fashioned from 2 inch strips of gauze were used to secure each limb of the animal to the operating table.

#### E. Selection of Teeth for Movement:

The dry skull of a mature rhesus monkey (Figure 1) was used to study the morphology of the crowns of the teeth, their

A



B

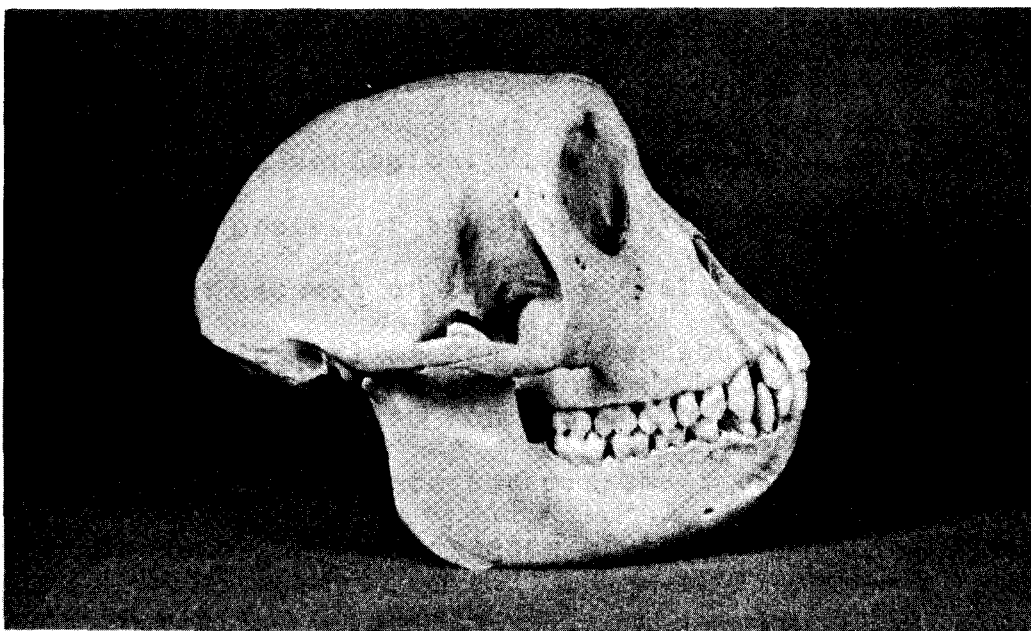


FIGURE 1

FRONTAL VIEW (A) AND LATERAL VIEW (B)  
OF A DRY SKULL OF A RHESUS MONKEY

occlusion, and the morphology of the bone supporting the teeth. Periapical radiographs on the skull revealed root morphology. The bodily movement of a posterior tooth had been selected as the subject of this experiment and tooth movement was to be documented radiographically. The skull was then examined to select the tooth for movement. The findings were as follows;

(1) The premolar teeth are embedded in spongy bone. The canine teeth with long banana-like roots are embedded in more dense cortical bone.

(2) The roots of the mandibular premolar teeth are bifurcated while the roots of the maxillary premolar teeth are trifurcated.

(3) Parallel periapical film placement is possible for the mandibular posterior teeth but it is not possible in the maxillary arch because of the very shallow palatal vault.

(4) Periapical films for the mandibular posterior teeth can be placed only as far forward as the middle of the second premolar tooth. More anterior placement of the film is not possible because of the presence of the lingual surface of the Simeon plate.

(5) The crowns of the second premolar teeth are better shaped morphologically for orthodontic band placement than the crowns of the first premolar teeth.

(6) The teeth mesial and distal to the second premolar tooth could be used as an anchor unit to aid in moving that tooth.

(7) Because of the deep interdigitation of the cusps of the opposing teeth, some means would be needed to eliminate functional interference.

From the foregoing observations on the dry skull, it was concluded that the mandibular second premolar teeth should be translated distally into the extraction sites of the first molar teeth in this study.

#### F. Stereotaxic Instrument for Radiographic Records:


The dry skull of a mature rhesus monkey was used to design an animal cephalometer. The design was based on the principle of the Broadbent cephalostat. The head of the animal was positioned between two movable ear rods while the animal was in the supine position. A millimeter scale having zero at the center of the apparatus enabled the operator to record the position of the ear posts for each animal so that future records could be taken from the same reference. A third point, an incisal guide placed in the mid-sagittal plane, was used to position the head so that the mandibular occlusal plane was either perpendicular to the base of the apparatus or 15 degrees to the base of the apparatus.

Right and left intraoral periapical film holders for




parallel placement of the films were designed to hold films measuring  $7/8$  by  $1\ 3/8$  inches. Orthodontic elastics were used to secure the films to the holders. The centric ray was angulated 10 degrees upward toward the mandibular occlusal plane to compensate for the inferior convergence of the body of the mandible. In addition, it was angulated 6 degrees toward the frontal plane to compensate for the anterior narrowing of the mandible. The centroid of the mandibular second premolar tooth was estimated and the centric ray aimed for this point. A device was constructed to fix the cone of the x ray machine for the lateral periapical radiographs.(Figure 2A).

An occlusal film holder was used with standard dental film measuring  $1\ 3/16$  by  $1\ 5/8$  inches. The film packets were attached to the holder with orthodontic elastics. The head of the animal was tipped back for the occlusal radiographs so that the mandibular occlusal plane was 15 degrees from the original vertical plane. This raised the head and cone of the x ray machine from the chest of the animal. The centric ray was directed perpendicular to the film packet and centered on a point which represented the intersection of the cranial midline and a line between the two mandibular second premolar teeth. A device was constructed to fix the cone of the x ray machine for the occlusal radiographs (Figure 2B).



A



B

(3) Models were made of the dentures of each animal. A  
FIGURE 2  
ANIMAL HEADHOLDER AND X RAY ORIENTING DEVICE FOR  
LATERAL RADIOGRAPHS (A) AND OCCLUSAL RADIOGRAPHS (B)

### G. Preparation of the Experimental Animal:

After a general anesthetic was administered as described earlier, the following things were done to prepare the animal for the experimental procedure;

(1) A prophylaxis was performed on the teeth of each animal. They had small amounts of calculus on the anterior teeth. The teeth were scaled and then polished to remove any remaining stains.

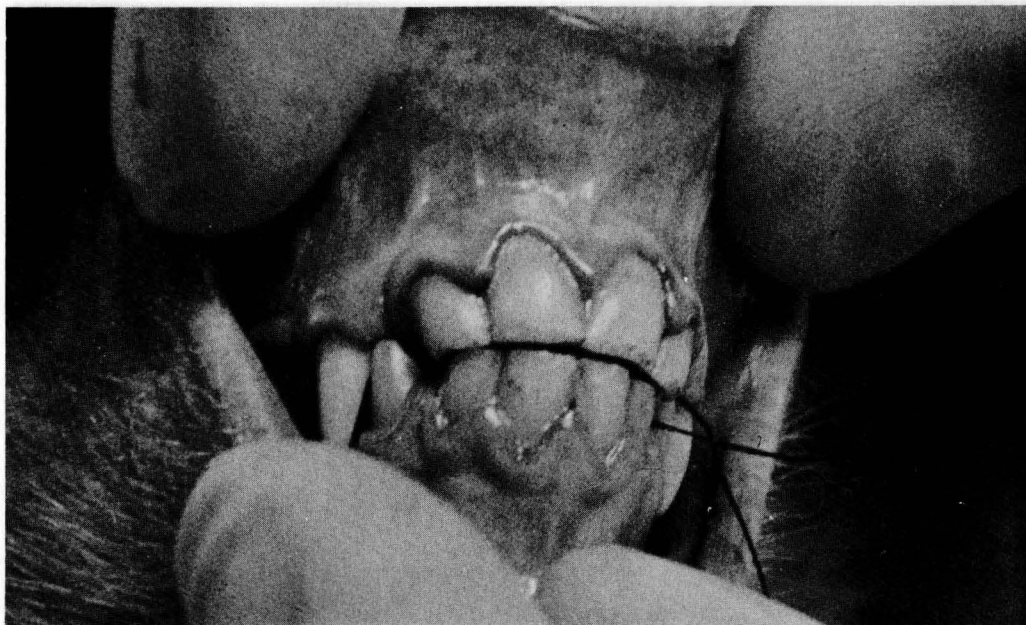
(2) Intraoral photographs were taken of the teeth of each animal (Figure 3).

(3) Models were made of the dentures of each animal. A heavy rubber base impression material in acrylic trays was used to take accurate impressions. Models were prepared from these impressions on which the appliances were constructed.

(4) Simple occlusal cavities were prepared in the mandibular posterior teeth into which were placed amalgam fillings. These fillings were used as reference points (Figure 4). Two cavities were prepared in each second premolar tooth and one in each first premolar and molar teeth.

(5) Each animal was placed into the stereotaxic instrument (Figure 5). A notation was made of the ear post position from the scale for subsequent radiographic records. Bilateral periapical radiographs and occlusal radiographs were taken at a target film distance of 16 inches. An exposure time of  $1\frac{1}{2}$

A



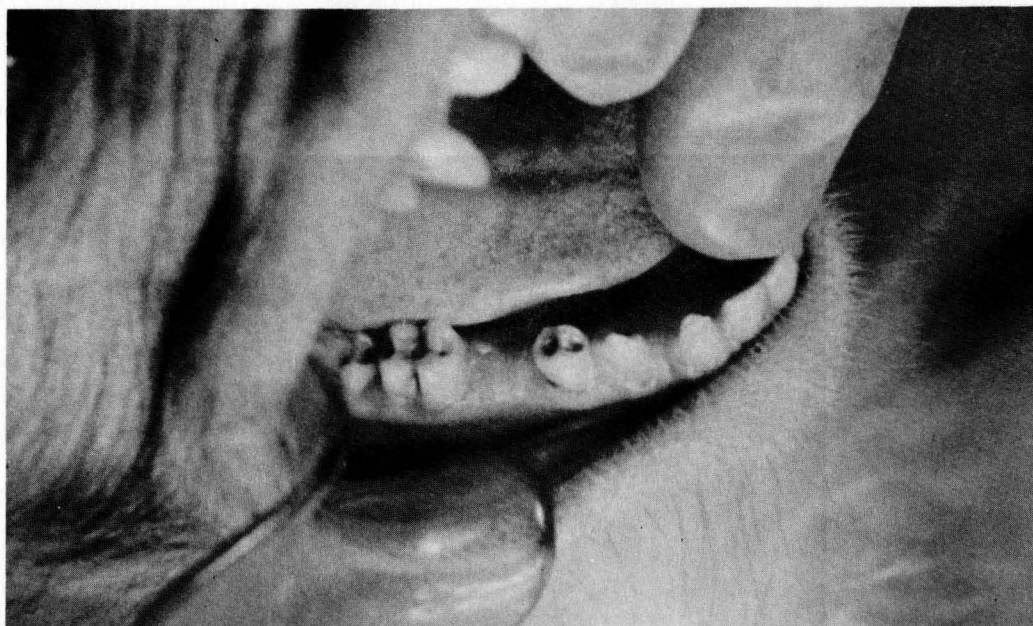
B

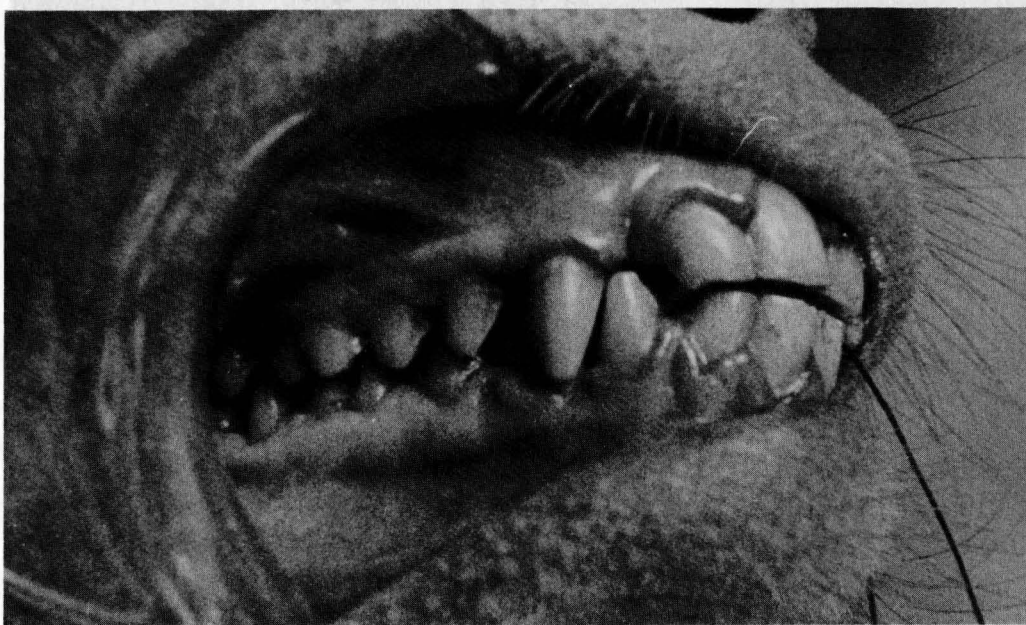

FIGURE 3

INTRAORAL PHOTOGRAPHS OF THE  
FRONTAL VIEW (A) AND LATERAL VIEW (B)

A



B

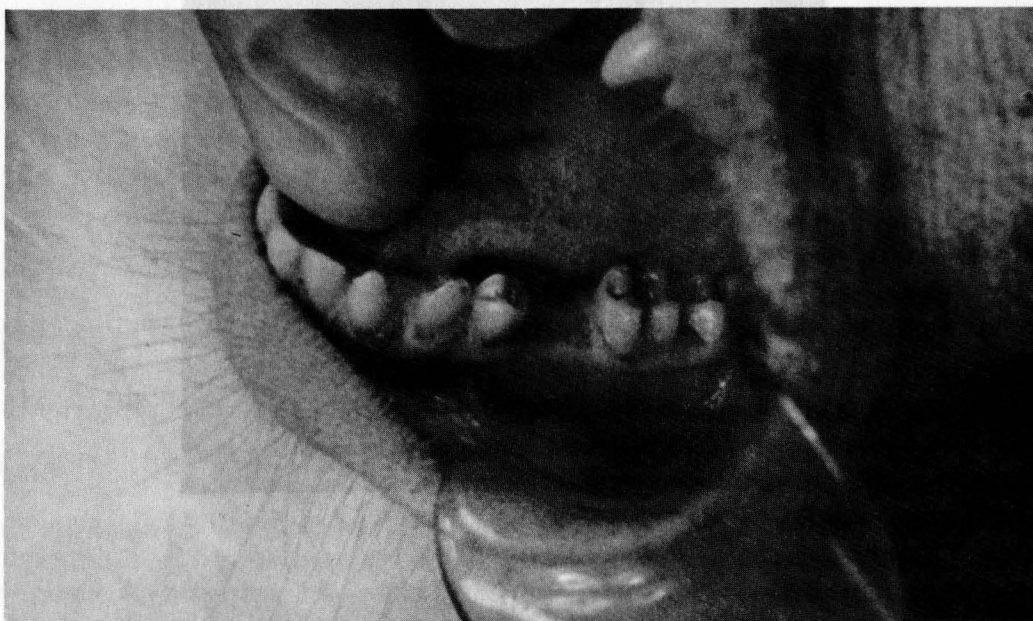
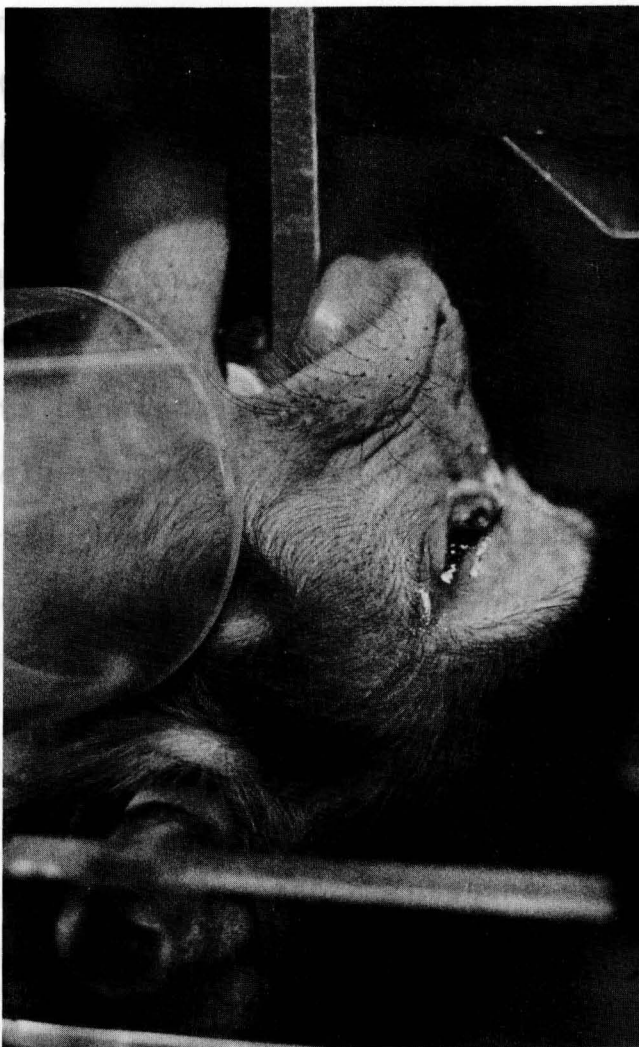


FIGURE 4

ANESTHETIZED ANIMAL POSITIONED IN STEREOTAXIC INSTRUMENT  
RIGHT SIDE (A) AND LEFT SIDE (B)

seconds at 125 KVP and 25 MA was used with Kodak Ultra-speed film to obtain each radiograph.

(6) The  
 the closed me  
 employs eleva  
 alveolar bone  
 was made of t  
 remained and  
 returned to i  
 facing obliqu  
 from accumula  
 tion was unif  
 the tongue su  
 H. Force Syst  
 The main  
 second mandib  
 the mandibula  
 This force ce



extracted by  
 , this method  
 destruction of  
 an inspection  
 t no debris  
 a monkey was  
 the head  
 secretions  
 When respira-  
 l would revive,  
 closed.  
 termination  
 translate the  
 action site of  
 an magnitude.  
 (an intrinsic

force system). It can be derived from an extraoral device such as a headgear (an extraoral extrinsic force system). It can be developed by stretching intraoral rubber bands (an intraoral extrinsic force system). **FIGURE 5** The intrinsic force system was used to apply a distally directed translatory force to move the mandibular

seconds at 125 KVP and 25 MA was used with Kodak Ultra-speed film to obtain each radiograph.

(6) The mandibular first molar teeth were extracted by the closed method. For purposes of explanation, this method employs elevators and forceps to minimize the destruction of alveolar bone. After the teeth were removed, an inspection was made of the oral cavity to make certain that no debris remained and that all bleeding had stopped. The monkey was returned to its cage and laid on its side with the head facing obliquely downward. This prevented oral secretions from accumulating and obstructing the airway. When respiration was uniform and it appeared that the animal would revive, the tongue suture was removed and the cage was closed.

#### H. Force System Design and Force Magnitude Determination:

The main object of this experiment was to translate the second mandibular premolar tooth into the extraction site of the mandibular first molar with a force of known magnitude. This force can be derived from stressing a wire (an intrinsic force system). It can be derived from an extraoral device such as a headgear (an extraoral extrinsic force system). It can be developed by stretching intraoral rubber bands (an intraoral extrinsic force system). The intrinsic force system was selected. This force system was designed to produce a distally directed translatory force to move the mandibular

second premolar tooth.

The magnitude of force that will cause optimal translatory movement of a rhesus monkey mandibular second premolar tooth is unknown. Jeffry (1965) and Kostiwa (1965) determined that 60 percent of the force value for the movement of a human tooth be used for a monkey tooth. Empirical values of approximately 180 to 200 gm. have been suggested for the movement of a human premolar tooth. A force of 100 to 125 gm. was selected to translate the mandibular second premolar tooth in this experiment.

#### I. Appliance Design:

The force system specified in the preceding section required that an intrinsic force system achieve the desired translatory movement of a mandibular second premolar tooth. This implied that the translatory force had to come from the archwire itself. A force and a couple are necessary to effect a translatory tooth movement. This will be done with a specific arrangement of helical loops.

The combined action of two helical loop springs was decided upon in the design of the active element. An expansion loop was placed mesial to the second premolar tooth and a contraction loop was placed distally. The respective opening and closing of these loops resulting in a push and a pull provided a distally directed force. A couple was



developed by the horizontal segment of the archwire between the two loops. This segment was engaged in the horizontal slot of a specially designed edgewise bracket on the second premolar. The stressed segment of wire made a two point contact with the bracket while the vertical slots in the end slotted brackets afforded additional control by engaging the legs of the mesial expansion loops. The action of the active element was reciprocal on the first premolar and second molar teeth, tending to move them mesially. To minimize the reciprocal action on these two teeth, they were attached to a lingual archwire which was also affixed to the canine tooth as well as the teeth on the opposite side of the arch.

#### J. Appliance Construction:

The appliances were constructed on models prepared from the rubber base impressions poured in dental stone (Figure 6). The mandibular teeth on the stone models on which the bands were to be placed were trimmed along the gingival margin to facilitate band adaptation. The first molar crowns were removed completely from the models because these teeth were extracted after the impressions were taken. Bands for the canine teeth were fabricated from 0.003 inch banding material, the premolar bands from 0.004 inch banding material, and the molar bands from 0.006 inch banding material. A 0.036 inch passive mandibular lingual arch was formed for

each appliance and made to contact all of the teeth end bands except the second premolar bands. The arch was then soldered to all of the bands except the second premolar bands. The brackets were first aligned and then soldered to the first premolar, second premolar, and second molar bands on one side.

Band

caus

(pas

appl

form

cons

mon

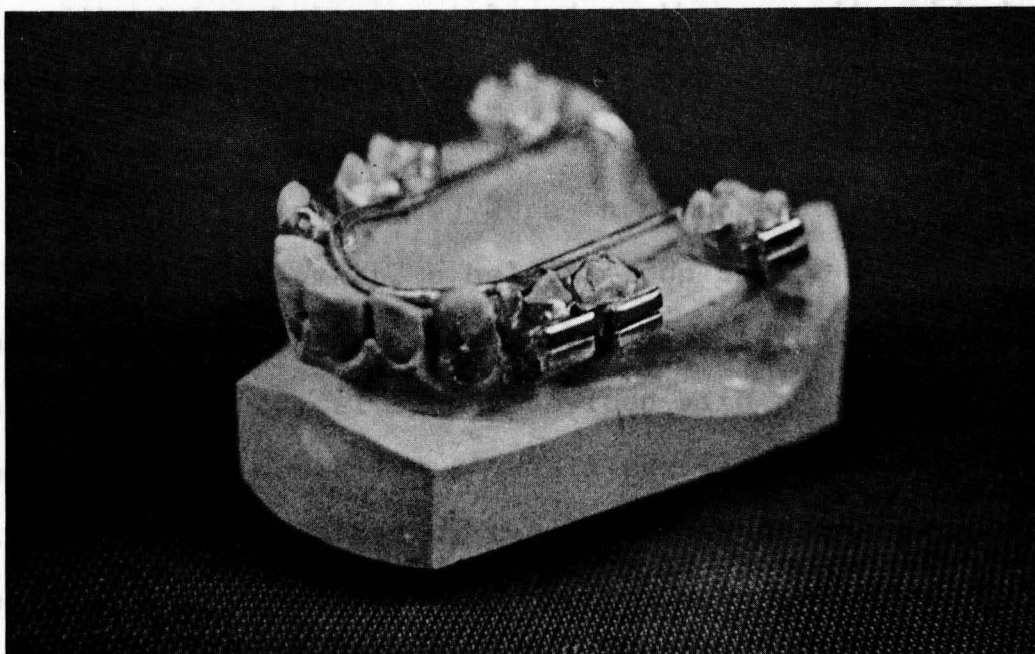
at t

mon

loop.

This arch was placed over the first and second premolar teeth engaging the vertical slots of the end-slotted brackets on these teeth. A contraction loop was fitted distal to the second premolar tooth. A vertical hook was placed to the distal of the second molar tooth to rest in the distal vertical slot of the second molar bracket. This hook activated the contraction loop. All of the loops in each active element were made with  $2\frac{1}{2}$  turns of FIGURE 6

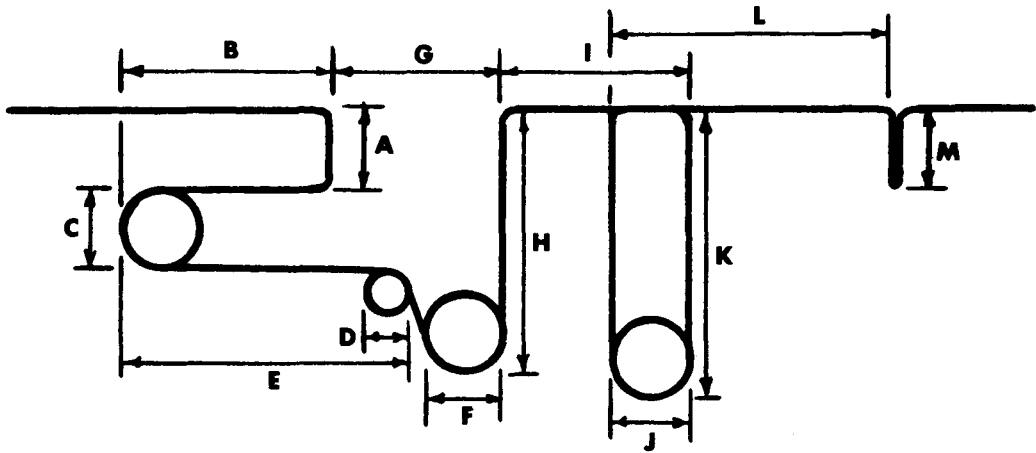
PASSIVE COMPONENT OF THE APPLIANCE ON WORKING MODEL



each appliance and made to contact all of the teeth and bands except the second premolar bands. The arch was then soldered to all of the bands except the second premolar bands. The brackets were first aligned and then soldered to the first premolar, second premolar, and second molar bands on one side. Bands without brackets were placed on the opposite side because these teeth were the control. After the bands and arch (passive elements) were fabricated for each animal, the loop appliances (active elements) were then constructed.

Each active element, a helical loop spring unit, was formed from 0.014 inch green Elgiloy wire (Figure 7). It consisted of a vertical expansion loop with a horizontal moment extending mesially. A small auxillary loop was placed at the right angle formed by the lower leg of the horizontal moment and the continuation of the mesial leg of the vertical loop. This unit was placed between the first and second premolar teeth engaging the vertical slots of the end-slotted brackets on these teeth. A contraction loop was fitted distal to the second premolar tooth. A vertical hook was placed to the distal of the second molar tooth to rest in the distal vertical slot of the second molar bracket. This hook activated the contraction loop. All of the loops in each active element were made with  $2\frac{1}{2}$  turns of wire.

The requirements of the active elements were that they



	M-2	M-2A
A	2.9	2.6
B	6.9	6.9
C	2.8	2.8
D	1.9	1.8
E	9.0	8.8
F	2.8	2.7
G	5.2	5.3
H	8.9	7.8
I	6.3	6.9
J	2.9	2.9
K	9.1	9.4
L	9.2	9.0
M	4.0	4.0

FIGURE 7

DIAGRAM OF THE ACTIVE ELEMENT WITH DIMENSIONS IN MILLIMETERS

each produce a force of 100 to 125 gm. and that each have a linear characteristic for a minimum of 2 mm. of return. Each element was tested on the load-deflection apparatus (Figure 8). Wires of several diameters and types were tested for force magnitudes and elasticity by being made up into variations of the basic design. These elements were made with  $1\frac{1}{2}$  and  $2\frac{1}{2}$  turns, with and without auxillary loops. They were tested for force magnitudes before and after heat treatment. The characteristics for the two active elements used in this study are illustrated in Figure 9.

In addition to the loop appliance, a bite plane was cemented to the maxillary anterior teeth. It was constructed from acrylic resin. The bite plane covered the anterior teeth and extended to a point just distal to the canines. The inclined plane extended in a straight line across the palate from the right to the left maxillary canines. The edge of the resin extended 1 to 2 mm. above the gingival margins of the teeth on the labial. The plane opened the bite approximately 2.5 mm. in the incisor region. The tips of the maxillary canine teeth protruded through the bite plane. In the construction of the plane the canine teeth were reduced on the stone model. Subsequently, the teeth themselves were ground down prior to cementing the appliance. The cusps of the mandibular canines were also reduced to the height of the





FIGURE 8  
LOAD-DEFLECTION TESTING APPARATUS

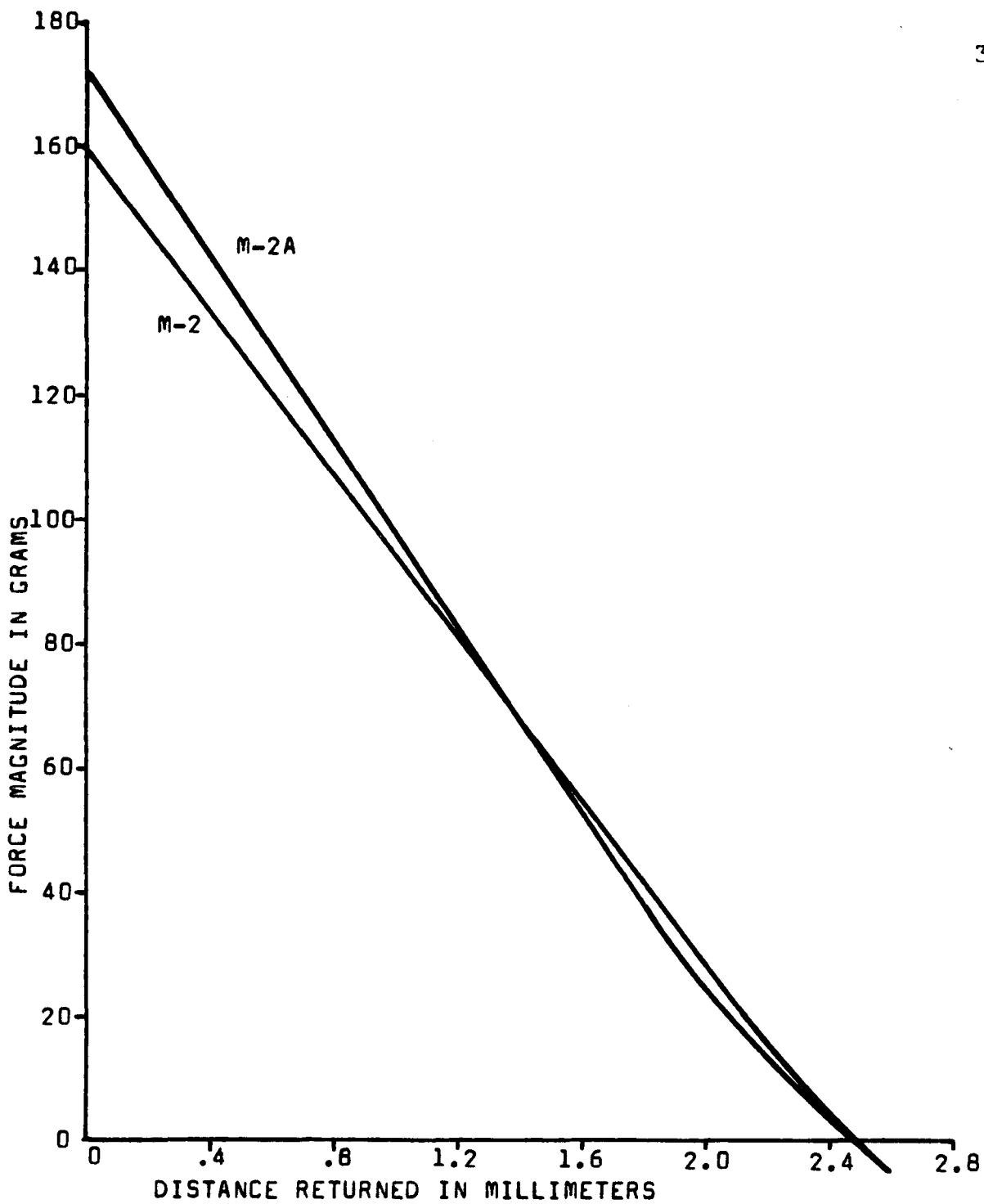


FIGURE 9  
LOAD-DEFLECTION CHARACTERISTIC

four mandibular incisor teeth so that all the teeth would strike evenly on the acrylic bite plane

#### K. Appliance Cementation and Activation:

The animal was given a general anesthetic. The contact points between the teeth were reduced with lightning strips to facilitate placement of the mandibular appliance. The appliance was cemented to the teeth. The resin bite plane was cemented to the maxillary anterior teeth. The helical loop spring element was tied to the brackets with 0.010 inch ligature wire (Figure 10). The animal was then placed into the stereotaxic instrument for radiographic records.

Next, the forelimbs of the animal were shaved to the elbows and the skin was painted with tincture of benzoin. The hands and wrists were loosely wrapped with several layers of gauze which was followed by adhesive tape to form mitten-like gloves (Figure 11). The benzoin was used to reduce irritation of the skin by the adhesive. The mittens restrained the animal from tearing off the orthodontic appliances.

#### L. Animal Sacrifice and Perfusion:

When the active element of the orthodontic appliance was fully deactivated, the animal was given a general anesthetic. Final radiographic records were made. The animal was then moved to the operating table. The necessary equipment for the



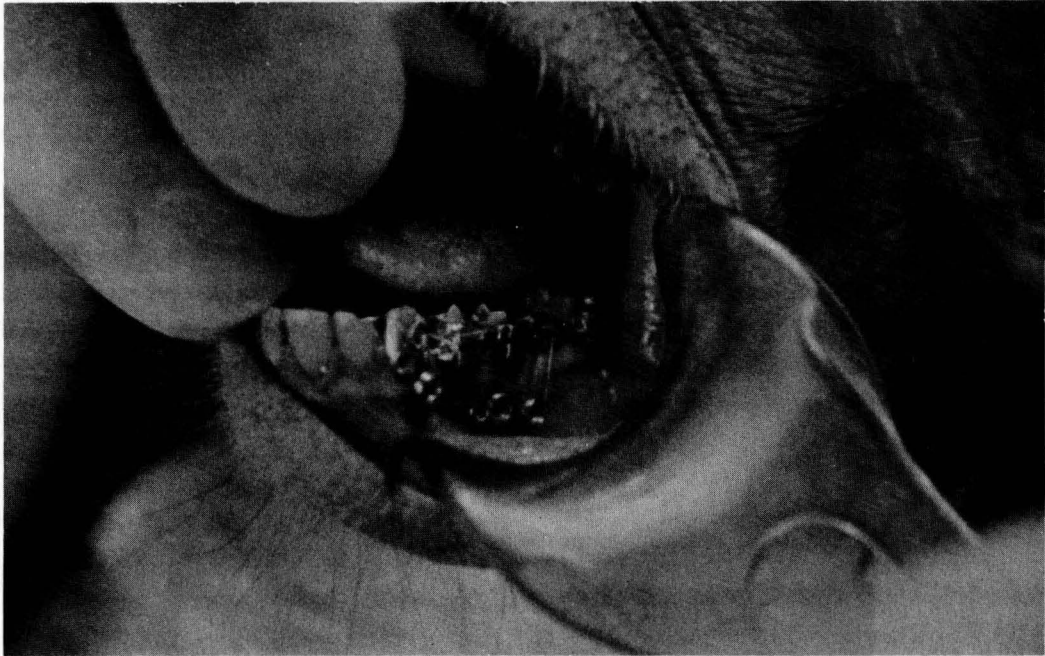



FIGURE 10

ANIMAL DEACTIVATED APPLIANCE



sacrifice and perfusion was prepared beforehand. A thoracic incision was made over the sternum and the skin reflected.

The first to

the sternum.

Entry was made

cardium was

exposed. The

and the arch

of the sort

tion of the

aorta was cl

was punc-

tured and th

perfusion

cannula was

ution of

isotonic sod

circulatory

system by ne

out from

the tissues

lear sodium

citrate solu

cava, a 10

percent buff

roduced to

replace the

of the tissues

was complete

from the

superior ven

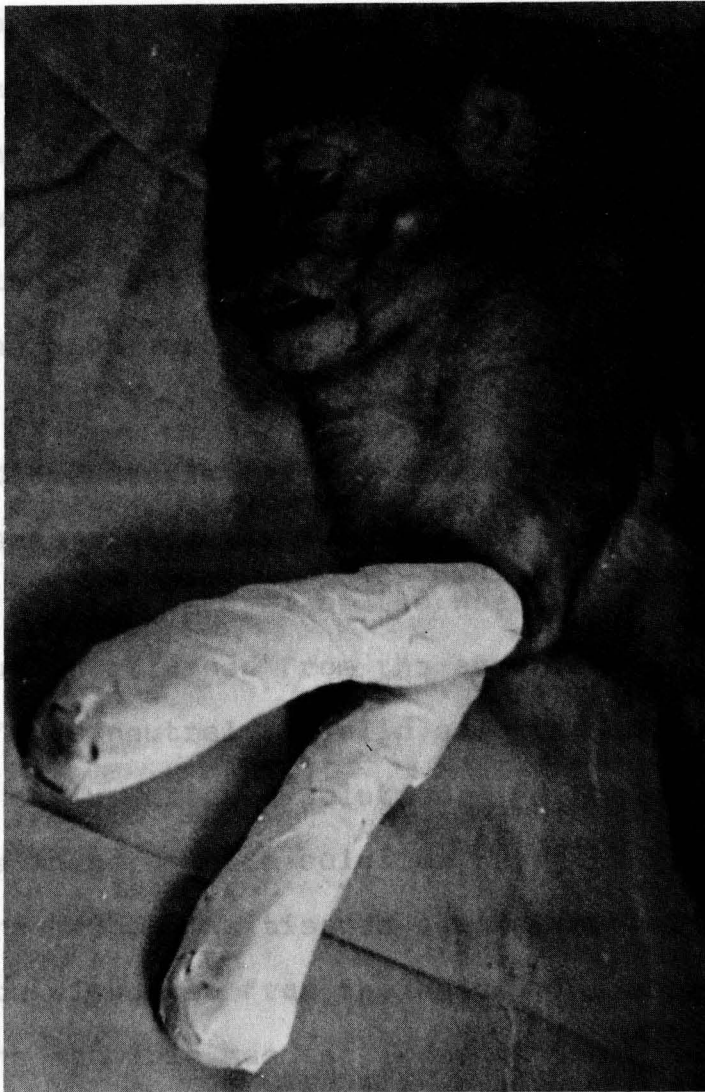
d. The man-

dible was no

ance was re-

moved and th

ns. The



sections were then placed into a 10 percent buffered solution of formalin.

#### M. Analysis of the Force System:

#### FIGURE 11

The force system used in this experiment can be analyzed with the aid of a free body diagram. This will

#### ANIMAL WITH THE MITTEN-LIKE RESTRAINTS

sacrifice and perfusion was prepared beforehand. A thoracic incision was made over the sternum and the skin reflected. The first to the fifth ribs were removed with the sternum. Entry was made into the mediastinum and the pericardium was exposed. The superior and inferior vena cava and the arch of the aorta were identified. The descending portion of the aorta was clamped off and the superior vena cava was punctured and the blood aspirated. Simultaneously, a perfusion cannula was inserted into the aortic arch. A solution of isotonic sodium citrate was introduced into the circulatory system by means of gravity feed forcing the blood out from the tissues above the level of the heart. When clear sodium citrate solution returned from the superior vena cava, a 10 percent buffered neutral formalin solution was introduced to replace the sodium citrate solution. Perfusion of the tissues was complete when formalin solution began to flow from the superior vena cava. The tissues became very rigid. The mandible was now dissected from the head. The appliance was removed and the mandible was sectioned at the midline. The sections were then placed into a 10 percent buffered solution of formalin.

#### M. Analysis of the Force System:

The force system used in this experiment can best be analyzed with the aid of a free body diagram. This will

illustrate the effect of the force system on the mandibular second premolar tooth. Diagrammatic sketches of the buccal and occlusal views of this tooth are shown in Figure 12.

A distally directed force  $F_m$  from the helical loop unit was applied to the bracket of the tooth. The vector labelled  $F_m$  represents this force. Simultaneously, the stressed horizontal segment of the helical loop unit making two point contact in the horizontal slot of the bracket, developed a couple labelled  $F_t-F_t$  having counter-clockwise torque. In analytical mechanics, the combination of a force and a couple acting simultaneously produce translatory movement of an object (in this case a tooth). The resultant of this system on the tooth was a force represented by the vector  $f$ . It was assumed that the force  $f$  directed at the centroid of the tooth would bring about pure translation. The reacting force to this force  $f$  was developed in the periodontal ligament and alveolar process around this tooth. This resistance was represented by the force labelled  $F_R$ . In reality, force  $F_R$  was distributed along the entire root surface but theoretically, it was effective only at the centroid of the tooth. This force was equal, opposite, and collinear to force  $f$ . The foregoing explanation of force  $f$  and force  $F_R$  is based on the second law of equilibrium which states that the sum of all the forces in a horizontal direction is zero when a body is in equilibrium,  $\sum F_H = 0$ .

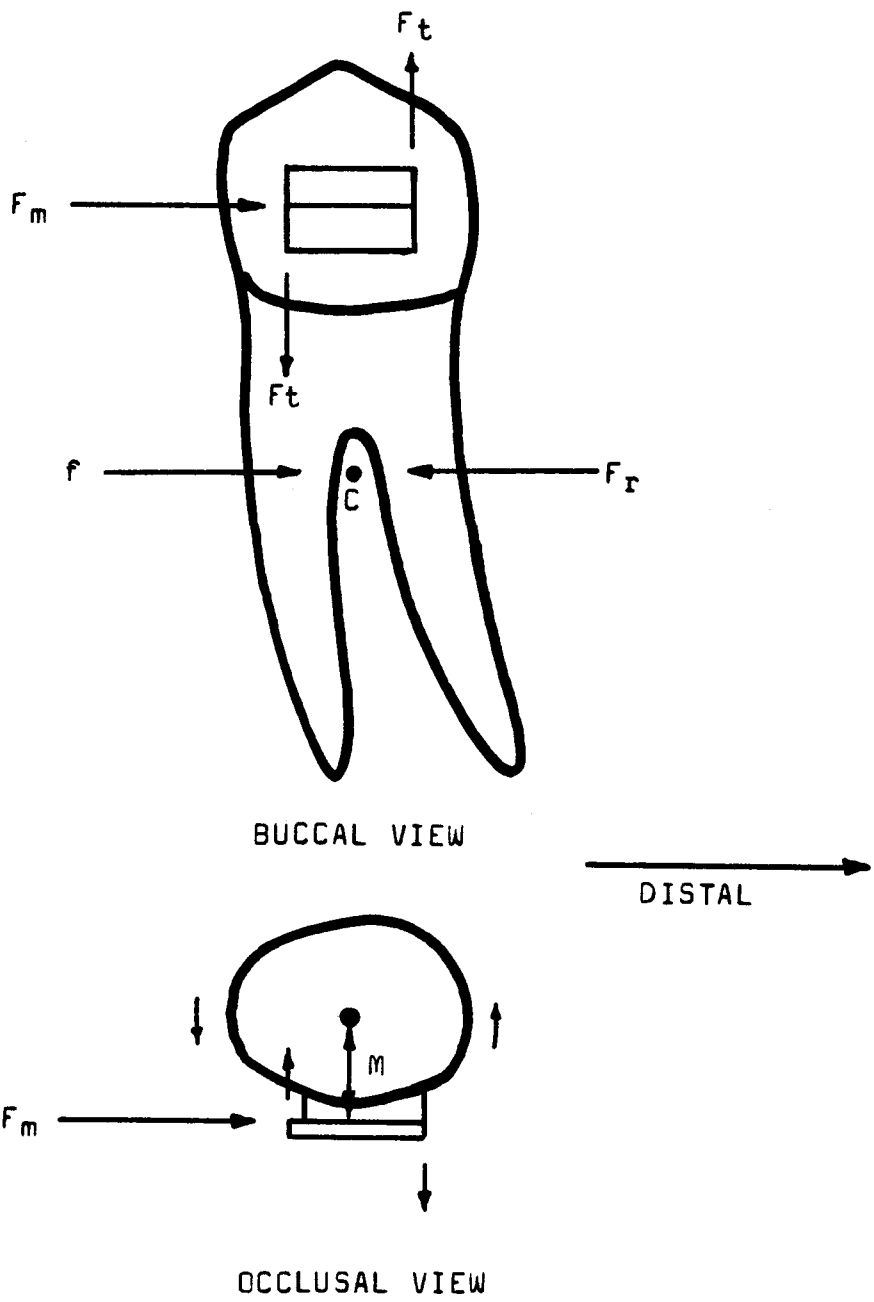


FIGURE 12  
FREE BODY DIAGRAMS

There had to be a delicate balance between the magnitudes of the force  $F_m$  and the couple  $F_t-F_t$  for pure translation to take place. The resultant force  $f$  had to be directed at the centroid of the tooth. If the magnitude of the force  $F_m$  was excessive and the moment of the couple deficient, the tooth would tip in a clockwise direction. Conversely, if the force  $F_m$  was of a lesser magnitude and the couple  $F_t-F_t$  excessive, the tooth would tip counter-clockwise. In either case, there would be tipping.

The free body diagram from the occlusal aspect illustrates that force  $F_m$  was not in line with the long axis of the tooth. Rather, it was applied to the bracket located on the buccal surface of the tooth creating a moment of force. The moment arm  $M$  extended from the long axis of the tooth to the point of application of the force on the bracket. This turning moment of force attempted to rotate the tooth in a counter-clockwise direction but a resisting couple arising from the supporting tissues of the tooth prevented this. The moment of force would bring about a rotation of the tooth as the tissues responded but this rotation was limited by the effect of a couple arising from the action of the archwire tied in the bracket. Thus, the resultant of force  $F_m$  viewed from the occlusal was translation of the tooth with a limited degree of rotation in a counter-clockwise direction.

The third equation of equilibrium states that the sum of all the moments about any point is zero,  $\sum M_p = 0$ . The following calculations will yield the initial magnitude of the couple  $F_t - F_t$  which should be developed by the respective force system for each animal. A diagrammatic sketch of the mandibular second premolar tooth with the necessary measurements for the calculations is shown in Figure 13. From the previous determinations, centroid was found to be located at a point 63 percent of the root length from the apex. Hence, the dimension from the apex to centroid =  $0.63 \times 8.60 = 5.52$  mm.

$$\sum M_p = 0$$

$$0 = F_m(4.48) - F_t(1.25) - F_t(1.25) + F_r(0)$$

For monkey M-2,  $F_m = 118$  gm.

$$0 = 118(4.48) - F_t(2.50)$$

$$F_t = \frac{118(4.48)}{2.50}$$

$$F_t = 211.5 \text{ gm.}$$

For monkey M-2A,  $F_m = 123$  gm.

$$0 = 123(4.48) - F_t(2.50)$$

$$F_t = \frac{123(4.48)}{2.50}$$

$$F_t = 220.0 \text{ gm.}$$

It was noted earlier in the text that a force  $F_t$  of greater magnitude than that calculated above would cause a counter-clockwise tipping movement. A lesser magnitude of  $F_t$  would

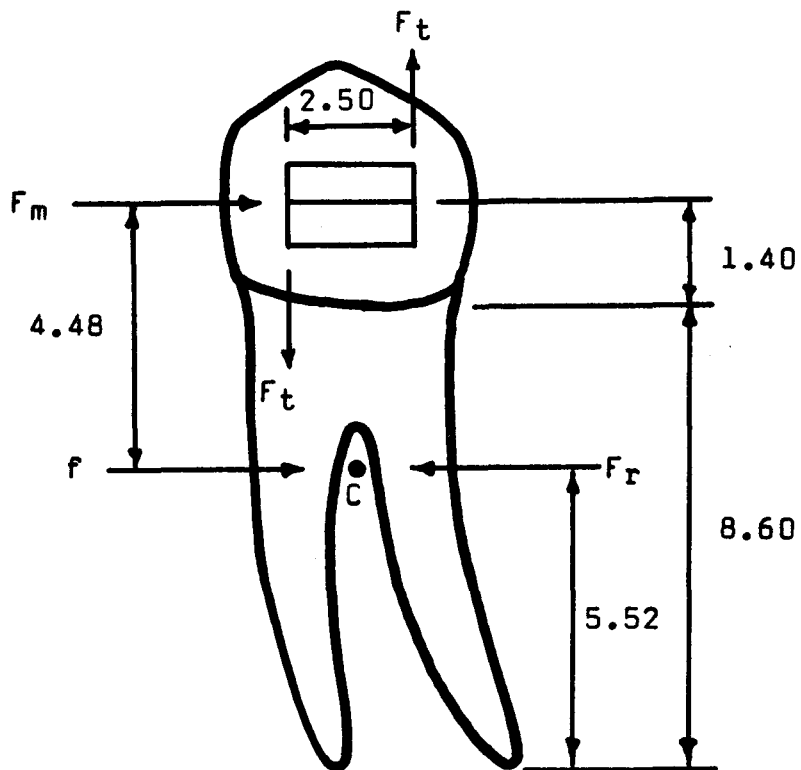


FIGURE 13

DIAGRAM WITH DIMENSIONS FOR THE DETERMINATION  
OF THE MAGNITUDE OF THE COUPLE  $F_t - F_t$



result in a clockwise tipping of the tooth. The values calculated are valid immediately after the initial activation of the force system. As the system deactivates, the magnitudes of the force  $F_m$  and the couple  $F_t-F_t$  diminish.

#### N. Method of Assessing Tooth Movement:

(1) Testing the reliability of measurements from radiographic records.

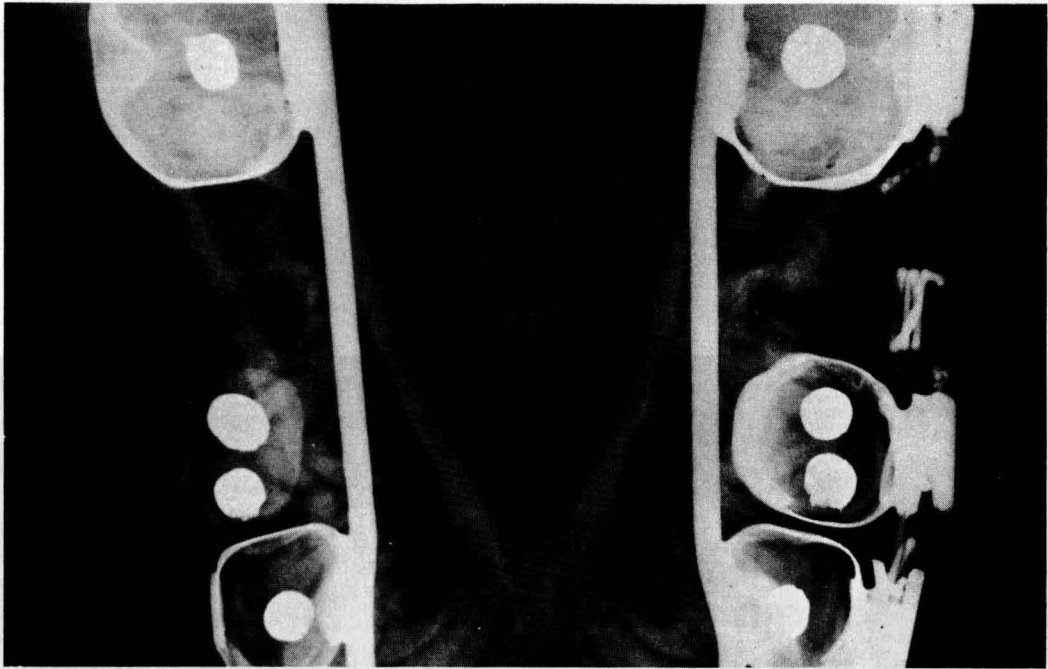
Occlusal amalgam restorations were placed into the mandibular first and second premolar and second molar teeth of a rhesus monkey dry skull. Two fillings were placed into each second premolar tooth and one filling each into the first premolar and second molar teeth. The skull was then placed in the animal headholder and an occlusal radiograph taken. Examining the radiograph on a view box under a  $3\frac{1}{2}$  inch magnifying lens, the center of each amalgam restoration image was punctured with a phonograph needle probe to make a point. The distances between the points were then measured. Twenty-eight combinations of measurements were made on the radiograph. Identical measurements were made directly between the amalgam restorations in the teeth of the dry skull. All measurements were made with a precision vernier caliper. The two sets of measurements were compared by the t-test. Statistically, there was little difference in the direct measurements as compared with those made on the x ray film.

(2) Method of obtaining measurements from the mandibular occlusal radiographs.

The serial mandibular occlusal radiographs (Figure 14A) taken during the experiment were considered individually in their proper sequence. Each film was first placed on a view box. The images representing the amalgam restorations were identified with the help of a  $3\frac{1}{2}$  inch magnifying lens and the point of a phonograph needle probe was used to perforate the center of each image (Figure 15). The perforations were assigned letters A through H starting with the left second molar and working around the arch to the opposite second molar. A sheet of thin vellum graph paper graduated in millimeters on which "x" and "y" axes were marked off was placed beneath the film. Point H was superimposed on the origin of the coordinate system. Point A was superimposed on the "y" axis so that the remaining points were located in the first quadrant. The phonograph needle probe was used to perforate the vellum graph paper and thus transfer the points from the film to the graph (Figure 16A). The points were labelled with the appropriate letters. A separate sheet of graph paper was used for each occlusal film and identified with the animal and examination numbers.

All measurements were taken by two operators. A precision vernier caliper was used to make the measurements

A



B

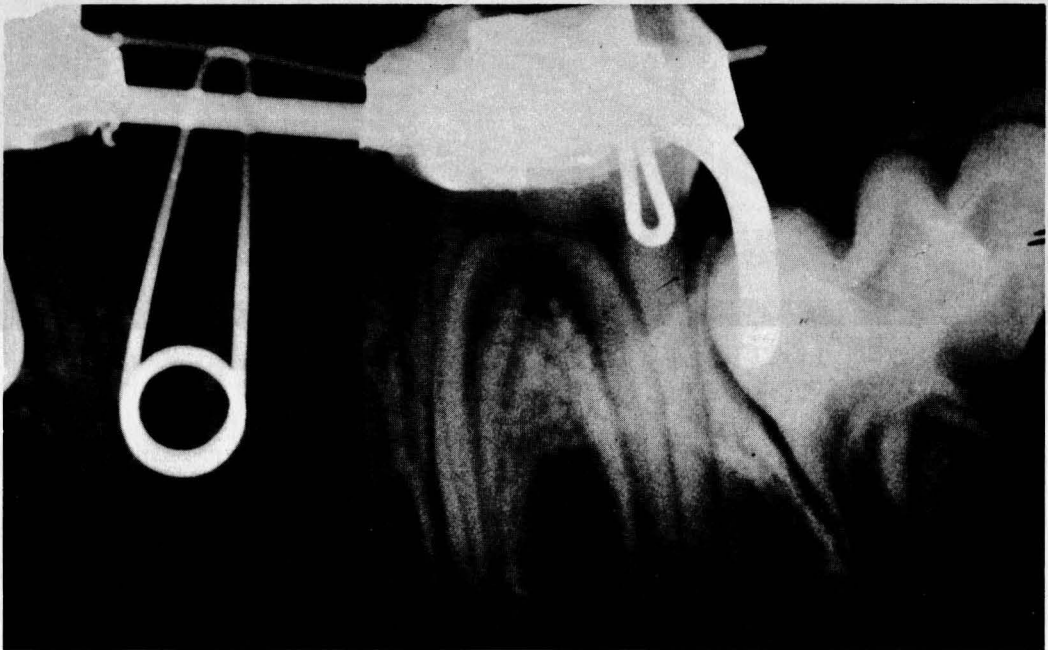


FIGURE 14

PHOTOGRAPHS OF THE OCCLUSAL RADIOGRAPHIC RECORDS (A)  
AND LATERAL RADIOGRAPHIC RECORDS (B)




FIGURE 15

GRAPH PAPER, VERNIER CALIPER, PHONOGRAPH NEEDLE PROBE,  
AND MAGNIFYING LENS

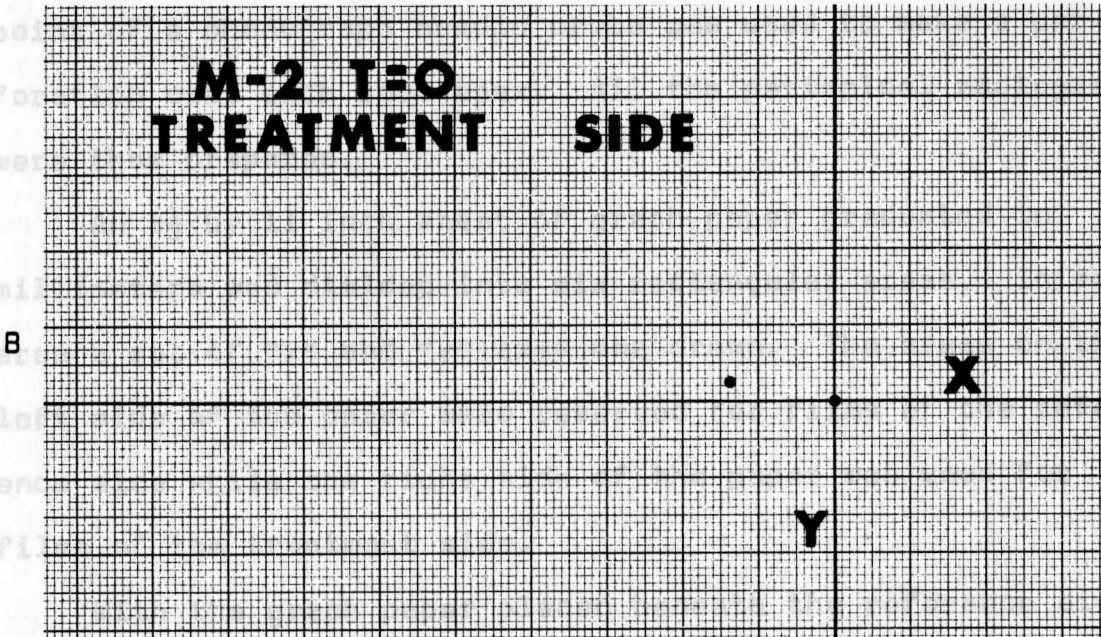
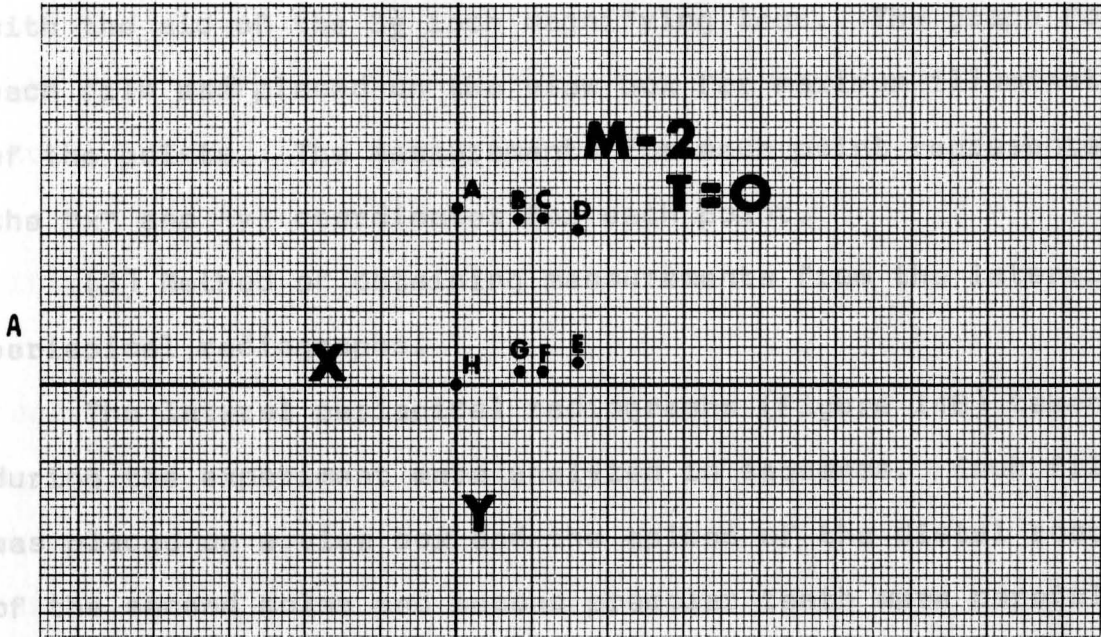


FIGURE 16

DATA ON GRAPH PAPER FROM AN OCCLUSAL RADIOGRAPH (A)  
AND A LATERAL RADIOGRAPH (B)

with the aid of the  $3\frac{1}{2}$  inch magnifying lens. The graph for each film was placed on the view box for maximum illumination of the points. The measurements for each point represented the "x" and "y" coordinates for each point.

(3) Method of obtaining measurements from the lateral periapical radiographs.

The lateral periapical radiographs (Figure 14B) taken during the experiment were analyzed in sequence. Each film was placed on a view box and the apices of the distal roots of the second molar and second premolar teeth were carefully identified with the help of the  $3\frac{1}{2}$  inch magnifying lens. The point of a phonograph needle probe was used to make a perforation over each root apex. All the periapical radiographs were thus prepared.

An  $8\frac{1}{2}$  by 11 inch sheet of graph paper graduated in millimeters was divided into six rectangular areas. In each area a set of "x" and "y" axes was drawn. The areas on the left side of the paper were reserved for films of the reference side while the right side of the paper was used for films of the treatment side.

With the graph paper placed beneath the reference side periapical radiograph, the distal root apex of the second molar which was perforated was superimposed on the origin of the coordinate system. The image of the lingual archwire was

positioned parallel to the "x" axis. This placed the premolar root apex perforation into the first quadrant. Both points were transferred to the graph paper with the phonograph needle probe and that section of the graph paper appropriately identified.

A lateral periapical radiograph of the treatment side corresponding to the periapical film of the reference side was placed on the coordinate system in the section adjacent to that used for the reference side. The points were transferred to the graph paper as described above. The premolar root apex point on the treatment side was located to the left of the "y" axis or in the second quadrant (Figure 16B).

The data were thus transferred from the lateral periapical radiographs to the graph paper. Each graph was then placed on the view box. With the aid of the magnifying lens, a precision vernier caliper was used to measure the "x" and "y" coordinates for each point. Two operators made independent measurements and their findings were recorded.

## CHAPTER IV

### FINDINGS

#### A. Reducing the Data:

On completion of the laboratory phase of the experiment, the process of data reduction was begun. This consisted of taking measurements of tooth positions from the radiographs as described in Chapter III, Methods and Materials. Tables I and II are sample data sheets. One sheet was drawn up for each animal. The sheets contained the "x" and "y" coordinates for each point as measured on each examination day by the two operators.

The data from each examination represented the location of the teeth of the animal on the examination days. The change from day to day was shown by the difference between successive locations. When the successive locations were plotted on graphs having time as the "x" axis, the line connecting these locations revealed the trend of tooth motion. Graphs were prepared to show these important findings.

#### B. Testing the Stability of the Anchor Unit Points:

Points A, D, E, and H as described in Chapter III, Methods and Materials, were the "corner points" of the anchor unit or reference framework. Point H was always located at the



TABLE I  
 COORDINATE MEASUREMENTS FROM THE OCCLUSAL RADIOGRAPHS  
 MONKEY M-2

EXAMINATION	POINT	OPERATOR #1		OPERATOR #2	
		x	y	x	y
T=0	A	0.00	22.70	0.00	22.85
	B	8.40	21.20	8.40	21.25
	C	10.85	21.30	10.85	21.40
	D	15.25	20.25	15.20	20.25
	E	13.85	2.80	13.85	2.80
	F	11.15	1.90	11.20	1.85
	G	8.70	2.20	8.75	2.15
T=7	A	0.00	22.80	0.00	22.75
	B	7.90	21.25	7.85	21.25
	C	10.30	21.40	10.25	21.35
	D	15.15	20.15	15.10	20.25
	E	13.70	2.70	13.65	2.60
	F	10.85	1.85	10.75	1.85
	G	8.60	2.00	8.50	1.95

TABLE II  
COORDINATE MEASUREMENTS FROM THE LATERAL RADIOGRAPHS  
MONKEY M-2

EXAMINATION	SIDE	OPERATOR #1		OPERATOR #2	
		x	y	x	y
T=0	Ref.	13.20	1.70	13.25	1.75
	Treat.	12.70	2.60	12.80	2.55
T=7	Ref.	13.05	1.90	13.05	1.95
	Treat.	12.90	3.60	12.90	3.55
T=14	Ref.	12.80	2.15	12.80	2.20
	Treat.	12.85	3.95	12.95	4.00

origin or reference point in all the graphs. Point A was always on the "y" axis above point H. If there were no experimental error and no change in the relationship between these four corner points, their coordinates would remain unchanged from one examination to the next. Therefore, a measure of the variability of the coordinates of the three points A, D, and E would be an indicator of experimental error and actual mobility of these three points in the anchor unit.

The selected measures of variability for the coordinates were the standard deviations of the respective coordinate values. These were the "x" and "y" values for each point for each examination. After all calculations were completed, it was found that the average standard deviation was 0.07 mm. The 99 percent confidence limits indicated that a point in the anchor unit lay in a square measuring 0.37 mm. x 0.37 mm. This was the measure of uncertainty in the location of these important points in the anchor unit and most of this was due to experimental error rather than to movement of the points. The anchor unit gave evidence of great stability within its own framework.

#### C. Gross Interpretation of the Data:

##### (1) Movement of the Mandibular Second Premolar Teeth.

A force system applied to a tooth can cause movement of that tooth in any one or a combination of the three planes of

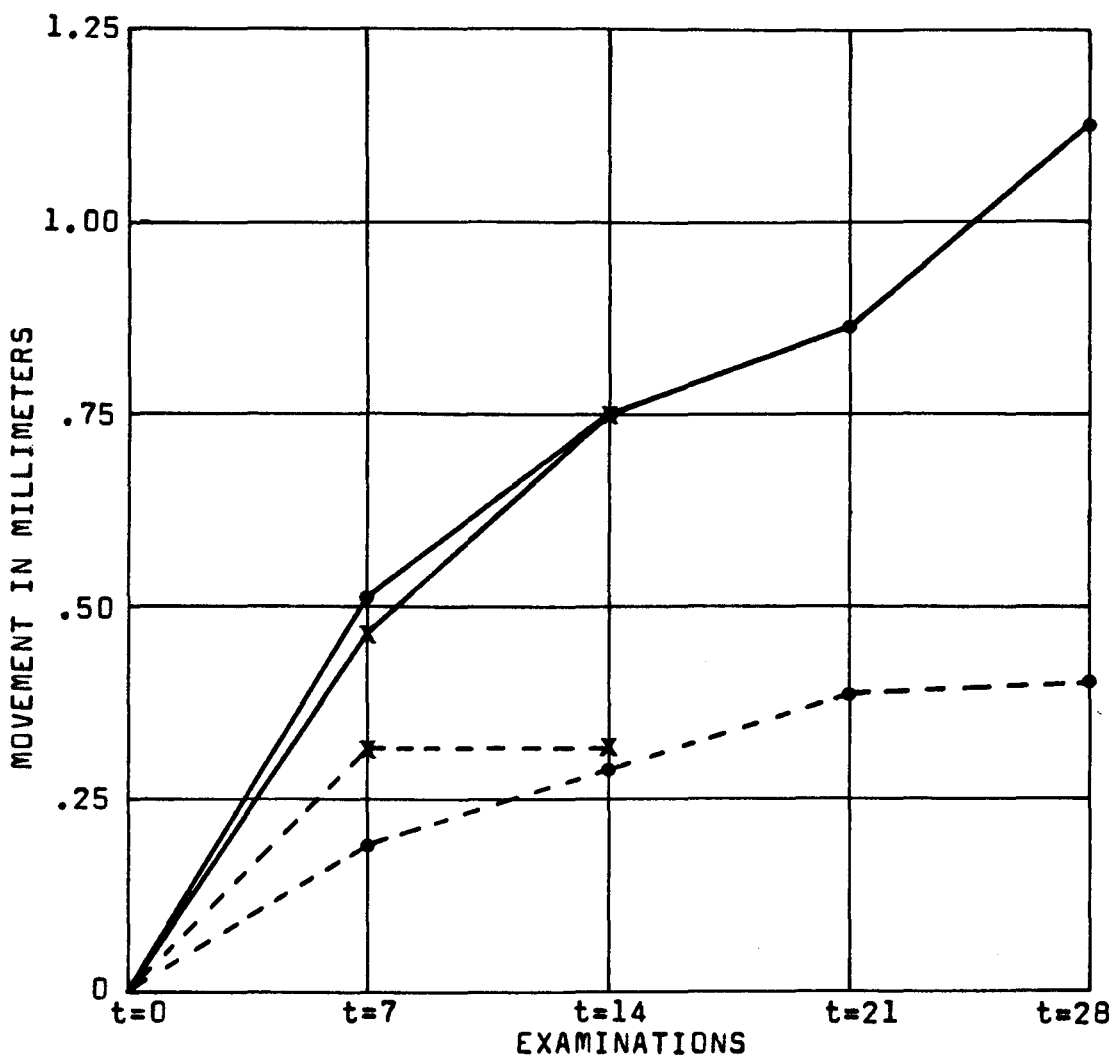
space. An examination of the original data from the occlusal radiographic records of the two animals revealed distal movement of the mandibular second premolar teeth on the treatment sides and some movement on the reference sides. The graph in Figure 17 illustrates these movements. The readings made by the two operators were averaged. The slope formed by connecting the points on the graph indicated the trend and magnitude of tooth movement. A rising line through the successive examinations denotes a distal movement of the crowns of the second premolar teeth.

#### (2) Rotation of the Mandibular Second Premolar Teeth Around Their Long Axes.

When a mesial-distal force is applied to the buccal surface of a tooth a few millimeters from its long axis, as was done in this experiment, a rotation of that tooth about the long axis can be expected. The original data from the occlusal radiographic records were used to determine whether any rotations resulted from the application of the force system in this study. The data were also used to check for rotations of the reference side teeth.

As mentioned in Chapter III, Methods and Materials, each mandibular second premolar tooth had two small amalgam fillings in its occlusal surface. The coordinates of these two points were used to determine a line representing the tooth position

DISTAL MOVEMENT OF THE MANDIBULAR  
SECOND PREMOLAR TEETH



TREATMENT SIDE  
M-2 —●—●—  
M-2A —×—×—  
REFERENCE SIDE  
M-2 - - - ● - - -  
M-2A - - - × - - -

FIGURE 17

as viewed occlusally. If the angular position of this line changed from one examination to the next, it signified a rotation of the tooth.

The following is a sample calculation to determine the angle of a line on the coordinate system. The values were taken from the data for animal M-2, examination T=0.

	x	y
Point B	8.40	21.23
Point C	10.85	21.35

$$\text{Arc tangent of the angle} = \frac{Y_B - Y_C}{X_B - X_C}$$

$$\text{Arc tangent of the angle} = \frac{21.23 - 21.35}{8.40 - 10.85} = \frac{0.12}{2.45} = 0.0490$$

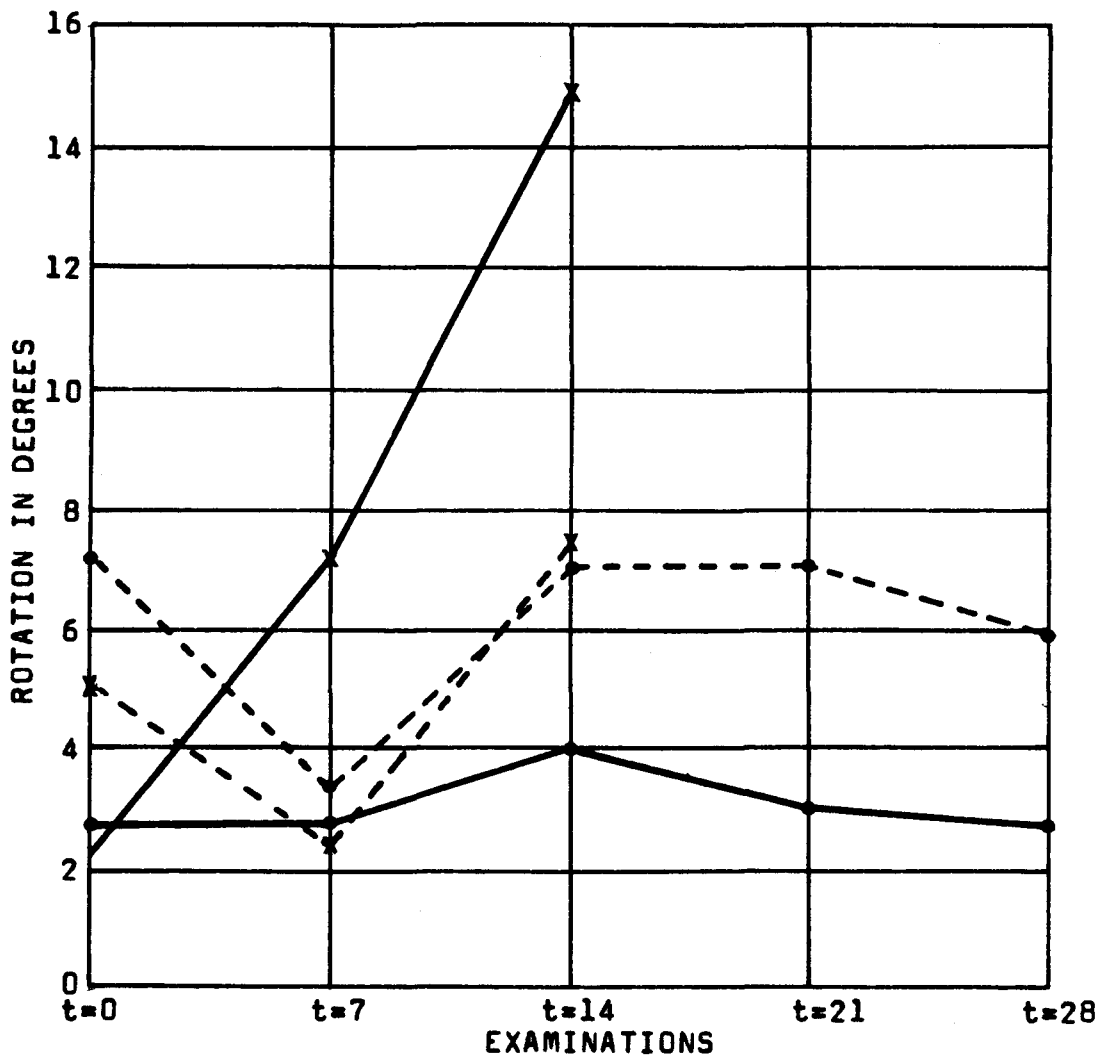
$$\text{Angle} = 2 \text{ degrees } 49 \text{ minutes}$$

The graph in Figure 18 illustrates the original angular position of the premolar teeth on both treatment and reference sides at the beginning of the experiment and during the successive examinations. A rising graph line for a premolar on the treatment side indicates a distal rotation. A rising graph line for a premolar on the reference side denotes a mesial rotation.

### (3) Horizontal and Vertical Movement of the Mandibular Second Premolar Distal Root Apices.

The original data from the lateral periapical radiographs were used to prepare the graphs in Figures 19 and 20.

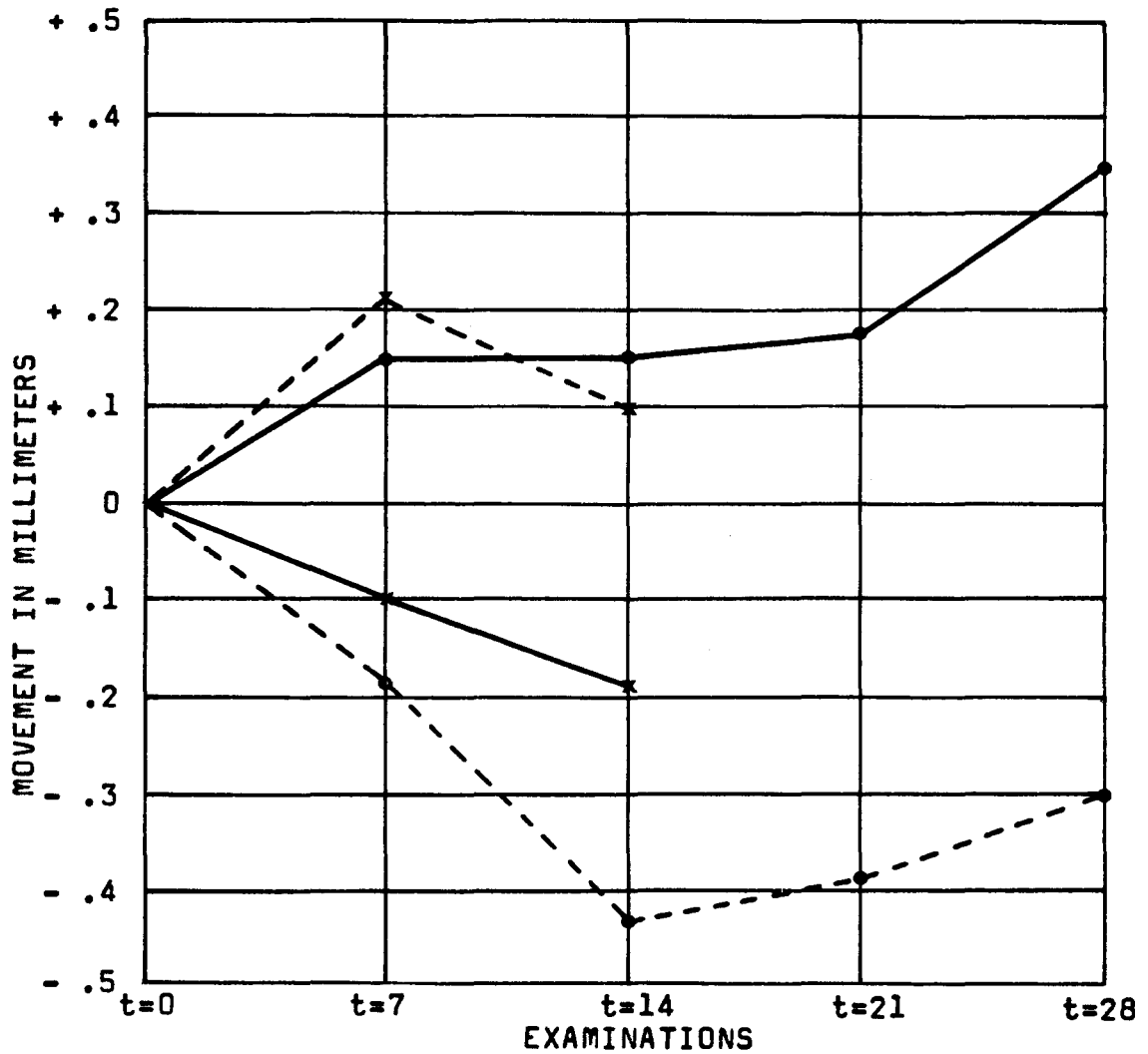
ROTATION OF THE MANDIBULAR SECOND PREMOLAR  
TEETH AROUND LONG AXES



TREATMENT SIDE  
M-2 —●—●  
M-2A —x—x  
REFERENCE SIDE  
M-2 - - - ● - - - ●  
M-2A - - - x - - - x

FIGURE 18

HORIZONTAL MOVEMENT OF THE MANDIBULAR  
SECOND PREMOLAR DISTAL ROOT APICES



TREATMENT SIDE  
M-2                   ●———●  
M-2A                  x———x  
REFERENCE SIDE  
M-2                   ○-----○  
M-2A                  x-----x

FIGURE 19



VERTICAL MOVEMENT OF THE MANDIBULAR  
SECOND PREMOLAR DISTAL ROOT APICES

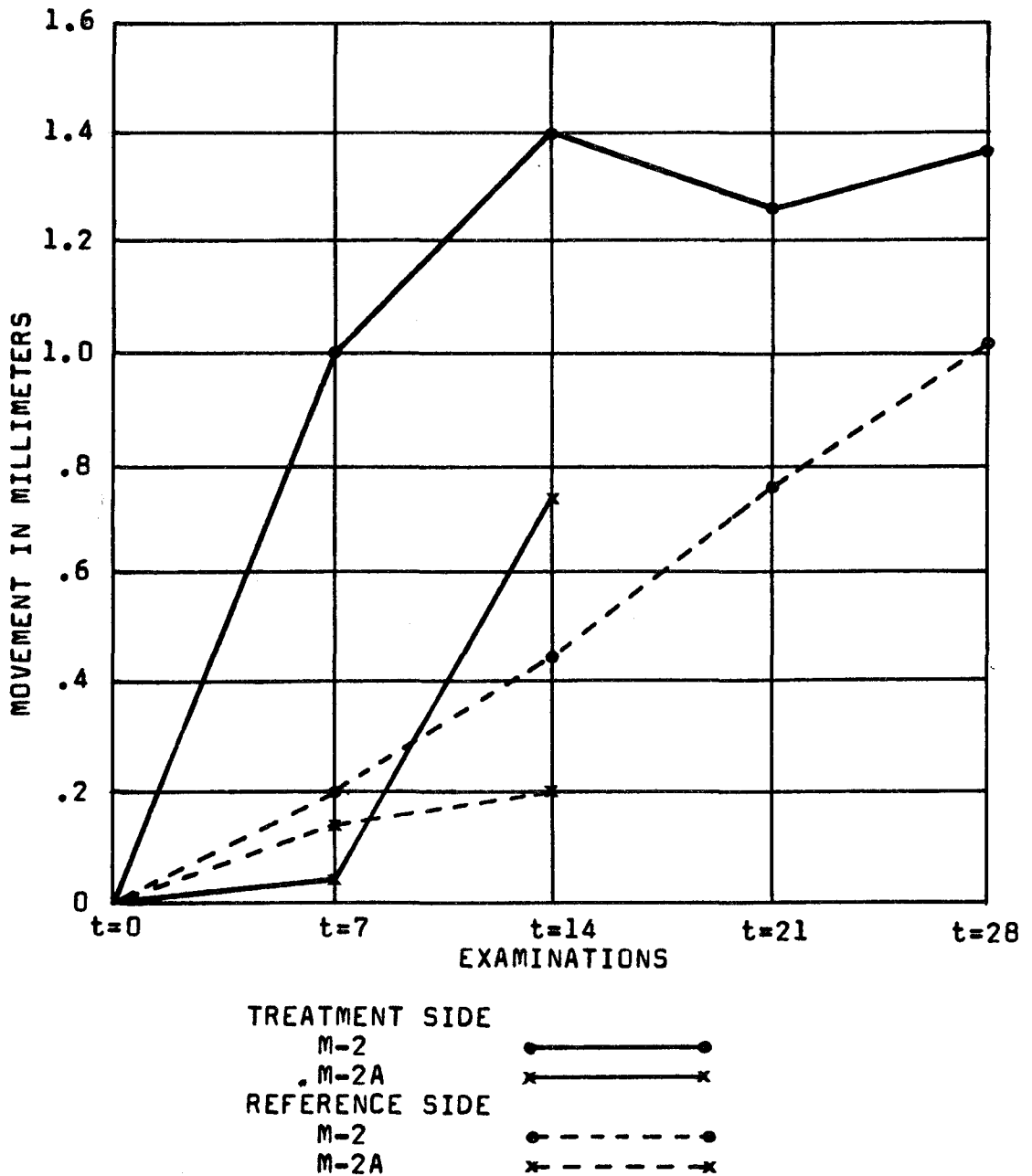


FIGURE 20

They indicate the positions of the distal root apices of the mandibular second premolar teeth on the treatment and reference sides in the serial records. The readings of the two operators were averaged and the differences between the first and successive readings were used as a basis for the graphs. Figure 19 illustrates the change of the apex position in a horizontal direction. Positive readings denote a mesial movement while negative readings denote a distal movement of the apex. The graph in Figure 20 indicates a vertical change in the position of the apex. Rising graph lines indicate extrusion of the teeth.

#### D. Analysis of Variance:

Fisher's Analysis of Variance was used to analyze the data in this experiment. The advantage of this analysis is that data which reveal little to gross inspection can be evaluated more critically. Minute trends and changes are separated from the gross data. Two separate analyses were performed. The data from the occlusal radiographic records were used for one analysis while the data from the lateral periapical radiographic records were used for the second analysis.

The main sources of variation for the analysis of the variance in the data from the occlusal records were Operators, Animals, Sides, Examinations, and Points. There were two

operators, two animals, two sides to each animal, three examinations, and three points on each side. Animals represented a random sample from a larger population while each of the other sources of variation represented a complete distribution or population. This was the basic plan of the analysis.

The error variance or the estimate of experimental error was 0.0025. The standard error or the square root of 0.0025 was plus and minus 0.0496 mm. The 99 percent confidence limits of such a distribution of experimental errors are plus and minus 0.133 mm. This was equivalent to between  $2\frac{1}{2}$  and 3 times the least count of the measuring instrument which is 0.05 mm. or the smallest readable increment on its scale. This magnitude of experimental error was acceptable from the practical point of view.

The results of the complete statistical analysis shown in Table III will not be discussed in detail but a few explanatory remarks may be helpful. Among the main sources of variation, it can be seen that there was a very significant difference between the two animals, between the various examinations, and between the numerous points measured. In this experiment, however, the important findings lay not in the main sources of variation themselves but in the interaction between these sources of variation.

TABLE III  
ANALYSIS OF VARIANCE - OCCLUSAL RADIOGRAPHS

SOURCES	DF	SS	MS	VR	SIGNIFICANCE
OPERATORS	1	0.0001	0.0001	<1	N.S.
ANIMALS	1	156.3501	156.3501	6,260.00	8.5 (.5%)***
SIDES	1	0.1089	0.1089	<1	N.S.
EXAMINATIONS	2	2.1715	1.0857	434.00	6.0 (.5%)**
POINTS	2	485.2819	242.6409	141.70	99.0 (1%)**
OxA	1	0.0036	0.0036	1.44	N.S.
OxS	1	0.0023	0.0023	<1	N.S.
OxE	2	0.0092	0.0046	1.84	N.S.
OxP	2	0.0005	0.00025	1.00	N.S.
AxS	1	0.6423	0.6423	257.00	8.0 (.5%)**
AxE	2	0.0363	0.0181	72.30	6.0 (.5%)*
AxP	2	0.3426	0.1713	68.50	6.0 (.5%)*
SxE	2	0.0904	0.0452	18.10	6.0 (.5%)*
SxP	2	6.2355	3.1177	2.72	N.S.
ExP	4	0.6079	0.1519	60.7	4.40(.5%)*
OxAxS	1	0.0020	0.0020	<1	N.S.
AxSxE	2	0.0126	0.0063	2.4	N.S.
SxExP	4	0.2014	0.0503	20.1	4.40(.5%)*
OxAxE	2	0.0180	0.0090	3.6	N.S.
OxAxP	2	0.0008	0.0004	<1	N.S.
AxSxP	2	2.2941	1.1470		
OxSxP	2	0.0004	0.0002	<1	N.S.
OxSxE	2	0.0014	0.0007	<1	N.S.
OxExP	4	0.0014	0.0003	<1	N.S.
OxAxSxE	2	0.0017	0.0008	<1	N.S.
OxAxSxP	2	0.0009	0.0004	<1	N.S.
AxSxExP	4	0.0211	0.0052	2.08	N.S.
OxSxExP	4	0.0010	0.0002	<1	N.S.
OxAxExP	4	0.0027	0.0006	<1	N.S.
OxAxSxExP	4	0.0015	0.0004	<1	N.S.
TOTAL	71	654.4738	405.5763		

ESTIMATE OF EXPERIMENTAL ERROR = 0.0025  
STANDARD DEVIATION OF ERROR =  $\pm$  0.0496 mm.  
99% CONFIDENCE LIMITS =  $\pm$  0.133 mm.

D.F. = DEGREES OF FREEDOM

S.S. = SUMS OF SQUARES

M.S. = MEANS OF SQUARES

\*\*\* = HIGHLY SIGNIFICANT VARIANCE RATIO

N.S. = NON-SIGNIFICANT VARIANCE RATIO

The highly significant interaction of Animals x Sides indicated that the difference between the right and left sides of monkey M-2A was much greater than the difference between the two sides of monkey M-2. This may be attributed to anatomical differences in the animals and to the placement of the amalgams in the crowns. This difference is shown grossly on the graph in Figure 21.

The significant interaction of Animals x Examinations indicated that monkey M-2 and monkey M-2A responded differently at each examination. The measurements differed for each animal at each examination. There was a slightly greater amount of tooth movement in monkey M-2 than in monkey M-2A on the second examination. The graph in Figure 22 demonstrates this interaction.

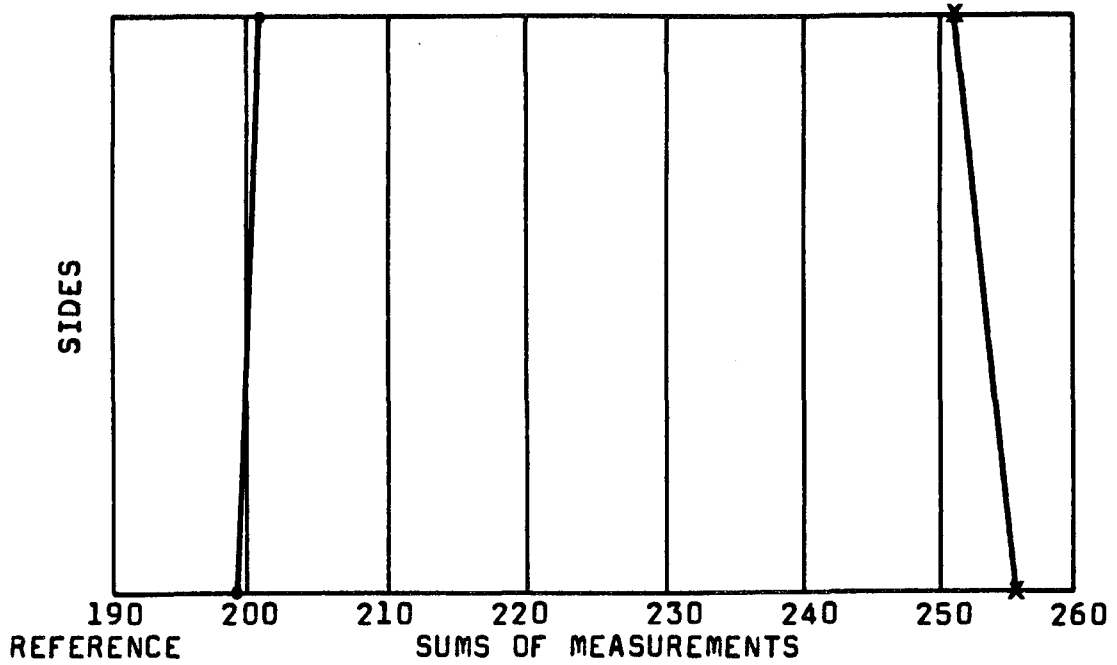
The graph in Figure 23 illustrates the nature of the Animals x Points interaction. Points represent the position of the teeth. Since there is no distinction between right and left sides, the interaction simply demonstrates that points B and G were located more distal to C and F in monkey M-2 than were comparable points in monkey M-2A.

The Sides x Examinations interaction as shown on the graph in Figure 24 was also found to be highly significant. The sums of measurements for the reference side should have been constant at about 154 on each examination; apparently

INTERACTION  
ANIMAL X SIDES

TREATMENT

ANIMALS



ANIMALS

M-2

M-2A



FIGURE 21

INTERACTION  
ANIMALS X EXAMINATIONS

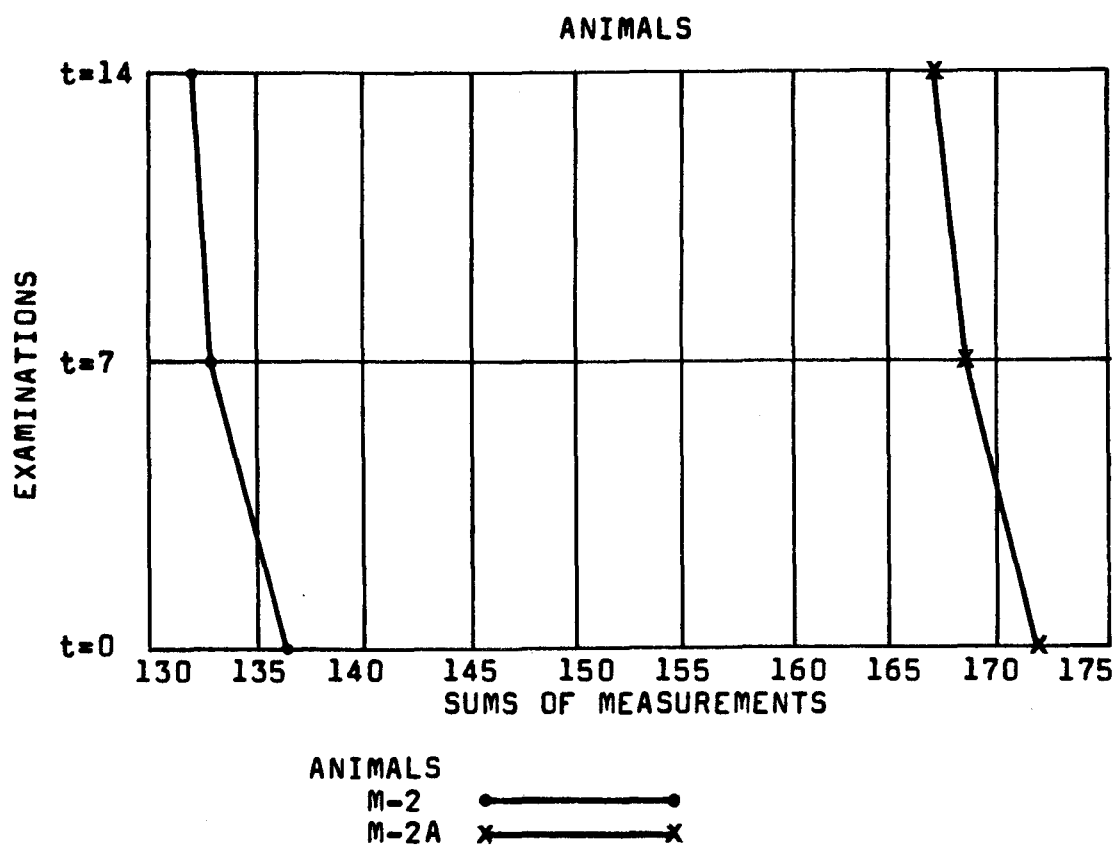


FIGURE 22

INTERACTION  
ANIMALS X POINTS

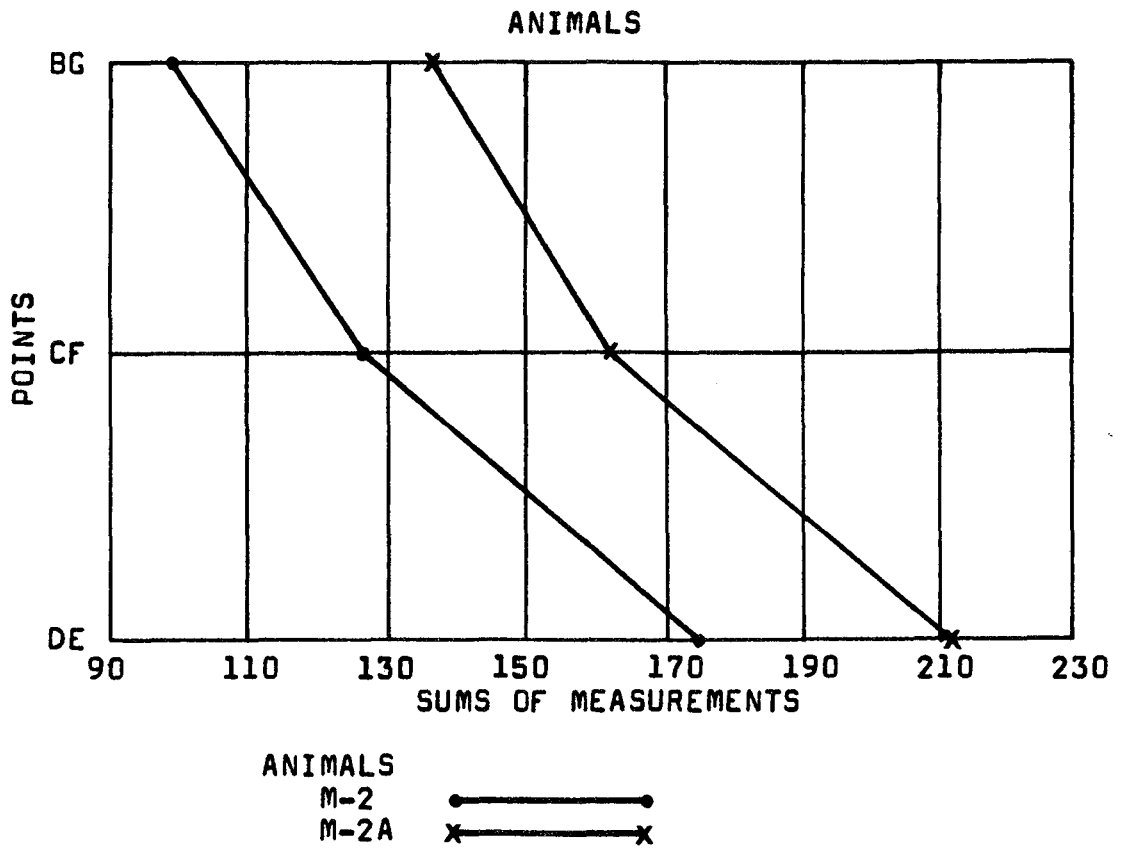


FIGURE 23



### INTERACTION SIDES X EXAMINATIONS

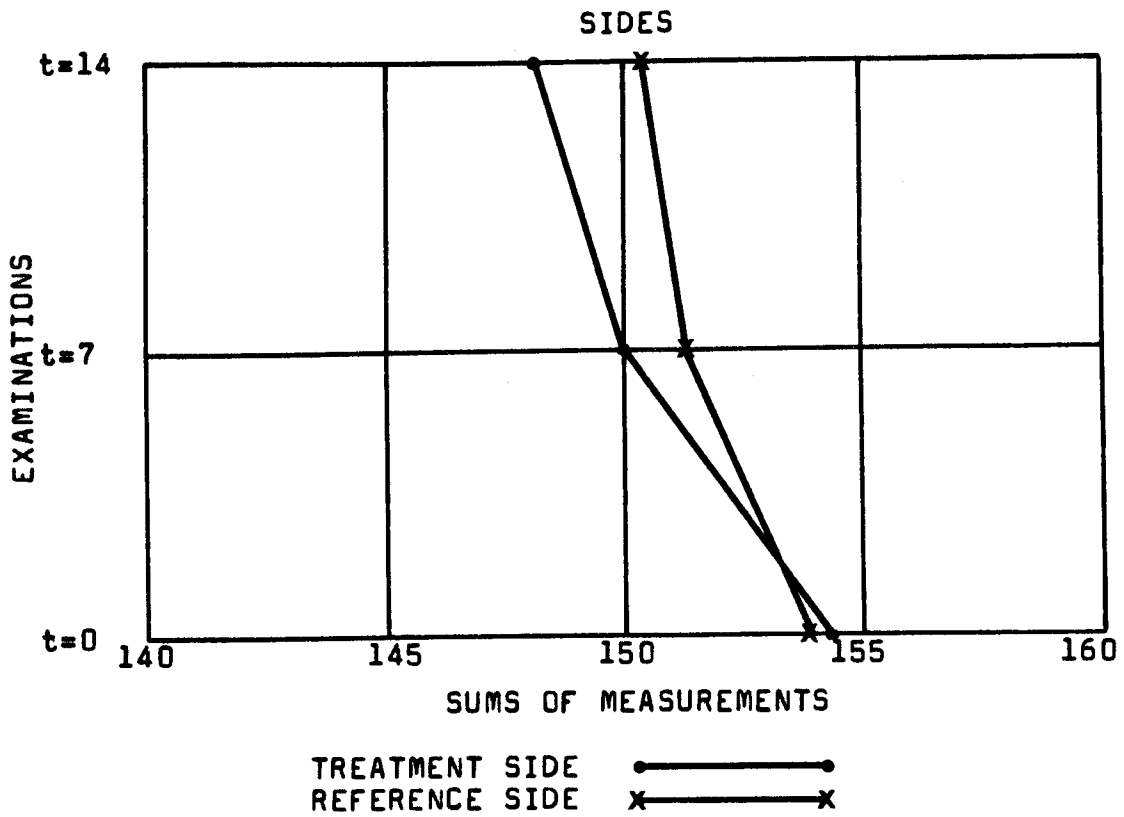


FIGURE 24

there was a slight distal movement. The sums of measurements on the treatment side reduced at each examination indicated a definite distal movement of some of the points.

The Examinations x Points interaction is shown on the graph in Figure 25. Points D and E represent the anchor unit teeth. Their measurements remained uniform during the three examinations. Points B, G, C, and F represent the second premolar teeth on both treatment and reference sides. Their sums of measurements decreased during the three successive examinations.

The main sources of variation for the analysis of the variance of the data from the lateral periapical radiographs were Operators, Animals, Sides, and Examinations. The sample size and degrees of freedom for each main source were described in the preceding analysis on the occlusal data.

The error variance or the estimate of experimental error was 0.0018. The standard error or the square root of 0.0018 was plus or minus 0.0427. The 99 percent confidence limits of such a distribution of experimental errors are plus and minus 0.130 mm. This was equivalent to between  $2\frac{1}{2}$  and 3 times the least count of the measuring instrument which is 0.05 mm. It was comparable to the experimental error calculated from the occlusal data.

The results of the complete statistical analysis are

# INTERACTION EXAMINATIONS X POINTS

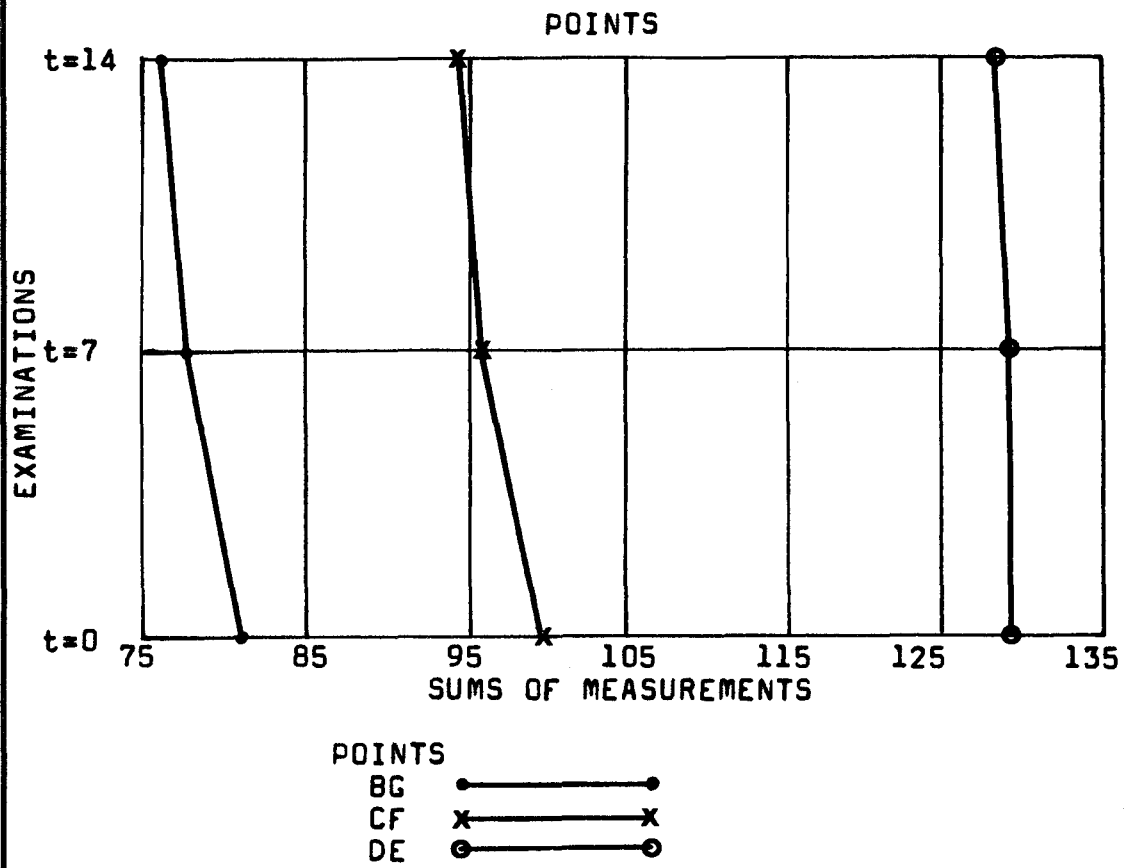


FIGURE 25

shown in Table IV. The last column of this table indicates that animals and examinations were highly significant main sources of variation in this experiment. This means that there was a large difference between the sums of the measurements of the two animals and also large differences between sums of measurements on the separate examinations.

The graph in Figure 26 illustrates the Operators x Sides interaction. It was found significant at the 5 percent level of probability. The measurements by the two operators for the reference side were nearly identical but one operator found a slightly higher total on the treatment side. While this difference is statistically significant, it is not important practically.

The highly significant Sides x Examinations interaction illustrated that the treatment and reference sides of the two animals were different. On the reference side the line should have been vertical indicating a constant sum of measurements at each examination. There was some movement of these teeth. On the treatment side there was a significant distal movement of the teeth as indicated by this interaction. This can be seen on the graph in Figure 27.

#### E. Gross Interpretation of the Radiographs:

##### (1) Occlusal Radiographs.

A gross examination of the occlusal radiographs of monkey

TABLE IV  
ANALYSIS OF VARIANCE - LATERAL RADIOGRAPHS

SOURCES	DF	SS	MS	VR	SIGNIFICANCE
OPERATORS	1	0.0051	0.0051	2.83	N.S.
ANIMALS	1	1.3301	1.3301	246.0	198.0 (.5%)*
SIDES	1	0.0459	0.0459	3.06	N.S.
EXAMINATIONS	2	0.0558	0.0279	15.5	8.19 (.5%)*
OxA	1	0.0009	0.0009	<1	N.S.
OxS	1	0.0084	0.0084	4.67	4.67 (5%)*
OxE	2	0.0008	0.0004	<1	N.S.
AxS	1	0.4134	0.4134	4.18	N.S.
AxE	2	0.0108	0.0054	3.0	N.S.
SxE	2	0.0300	0.0150	8.33	8.19 (.5%)*
OxAxE	2	0.0025	0.00125	1	N.S.
OxAxS	1	0.0009	0.0009	<1	N.S.
OxSxE	2	0.00125	0.00125	<1	N.S.
AxSxE	2	0.1975	0.09875		
OxAxSxE	2	0.0003	0.00015	<1	N.S.
TOTAL	23	2.1049	1.95480		

ESTIMATE OF EXPERIMENTAL ERROR = 0.0018  
STANDARD DEVIATION OF ERROR =  $\pm$  0.0427 mm.  
99 % CONFIDENCE LIMITS =  $\pm$  0.130 mm.

D.F. = DEGREES OF FREEDOM

S.S. = SUMS OF SQUARES

M.S. = MEANS OF SQUARES

\*\*\* = HIGHLY SIGNIFICANT VARIANCE RATIO

N.S. = NON-SIGNIFICANT VARIANCE RATIO

INTERACTION  
OPERATORS X SIDES

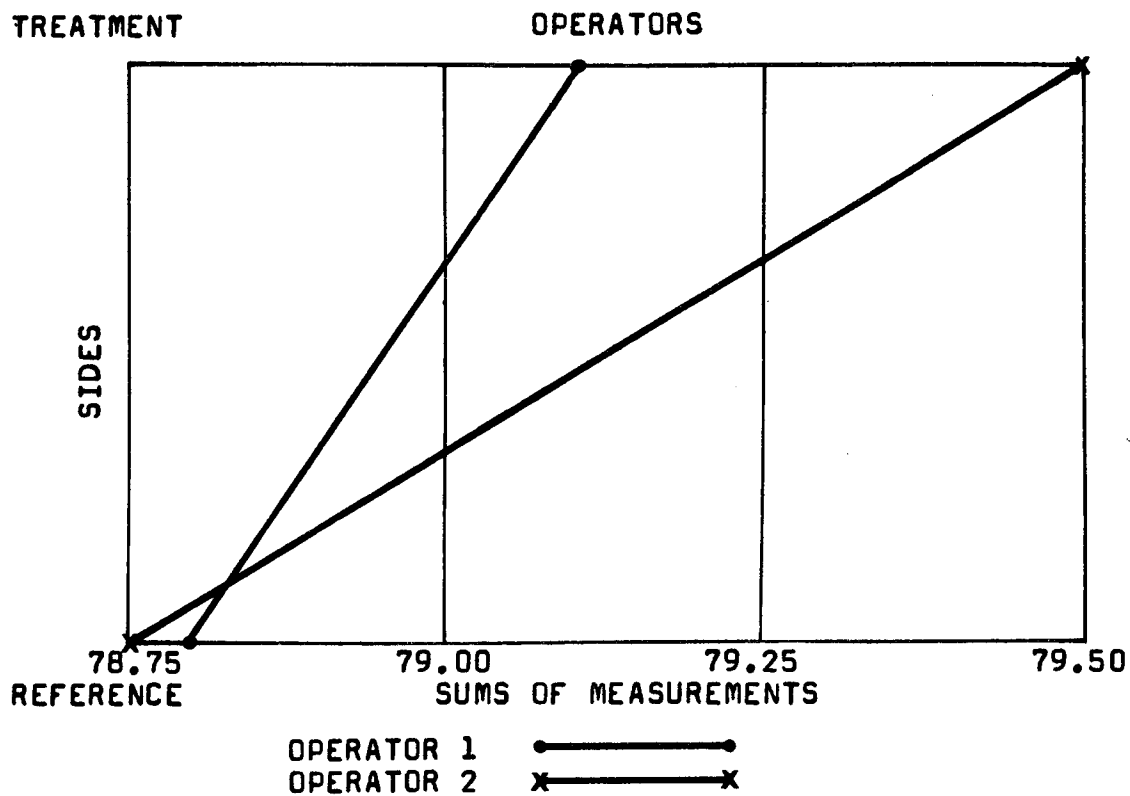


FIGURE 26

INTERACTION  
SIDES X EXAMINATIONS

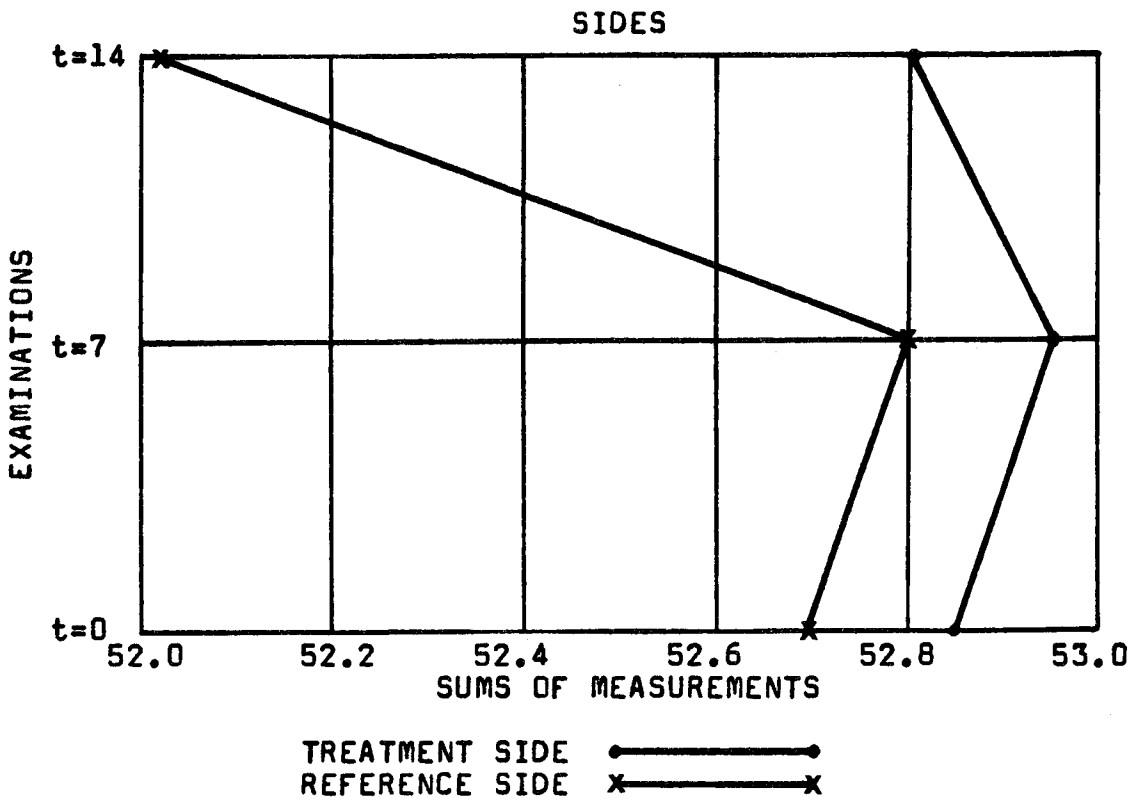


FIGURE 27

M-2 and monkey M-2A revealed the typical morphology of a primate mandible. It was long antero-posteriorly and very narrow. The apices of the posterior teeth were closer to the midline than the crowns as viewed on the occlusal radiographs. The long axes of these teeth were divergent. The teeth were inclined laterally or to the buccal. The anterior teeth were labially inclined. Their root apices were directed posteriorly. This is due to the morphology of the primate mandible because it has no symphysis. The buccal and lingual cortical plates were well delineated in both animals indicating that these structures were well calcified. The cribriform plate around the labially inclined incisors was well defined. The cancellous or spongy bone appeared to have a lace-like heterogeneous trabeculation pattern. The extraction sites of the first molars were still visible. There was evidence that all fourteen of the mandibular permanent teeth were present in both animals before the first molars were extracted.

The components of the experimental orthodontic appliance were seen in each occlusal radiograph. The bands, heavy lingual archwire, the active element tied into the brackets on the treatment side, and the occlusal silver amalgam reference points were all plainly visible.

An examination of the occlusal radiographs for the



successive examinations revealed that the active spring elements deactivated on the treatment sides. The space between the first premolar crowns and the second premolar crowns on the treatment sides increased from the first to the last examination. There was an increase in the space between the premolar crowns on the reference sides of monkey M-2 but no comparable change was seen on the reference side of monkey M-2A. No appliance forces were applied to these teeth.

(2) Lateral Periapical Radiographs.

A gross examination of the mandibular lateral periapical radiographs of monkey M-2 and monkey M-2A revealed a uniformity of general content. The tooth images recorded on each right and left lateral periapical radiograph included the distal one half of the second premolar tooth, the second molar tooth, and the third molar tooth. The mandibular first molars were extracted. The backward slope of the lingual surface of the anterior portion of the mandible does not allow the placement of radiographic film forward to the middle of the second premolar tooth. The second premolars and the second molars were fully developed in both animals. The third molars were unerupted. The third molar crowns were covered by soft tissue in monkey M-2. The crowns and one half of the roots of these teeth were calcified. The dental age of this animal was estimated at 5 years 6 months. The

third molars were covered by a layer of bone in monkey M-2A. Only the crowns of these teeth were calcified. The dental age of this second animal was estimated at 4 years 6 months.

Portions of the experimental orthodontic appliance were visible in all of the lateral periapical radiographs. The active element was attached to the left side of the appliance in both animals. This was the treatment side. No appliance forces were applied to the teeth on the right or reference sides of the animals. An examination of the treatment side lateral periapical radiographs from the successive examinations revealed a deactivation of the contraction loops. The loop in monkey M-2A deactivated in 14 days. It required 28 days for the loop to deactivate in monkey M-2.

The cancellous or spongy bone surrounding the teeth was characterized by a predominately heterogeneous trabeculation pattern in both animals. The trabeculae were closer knit forming smaller marrow spaces approaching the alveolar crest areas. The cribriform plate around the second molar teeth and the distal root of the second premolar teeth was well defined. The extraction sites of the first molars were still evident. Remnants of the cribriform plate were present but its density had decreased when compared with that on the radiographs of the first examination. The mesial root tip of the first molar of monkey M-2 was fractured while this

tooth was being extracted. The oval fragment measuring 1.5 by 3.0 mm. was visible in the alveolus.

The space occupied by the periodontal ligament was seen around each of the teeth in the lateral periapical radiographs taken at the successive examinations. The space was wider on the mesial surface of the distal root of the second premolar on the treatment side of monkey M-2. The space was greater at the alveolar crest than at the apex. The space on the distal surface appeared narrowed. This means that the tooth moved bodily in a distal direction. Some tipping was combined in this movement as indicated by the periodontal space. The periodontal space was also widened around the root apex which means the tooth had extruded. The space occupied by the periodontal ligament around the second molar roots on the treatment side of monkey M-2 was wider on the distal surfaces of the roots than on the mesial surfaces. This did not change in the serial radiographs from the successive examinations. The space around the apices similarly showed no change.

The width of the space occupied by the periodontal ligament around the distal root of the second premolar tooth on the reference side of monkey M-2 increased on the mesial surface as well as at the apex and decreased on the distal surface. This means the tooth moved distally and extruded.

The periodontal space around the second molar roots on the reference side of monkey M-2 remained uniform on the mesial and distal surfaces in the successive films. The space became wider at the apices which means the second molar tooth had extruded.

The space occupied by the periodontal ligament around the distal root of the second premolar tooth on the treatment side of monkey M-2A increased in width on the mesial surface. The space was wider at the alveolar crest than at the apex on this surface. The space also increased in width around the apex. This means there was a combination of bodily movement, tipping in a distal direction, and extrusion. The periodontal space around the roots of the second molar on the treatment side of monkey M-2A remained uniform on the lateral surfaces in the successive radiographs. But, the width of the space increased around the apices which means the second molar extruded.

The space occupied by the periodontal ligament around the distal root of the second premolar tooth on the reference side of monkey M-2A increased in width on the mesial lateral surface and around the apex. The space decreased in width on the distal surface. This means the tooth moved distally and extruded. The periodontal space around the roots of the second molar on the reference side of monkey M-2A increased in width only around the apices which means the tooth extruded.

## CHAPTER V

### DISCUSSION

The purpose of this study was to develop a method of assessing bodily movement of posterior teeth in the rhesus monkey. The Macaque rhesus monkey was selected for this study because its teeth and alveolar environment are nearly like those of man. An experimental appliance to move the mandibular second premolar teeth distally was designed and cemented to the teeth. The force system used to develop a continuous translatory force was designed according to the principles outlined by Jarabak and Fizzell (1963). They place strong emphasis on the biologic aspects of tooth movement. Hence, the force system was designed to produce translation with a high deflection and low force magnitude appliance. Jarabak and Fizzell have shown that such force producing machines fit physiological demands of the periodontium and the alveolar process. A detailed description of the mechanism can be found in Chapter III, Methods and Materials.

In an attempt to remain within the physiologic limits outlined above, a force magnitude of 100 to 125 gm. was selected to translate the mandibular second premolar tooth in this study. Jeffry (1965) and Kostiwá (1965) determined that 60 percent of the suggested optimal force value to

move a human premolar tooth could be used to move a primate premolar tooth. Their determination was based on the ratio of tooth sizes. This force magnitude was sufficient to move the tooth in this experiment. But, because the results of this study were radiographic no conclusion is possible on whether the force selected was optimal or excessive until histologic information is obtained from the tissue sections of these animals.

A radiographic method was used to record changes in tooth position in this experiment. The t-test in a pilot study on the dry skull demonstrated that recording and measuring tooth position on radiographic film was as accurate as measuring directly. Space limitations in the oral cavity of the rhesus monkey and the requirement of prolonged periods of anesthesia prohibited the use of the usual measuring instruments for direct measuring procedures, therefore, this radiographic method of recording was devised. It was considered more practical.

Serial occlusal radiographs and serial lateral periapical radiographs were taken for the total assessment of tooth movement. The information was transferred from the radiographs to a rectangular coordinate system on graph paper. Points on the graphs represented the teeth. Measurements were made between the points to determine tooth

movement. This constituted the data. Statistical analyses demonstrated that this method of recording and quantitating tooth movement was precise. The experimental error was calculated at plus and minus 0.133 mm. This was between 2 and 3 times the least count (0.05 mm.) of the measuring instrument used to make the measurements. A search of the literature revealed that few methods have evolved which are precise, accurate, and practical in spite of the many studies requiring the documentation and measurement of tooth movement. One very imaginative technique was developed by Jeffry (1965) and Kostiwa (1965) in a preceding thesis which proved very precise. Unfortunately, their method was not feasible in this study because the appliance used in this experiment included more teeth making them unsuitable for points of reference. Therefore, fillings were placed into certain teeth for purposes of creating reference points which would show up on x ray films and from which tooth movements could be determined.

The preciseness of this method can be attributed to several factors. The reliability of the stereotaxic instrument built for this experiment is one of these factors. It was used to accurately position the head and jaws of the experimental animal for the serial radiographic records at the successive examinations. An indirect measure of the

reliability of the instrument was embodied in the determination of the stability of the anchor unit points in Chapter IV, Findings. It was found that the range of movement of the individual anchor unit points was a square measuring 0.37 x 0.37 mm. This is a small degree of error. If the head of the animal was not placed in the same spatial relationship at each examination, the error would be greater.

The accurate conversion of the radiographic records to the rectangular coordinate system as outlined in detail in Chapter III, Methods and Materials, and measuring with a precision vernier caliper were additional factors contributing to the accuracy and precision of the method devised to quantitate tooth movement.

The results of the total assessment of tooth movement in this study are included in the preceding chapter. There are, however, several individual tooth movements which need further explanation.

The mandibular second premolar tooth on the treatment side of monkey M-2 tipped distally. The crown moved distally while the distal root apex moved mesially. The tipping axis was located above the level of the root apices. There was no rotation of this tooth on its long axis but the tooth did extrude. The mandibular second premolar tooth on the treatment side of the other animal, monkey M-2A, also tipped



distally. The distal root apex of this tooth moved in the same direction, however, the crown moved to a greater degree than the root. Hence, the tipping axis was located below the root apices. The tooth rotated distally on its long axis as a result of the applied force and it also extruded.

The foregoing pointed out that there was a different axis of tipping for the second premolar teeth on the treatment sides of the two animals. The theoretical aspects of translation were fully considered in the design of the force system. It was stated in Chapter III that the magnitudes of the force and couple had to be in delicate balance for translation to occur. The force system produced a greater tipping moment than couple in monkey M-2. The tooth tipped around an axis within the projected root surface area. The magnitudes of the moment of force and couple were more nearly balanced in monkey M-2A. Here, a combination of bodily movement and tipping occurred but the axis of tipping was below the root apex. The above statement should be cogent in future studies. The ratio of the tipping moment to the righting couple is important in determining where the axis of tipping is going to be. To amplify this statement, it is safe to say that the righting couple and the tipping moment should be nearly identical if pure translation is desired. Moyers and Bauer (1950) observed that the translation

of a tooth was an extremely difficult movement to achieve and the results of this experiment seem to support their observation. The results of Alexander (1962) revealed a tipping movement in his attempt to translate the mandibular molars of a rhesus monkey. Huettner and Young (1955) also reported tipping while attempting to translate endodontically treated teeth.

The mandibular second premolar tooth on the treatment side of monkey M-2A rotated distally while the comparable tooth of monkey M-2 did not. This was caused by different bracket positions on the teeth of the two animals. The bracket was positioned inadvertently more distal on the second premolar tooth of monkey M-2 while a more ideal bracket position was achieved in monkey M-2A. When the active element was ligated into the respective brackets, no distal rotation of the tooth could take place in monkey M-2. The bracket was already to the distal. A rotation of 12 degrees occurred in monkey M-2A before the restricting action of the archwire countered the turning moment that caused the rotation.

The results were quite different on the reference or non-treatment side. It must be remembered, however, there were no orthodontic forces applied to these mandibular second premolar teeth. Whatever tooth movements did take place were those occurring as a result of other factors. The tooth of

monkey M-2 showed a combination distal translatory movement with tipping while the tooth of monkey M-2A simply tipped distally.

Improbable as these tooth behaviors may seem on the reference side there is a logical explanation for their occurrence. The tipping in monkey M-2A we can readily accept. Translation of the premolar tooth in the other animal, monkey M-2, requires an explanation. Since the premolar teeth in the two animals were out of occlusion we must eliminate incline plane influence of the antagonist teeth as a factor causing this movement. This leaves one alternative, the manner in which healing of the alveolar process occurred where the first molar teeth were extracted.

Knowing that internal stresses develop in healing bone, it is conceivable that these stresses were not alike in the extraction sites of the two animals. On the strength of this phenomenon in bone, one can readily speculate that tipping of the premolar tooth in one animal was caused by the same healing factors that caused the translation in the other.

All of the mandibular second premolar teeth extruded on both treatment and reference sides. The amount of extrusion is shown on the graph in Figure 20. Placement of the plane in the incisor region opening the bite accounts for the extrusion of these teeth. The teeth on the treatment side

extruded more than those on the reference side. This was probably caused by a vertical component of force developed in the appliance.

This discussion would be incomplete without listing additional shortcomings of the experiment and recommended improvements in the experimental procedure. Awareness of them came only after the study was well underway. For example, it was observed that the ear of the rhesus monkey has a more flexible and perhaps a longer cartilagenous external ear canal than the human ear. It is more easily displaced in any direction than the human ear. As a result, the animal had to be positioned between the ear rods of the stereotaxic instrument very carefully at each examination to avoid a malpositioning. This was a potential source of error. An ear rod diameter of  $5/32$  inch as suggested by Jarabak (1942) was rigidly adhered to. A taper was incorporated into the design from the  $5/32$  inch to prevent excessive penetration of the ear rod into the ear canal. Deep entry could result in the perforation of the tympanic membranes of the animal. Better engagement of the ear canals with the ear rods however would have been desirable. If future studies are to be performed with this apparatus the problem should be investigated.

The posterior teeth extruded because a bite plane was placed on the maxillary incisor teeth. A method suggested

for future experiments where the bite must be opened to eliminate interferences and where extrusion is not desirable is to construct a full arch bite plane. The entire maxillary arch could be covered with a cast metal plane. It would provide a continuous surface against which the mandibular teeth could occlude. Yet, there would be no localized areas of extrusion and all functional interferences to tooth movement would be eliminated.

CHAPTER VI  
SUMMARY AND CONCLUSIONS

A. Summary:

This study was undertaken to design a method to assess the translatory movement of a mandibular second premolar tooth of a Macaque rhesus monkey in an environment in which the tooth was out of normal occlusion. The experimental force system was based on the principles of high deflection and low force magnitude. It was designed to produce a continuous translatory force of known magnitude for controlled tooth movement.

The physical method of recording tooth movement was radiographic. Occlusal radiographs and mandibular lateral periapical radiographs were taken. A stereotaxic instrument was devised to position the head and jaws of the experimental animal into the same spatial relationship for the serial radiographs which were taken at the beginning of the experiment, during and on termination of the experiment. Selected points on the radiographs representing the teeth were transferred to a rectangular coordinate system. Precise measurements between these points yielded the data for the experiment. Total assessment included changes in a mesio-distal direction, a bucco-lingual direction, a superio-inferior direction,

and rotation. Statistical tests were applied to the data to determine the reliability of the measuring system, precision of measurements, and the reliability of the method.

#### B. Conclusions:

1. This study provided a method of assessing experimental movement of the mandibular second premolar tooth of a rhesus monkey. The method assessing tooth movement was shown to be accurate, precise, and practical.

2. A force system was designed for controlled tooth movement. Principles of high deflection and low force magnitude described by Jarabak and Fizzell (1963) were used to develop a continuous translatory force. The force system was successfully adapted to the rhesus monkey.

3. The physical method of recording experimental tooth movement in this study was radiographic. Occlusal films were used to document movement from the occlusal aspect. Parallel placed periapical films were used to document movement from the lateral aspect. This method of recording tooth movement was shown to be reliable and practical.

4. The specially designed stereotaxic instrument made the serial or progress roentgenographic records possible. It was used to position the head of the animal into the same spatial relationship for the radiographs at each examination. The experiment demonstrated that this instrument was reliable.

5. An indirect method of measuring tooth movement was developed. The radiographic records were converted to rectangular coordinates. The data consisted of "x" and "y" coordinates for each tooth for the successive examinations. Tooth movement was revealed by changes in the coordinate readings. This method was shown to have advantages over direct methods of measuring tooth movement in the experimental animal.

6. The assessment of tooth movement revealed that the force system produced a bodily movement modified by tipping in one animal and a tipping movement in the other. This was accounted for by a lack of balance in the magnitudes of the force and couple produced by the force system. The teeth also rotated on their long axes and extruded.

7. The experimental movement of the teeth ascertained through indirect measurement correlated with the findings of the visual examination of the serial radiographic films.

8. The instruments designed and methods developed for this study can be helpful in future similar studies. They are worthy of consideration where experimental tooth movement, the effectiveness of a force system, or the effect of a force system on the tissues is to be studied.



## BIBLIOGRAPHY

- Aisenberg, M. S. The tissues and changes involved in orthodontic tooth movements. *American Journal of Orthodontics*, 34:854-856, 1948.
- Alexander, C. M. Force control in bodily movement of the lower first molar in the monkey. *American Journal of Orthodontics*, 48:221-222, 1962.
- Atta, A. E. Force magnitude and center of rotation, histologic study in rhesus monkey. M. S. Thesis. Indiana University, 1964.
- Breitner, C. Bone changes resulting from experimental orthodontic treatment. *American Journal of Orthodontics and Oral Surgery*, 26:521-547, 1940.
- Burstone, C. J. The biomechanics of tooth movement. *Vistas in Orthodontics*. Kraus, et al., Lea and Febiger, Philadelphia, 1962.
- Burstone, C. J. and Groves, M. H. Threshold and optimum force values for maxillary anterior tooth movement. *Journal of Dental Research*, 39:695, 1960.
- Dolowy, W. C., D.V.M. University of Illinois Research Center. Personal Communication.
- Haack, D. C. The science of mechanics and its importance to analysis and research in the field of orthodontics. *American Journal of Orthodontics*, 49:330-344, 1963.
- Heimlich, A. F. Tissue changes incident to tooth movement. *International Journal of Orthodontia*, 21:1022-1026, 1937.
- Hemley, S. The clinical significance of tissue changes incidental to tooth movement. *American Journal of Orthodontics*, 41:5-26, 1955.
- Herzberg, B. L. Bone changes incident to orthodontic tooth movement in man. *The Journal of the American Dental Association*, 19:1777-1787, 1932.

- Huettner, R. J. and Whitman, C. L. Tissue changes occurring in the Macaque rhesus monkey during orthodontic movement. *American Journal of Orthodontics*, 44:328-345, 1958.
- Huettner, R. J. and Young, R. W. The movability of vital and devitalized teeth in the *Macacus rhesus* monkey. *American Journal of Orthodontics*, 41:594-603, 1955.
- Jarabak, J. R. Development of a treatment plan in the light of one's concept of treatment objectives. *American Journal of Orthodontics*, 7:481-514, 1960.
- Jarabak, J. R. Animal cephalometry. *The Angle Orthodontist*, 12:87-93, 1942.
- Jarabak, J. R. and Fizzell, J. Technique and Treatment with the Light Wire Appliance. The C. V. Mosby Co., St. Louis, 1963.
- Jeffry, G. J. Biophysical assessment of a reciprocal vertical force system on posterior teeth in normal functional occlusion. M. S. Thesis. Loyola University Dental School, 1965.
- Johnson, A. L., Appelton, J. L., and Rittershofer, L. S. Tissue changes involved in tooth movement. *International Journal of Orthodontia*, 12:889-898, 1926.
- Kostiwa, D. Biophysical assessment of a reciprocal vertical force system on posterior teeth out of occlusion in a rhesus monkey. M. S. Thesis. Loyola University Dental School, 1965.
- Lane-Petter, W., Editor. *Animals for Research*. Academic Press, London and New York, 1963.
- Marshall, J. A. A study of bone and tooth changes incident to experimental tooth movement and its application to orthodontic practice. *The International Journal of Orthodontia and Dentistry for Children*, 19:1-21, 1944.
- Moyers, R. E. and Bauer, J. L. The periodontal response to various tooth movements. *American Journal of Orthodontics*, 36:572-581, 1950.
- Moyers, R. E. The periodontal membrane in orthodontics. *The Journal of the American Dental Association*, 40:22-27, 1950.

- Myers, H. I. and Wyatt, W. P. Some histopathologic changes in the hamster as the result of a continuously acting orthodontic appliance. *Journal of Dental Research*, 40:846-855, 1961.
- Ockerse, T. The histology of the teeth of the vervet monkey. *Journal of the Dental Association of South Africa*, 18:35-40, 1963.
- \_\_\_\_\_ The anatomy of the teeth of the vervet monkey. *Journal of the Dental Association of South Africa*, 1959.
- Oppenheim, A. Tissue changes, particularly of the bone, incident to tooth movement. *American Orthodontist*, 3:57-67, 113-132, 1911.
- \_\_\_\_\_ Human tissue response to orthodontic intervention of short and long duration. *American Journal of Orthodontics and Oral Surgery*, 28:263-300, 1942.
- Orban, B. Biologic problems in orthodontia. *The Journal of the American Dental Association*, 23:1849-1870, 1936.
- Reitan, K. Bone formation and resorption during reversed tooth movement. *Vistas in Orthodontics*. Krans, et al., Lea and Febiger, Philadelphia, 1962.
- \_\_\_\_\_ Tissue changes following experimental tooth movement as related to the time factor. *Dental Record*, 73:559-568, 1953.
- \_\_\_\_\_ Some factors determining the evaluation of forces in orthodontics. *American Journal of Orthodontics*, 43:32-45, 1957.
- \_\_\_\_\_ Retraction of upper canines after removal of first premolars. Relation to tissue reaction. *European Orthodontic Society Treatise*, 34:172-176, 197-210, 1958.
- \_\_\_\_\_ Tissue rearrangement during retention of orthodontically rotated teeth. *The Angle Orthodontist*, 24:105-113, 1959.
- \_\_\_\_\_ Tissue behavior during orthodontic tooth movement. *American Journal of Orthodontics*, 46:881-900, 1960.
- Sandstedt, C. Einige Beitrage zur Theoria den Zahnregulier-

- ung. Nordisk Tandlakare Tidsskrift, No. 4, 1904, No. 1, 1905. N.U.D.S. Translation by G. W. Rapp.
- Saur, R. M., Editor. Care and diseases of the research monkey. Annuals of the New York Academy of Sciences, 85:735-992, 1960.
- Selman, A. J. and Sarnat, B. G. A headholder for serial roentgenography of the rabbit skull. The Anatomical Record, 4:627-634, 1953.
- Schwarz, A. M. Tissue changes incidental to orthodontic tooth movement. International Journal of Orthodontia, 18:331-352, 1932.
- Sicher, H. and Weinmann, J. P. Bone growth and physiologic tooth movement. American Journal of Orthodontics, 30:109-132, 1944.
- Storey, E. Bone changes associated with tooth movement. A radiographic study. The Australian Journal of Dentistry, 2:57-64, 1953.
- Storey, E. and Smith, R. Force in orthodontics and its relation to tooth movement. The Australian Journal of Dentistry, 56:11-18, 1952.
- The importance of force in orthodontics. The Australian Journal of Dentistry, 56:291-304, 1952.
- Talbot, E. S. Irregularities of the Teeth and their Treatment. The S. S. White Dental Manufacturing Company, Philadelphia, 1903.
- Wentz, F. M., Jarabak, J., Orban, B. Experimental occlusal trauma imitating cuspal interferences. Journal of Periodontology, 29:117-127, 1958.
- Willian, D. E. The effect of continuous torquing forces on maxillary central incisors in Macaque rhesus monkeys. M. S. Thesis, Indiana University School of Dentistry, 1964.

APPROVAL SHEET

The thesis submitted by Dr. Jerry F. Lerch has been read and approved by members of the Departments of Anatomy and Oral Biology.

The final copies have been examined by the director of the thesis and the signature which appears below verifies the fact that any necessary changes have been incorporated, and that the thesis is now given final approval with reference to content, form, and mechanical accuracy.

The thesis is therefore accepted in partial fulfillment of the requirements for the Degree of Master of Science.

May 24-1966  
Date

Joseph R Jurabak  
Signature of Advisor