



1985

## A Comparative Morphological Study of the Intrarenal and Intrahepatic Lymph Systems of the Rat

George K. Niiro  
*Loyola University Chicago*

Follow this and additional works at: [https://ecommons.luc.edu/luc\\_diss](https://ecommons.luc.edu/luc_diss)



Part of the [Medicine and Health Sciences Commons](#)

---

### Recommended Citation

Niiro, George K., "A Comparative Morphological Study of the Intrarenal and Intrahepatic Lymph Systems of the Rat" (1985). *Dissertations*. 2347.

[https://ecommons.luc.edu/luc\\_diss/2347](https://ecommons.luc.edu/luc_diss/2347)

This Dissertation is brought to you for free and open access by the Theses and Dissertations at Loyola eCommons. It has been accepted for inclusion in Dissertations by an authorized administrator of Loyola eCommons. For more information, please contact [ecommons@luc.edu](mailto:ecommons@luc.edu).



This work is licensed under a [Creative Commons Attribution-Noncommercial-No Derivative Works 3.0 License](#).  
Copyright © 1985 George K. Niiro

A COMPARATIVE MORPHOLOGICAL STUDY OF THE  
INTRARENAL AND INTRAHEPATIC  
LYMPH SYSTEMS OF THE RAT

by

George K. Niiro

A Dissertation Submitted to the Faculty of the Graduate School  
of Loyola University of Chicago in Partial Fulfillment  
of the Requirements for the Degree of  
Doctor of Philosophy

January

1985

DEDICATION

To the Old and New

## ACKNOWLEDGEMENTS

First and foremost, I would like to express my sincere appreciation and gratitude to Charles C.C. O'Morchoe for his help and guidance throughout my graduate education. He has unselfishly given much of his time and effort towards the completion of this project.

I am also indebted to the members of my committee. Their comments and criticisms were particularly appreciated.

I would also like to thank all the members of the Department of Anatomy. They not only provided assistance when needed but the fellowship and familiarity of good friends. Special thanks are extended to Harriet Jarosz and Linda Fox for their excellent technical help.

Finally, I would like to thank my family for their continued support and encouragement. In particular, my wife, Teresa, has been of invaluable help and, without her, this work would not have been possible. I thank her.

## VITA

The author, George K. Niiro, is the son of Kohei and Chieko Niiro. He was born in Osaka, Japan on December 1, 1949.

His elementary and secondary education were received in the Chicago public schools. He graduated from Hyde Park High School in June of 1967. He attended the University of Michigan, Ann Arbor, Michigan from 1967 to 1971 and from 1973 to 1974, where he received the Bachelor of Science degree in Electrical Engineering in May of 1971 and the Master of Science degree in Bioengineering in August of 1974.

He worked in the Electron Microscopy Laboratory of the Department of Pathology, Loyola University of Chicago from 1975 to 1978. In July of 1978, he entered the Department of Anatomy of the Graduate School at Loyola University of Chicago. He was a recipient of the Loyola University Basic Science Fellowship from 1978 to 1982. He was awarded a Arthur J. Schmitt Fellowship in 1982. While at Loyola, he served as president of the Graduate Student Council.

He is a member of the Eta Kappa Nu Electrical Engineering Honor Society, Sigma Xi Research Society, North American Chapter of the International Society of Lymphology, Midwest Society for Electron Microscopy, Electron Microscopy Society of America and American Association of Anatomists.

He is married to Dr. Teresa Dombrowski Niiro.

## PUBLICATIONS

### Full Publications:

- Niuro, G.K., H.M. Jarosz, P.J. O'Morchoe and C.C.C. O'Morchoe (1982) Computer-assisted analysis of the rat intrarenal lymphatic system. In: Advances in Lymphology. Proceedings of the 8th International Congress of Lymphology. Eds. V. Bartos and J.W. Davidson. Avicenum, Czechoslovak Medical Press, Prague, pp. 73-79.
- Niuro, G.K., H.M. Jarosz, P.J. O'Morchoe and C.C.C. O'Morchoe (1985) The renal cortical lymphatic system in the rat, hamster and rabbit. In preparation.
- Niuro, G.K. and C.C.C. O'Morchoe (1985) The pattern and distribution of intrahepatic lymph vessels in the rat. In preparation.
- Niuro, G.K. and C.C.C. O'Morchoe (1985) An ultrastructural study of transport pathways across hepatic lymph vessels in the rat. In preparation.

### Published Abstracts:

- Niuro, G.K. and C.C.C. O'Morchoe (1981) The ultrastructure of the canine renomedullary interstitial cell. *Anat. Rec.* 199:183A.
- Niuro, G.K., H.M. Jarosz, P.J. O'Morchoe and C.C.C. O'Morchoe (1982) Distribution and size of renal cortical lymphatics in the rat, hamster and rabbit. *Proc. N. Am. Chapt. Int. Soc. Lymph.* 9.

## TABLE OF CONTENTS

	Page
DEDICATION.....	ii
ACKNOWLEDGEMENTS.....	iii
VITA.....	iv
PUBLICATIONS.....	v
TABLE OF CONTENTS.....	vi
LIST OF TABLES.....	ix
LIST OF ILLUSTRATIONS.....	x
CONTENTS OF APPENDICES.....	xii
<b>Chapter</b>	
I. INTRODUCTION.....	1
II. REVIEW OF LITERATURE.....	4
A. Morphological Techniques Used in Hepatic and Renal Lymphatic Studies.....	4
B. Renal Lymph System.....	9
1. General Pattern.....	9
2. Intrarenal Pattern.....	9
a. Cortex.....	10
b. Medulla.....	13
C. Hepatic Lymph System.....	14
1. General Pattern.....	14
2. Intrahepatic Pattern.....	15

D. Translymphatic Transport.....	19
1. Ultrastructure of the Lymphatic Capillary.....	19
2. Transport Pathways Across the Lymphatic Endothelium.....	21
a. Intercellular Channels.....	21
b. Vesicular System.....	22
c. Intraendothelial Channels.....	24
3. Formation of Lymph.....	24
III. PURPOSE OF STUDY.....	28
IV. THE RENAL CORTICAL LYMPHATIC SYSTEM IN THE RAT, HAMSTER AND RABBIT.....	31
Abstract.....	31
Introduction.....	32
Materials and Methods.....	35
Results.....	38
Discussion.....	59
V. THE PATTERN AND DISTRIBUTION OF INTRAHEPATIC LYMPH VESSELS IN THE RAT.....	65
Abstract.....	65
Introduction.....	66
Materials and Methods.....	68
Results.....	71
Discussion.....	95



VI. AN ULTRASTRUCTURAL STUDY OF TRANSPORT PATHWAYS ACROSS HEPATIC LYMPH VESSELS IN THE RAT.....	100
Abstract.....	100
Introduction.....	101
Materials and Methods.....	103
Results.....	105
Discussion.....	117
VII. DISCUSSION.....	121
VIII. SUMMARY.....	127
IX. BIBLIOGRAPHY.....	130
APPENDIX A.....	141
APPENDIX B.....	148

LIST OF TABLES

	Page
Chapter IV	
Table I: Mean size of cortical lymphatics.....	56
Table II: Density of cortical lymphatics.....	57
Table III: Urinary concentrating capacity, lymphatic volume density and profile density in four species of laboratory animals.....	61
Chapter V	
Table I: Frequency of hepatic lymph vessels.....	93
Table II: Size of vessels in hepatic portal canals.....	94
Chapter VI	
Table I: Intercellular contacts.....	115
Table II: Distribution and morphometry of endocytotic vesicles.....	116
Chapter VII	
Table I: Comparison of perfusion-fixed renal and hepatic lymph systems.....	126

## LIST OF ILLUSTRATIONS

	Page
 <b>Chapter IV</b>	
Figure 1. Light micrograph of renal intralobular and interlobular lymphatics in the rat....	41
Figure 2. Light micrograph of renal intralobular lymphatic in the hamster.....	43
Figure 3. Light micrograph of intralobular lymphatics related to tubules and blood capillaries only.....	45
Figure 4. Light micrograph of renal interlobular lymphatic in the rabbit.....	47
Figure 5. Light micrograph of renal interlobular lymphatic in the hamster.....	49
Figure 6. Electron micrograph of lymphatic intraendothelial channels in the kidney of the hamster.....	51
Figure 7. Electron micrograph of renal intralobular lymphatic in the rat and interlobular lymphatic in the rabbit.....	53
 <b>Chapter V</b>	
Figure 1. Light micrograph of hepatic portal canal..	74
Figure 2. Light micrograph of hepatic portal canal..	76
Figure 3. Electron micrograph of hepatic portal canal.....	78
Figure 4. Electron micrograph showing arrangement between hepatic lymph vessel and spaces of Mall and Disse.....	80

Figure 5.	Electron micrograph showing intimate association between collagen fibers, reticular fibers and lymphatic endothelium.....	82
Figure 6.	Electron micrograph of intercellular contacts in hepatic lymph vessels.....	84
Figure 7.	Electron micrograph showing relationship between hepatic lymph vessel, Mall's space and hepatocyte.....	88
Figure 8.	Relationship between cross-sectional area of hepatic arteriole and lymphatic vessel.....	90
Figure 9.	Relationship between cross-sectional area of bile duct and lymphatic vessel.....	92

## Chapter VI

Figure 1.	Electron micrograph of hepatic lymph vessel.....	108
Figure 2.	Electron micrograph of intercellular contacts in hepatic lymph vessels.....	110
Figure 3.	Electron micrograph of specialized junctional complexes in hepatic lymph vessels.....	112
Figure 4.	Electron micrograph of intercellular contacts with dilations in hepatic lymph vessels.....	114

CONTENTS OF APPENDICES

	Page
Appendix A Materials and Methods.....	141
I. Tissue Processing Procedures and Solutions.....	142
II. Additional Notes on Renal Drip Fixation.....	144
III. Additional Notes on Renal Perfusion Fixation.....	146
IV. Additional Notes on Hepatic Perfusion Fixation.....	147
Appendix B Data.....	148
I. Renal Lymphatics.....	149
II. Hepatic Lymphatics.....	151

## CHAPTER I

### INTRODUCTION

Two problems hinder the study of intraorgan lymphatic systems by morphological techniques. First, lymphatics are difficult to distinguish from empty blood capillaries and other thin-walled vessels by light microscopic examination of histologic sections. Often times they are collapsed, so even tissue spaces can be mistaken for lymphatics. If lymphatic vessels cannot be precisely distinguished from other vessels and tissue spaces, their extent within organs cannot be accurately determined. Electron microscopy is an effective means of identifying lymphatics, but because intraorgan lymphatics are usually sparse, ultrastructural observations alone do not reveal their full pattern and distribution. A second problem confronting lymphatic research is an inability to demonstrate the entire lymphatic network. The usual labelling techniques for study of blood vasculature are not entirely appropriate for lymphatics. For instance, resin-casting techniques which have been used to demonstrate the blood vasculature of the kidney (Evan et al., 1979; Casellas and Mimran, 1981) and liver (Kardon and Kessel, 1980; Hanstede and Gerrits, 1982) cannot be used to demonstrate lymphatic networks. Because the lymphatic system is closed at one end and protected by valves on the other, it is difficult to fill

all vessels, especially the small initial ones, with casting material. These two major technical difficulties have prevented the complete description of lymphatic systems in various organs.

In the kidney, the controversy over the existence of intralobular lymphatics has not yet been resolved. Although lymphatics have been described within the renal lobule of dogs by Nordquist et al. (1973) and Albertine and O'Morchoe (1979), others including Peirce (1944) and Kriz and Dieterich (1970) were unable to locate intralobular lymphatics. The existence of lymphatics within the lobule is central to determination of the role of tubular reabsorbate in renal lymph formation. If lymphatics begin in the interlobular connective tissue, then tubular reabsorbate must travel a longer distance to reach the initial lymphatics than plasma filtrate, the second source of fluid forming lymph. Quantitative data are also lacking on the extent of renal lymphatics of the rat. The only data presently available are on the dog (Albertine and O'Morchoe, 1979).

A similar controversy exists in the liver. Although, it is no longer believed that lymphatics originate within the hepatic lobule,\* the relationship between small lymphatic capillaries and the space of Disse is not clear. A morphological description of this relationship is important, since fluid and protein in the perisinusoidal space of Disse are regarded as a major source of hepatic lymph. However, previous

\* The term hepatic lobule, in this study, will refer to the classical lobule with branches of the portal vein, hepatic artery and bile duct at the periphery and the central vein in the center (Elias, 1963).

histological descriptions of lymphatics within the liver have been confined to larger vessels (Comparini, 1969; Schatzki, 1978). The routes of translymphatic transport, also, have not been examined in the liver, although they have been described in other organs (Casley-Smith, 1964, 1965; Leak, 1971; Yang et al., 1981; Albertine and O'Morchoe, 1980, 1981). In the liver, no quantitative morphological data on lymphatic vessels are available.

The intent of the present study was twofold. The first intent was to develop a general technique that could be used to obtain information on the lymphatic systems of different organs. As has been indicated, quantitative data on direct comparisons between the extent of lymphatics in various organs are especially lacking. The second intent was to apply this technique to the study of lymphatics in the kidney of the rat, hamster and rabbit and the liver of the rat in order to determine their pattern, distribution and extent. The results on renal and hepatic lymphatics will not only answer the questions posed earlier, but will contribute to an understanding of the mechanism of lymph formation. Knowledge of the way lymph is formed is essential to a more complete understanding of the role of the lymphatic system in tissue fluid dynamics.



## CHAPTER II

### REVIEW OF LITERATURE

#### A. Morphological Techniques Used in Hepatic and Renal Lymphatic Studies

The discovery of lymphatic vessels might not have been achieved if they had not been filled, albeit accidentally, with a substance that served as a tracer. Asellius (1627) was not looking for lymphatics when he examined the abdominal cavity of a well-fed dog. At first, he thought the mesenteric lymphatics, or bundles as he called them, were nerves. Later, when he realized the bundles were not nerves, he cut into one and observed "a fluid like milk or cream gush forth." Since that first observation, various methods have been used to make lymphatic vessels more visible in intact organs and in histological tissue sections. These techniques include stab injection of lymph-specific dyes, procedures that produce lymphatic dilation, retrograde injections of tracer material into lymphatics, examination of serial sections and drip-fixation. Although these techniques have helped to advance our knowledge of the lymphatic system, none is free of shortcomings that have led to much controversy.

Some of the early investigators in this area tried to inject various substances directly into larger lymph trunks in a retrograde direction. Among the substances used by them were air, milk and colored or uncolored water. Some of the most successful preparations were made by Nuck (1692) who injected a combination of mercury, lead and zinc into lymphatics of the kidney and sex organs. More recently, retrograde injections use India ink or ferritin as the tracer (Johnson and Blake, 1966; Leak and Burke, 1966; Casley-Smith, 1969; Norquist et al., 1973; Magari et al., 1979; Rodrigues Grande, 1983). Unfortunately, lymphatic valves protect against the backward flow of material and so high pressures must be used to permit complete filling of the vessels. This often leads to rupture of the delicate lymphatic endothelium. The spaces revealed by the subsequent leakage of dye into the interstitium can be falsely interpreted as lymphatics. Thus, great care must be taken when filling lymphatics with tracer in a retrograde direction.

In the latter part of the 1800's, it was discovered that it is not necessary to inject material directly into a lymphatic vessel but that injection into the interstitial space, so-called stab injection, may often be sufficient to label the lymphatics of most organs. This method was used by MacGillavry (1864) who examined the liver and was the first to describe the perisinusoidal space. Disse (1890), after whom this space is now named, also used stab injections. In the kidney, stab injections were used by Ludwig and Savarykin (1863) who were among the first to describe the intrarenal lymphatic system. Presently, lymph-specific dyes such as India ink or patent blue are used as tracers

and are injected into organs under pressure. The dye subsequently enters the lumen of lymphatic vessels to label their presence. The chief complaint directed towards this technique involves the high pressure required to inject tracer into the interstitial space or parenchyma. This forceful injection of tracer also causes the creation of artificial spaces that may appear to be lymphatics in tissue specimens. The dye can also enter vessels other than lymphatics. As early as 1867, Hering stated that substances injected under pressure merely demonstrate artifacts and do not enter preformed lymphatic clefts. Gloggiesser (1944) suggested that all the results from studies in the liver that have used the stab technique were significant only in so far as they demonstrated the "artificial separation of hepatic parenchyma and mesenchyma." In spite of the problems associated with the stab injection technique, its use has led to many advances in lymphology and it continues to be used by some investigators (Pissas and Papamiltiades, 1981).

In 1939, Kaiserling and Soostmeyer introduced a new technique to facilitate the detection of lymphatic vessels in histological sections. Their technique involved blocking the efferent lymph flow of the kidney which leads to dilation of the lymphatics back to their finest tributaries. This technique has since been used with success by many investigators (Huth, 1972; Szabo, 1975) and has been used with modifications by others who ligated the thoracic duct (Cremer et al., 1974; Rojo-Ortega et al., 1973), ureters (Babics, 1951), and renal collecting vessels (Holmes et al., 1977; Albertine and O'Morchoe, 1979).

The problem with this technique is that lymph blockage is not a normal physiological state and can lead to anatomical alterations. Thus, quantitative analyses of such tissues may only apply to the pathological conditions of lymphostasis.

Since the 1960's, electron microscopy has replaced light microscopy as the most reliable means of identifying lymphatics. The pioneering studies by Fraley and Weiss (1961), Casley-Smith and Florey (1961), Leak and Burke (1966, 1968) and Leak (1970) have helped to establish the ultrastructural criteria by which lymphatic vessels are identified. The chief characteristic used to distinguish lymphatics from blood vessels is the lack of a complete basal lamina in the former. However, because the specimens examined by the electron microscope are so small, the instrument is not well suited for defining the extent of lymphatics within an organ.

The examination of serial sections by light microscopy has been applied with success to define the extent of the lymphatic vasculature within organs. Peirce (1944) used the technique to examine renal lymphatics as did Comparini and Bastianini (1965) and Comparini (1969) who studied lymphatics of the liver. However, because lymphatics branch and anastomose so frequently and because they are difficult to identify by light microscopy, it is hard to follow their extent through an organ with assurance that the structure being followed is indeed a lymphatic. Electron microscopic examination of serial sections has been used to examine the ultrastructural morphology of lymphatics (Azzali, 1982a). The main complaint with serial ultrathin sections is that it is a

tedious and slow process to examine the pattern and distribution of lymphatic vessels.

Recently, a novel approach to the problem of identifying lymphatics was reported by Albertine and O'Morchoe (1979). These investigators dripped acrolein, a histological fixative, onto the surface of the dog kidney in order to preserve the luminal contents of blood vessels. Lymphatics were thus preliminarily distinguished from blood vessels by light microscopy because they lacked the formed elements of blood. Subsequent examination by electron microscopy confirmed their identity. However, the dog kidney may be unique since acrolein fixative does not appear to penetrate the kidneys of rats as deeply (Yang, personal communication) and only fixes the superficial cortex of kidneys in the hamster and rabbit (personal observation).

Immunocytochemistry is one of the newest techniques used to distinguish lymphatics from blood vessels (Barsky et al., 1983). This method uses antibodies against Type IV collagen and laminin, two components of basement membrane, to label blood capillaries. Although, this technique may be useful in identifying the blood vasculature, since the lymphatics themselves are not stained, this technique is not as desirable as one that labels lymphatic vessels directly.

## B. Renal Lymph System

### 1. General Pattern

Lymph from the kidney is drained by a superficial or capsular network and a deeper or hilar network (Rusznayak et al., 1967, Yoffey and Courtice, 1970). The capsular network runs across the surface of the kidney in the connective tissue capsule and converges to form three to four collecting vessels, that leave the kidney at the renal poles and course toward the renal pedicles. The collecting vessels of the capsular network empty into para-aortic nodes that eventually connect with the thoracic duct. The hilar network drains the deep parenchyma of the kidney and is distributed within the organ in association with the larger blood vessels. At the hilum, tributaries of the hilar system merge to form 3 to 14 collecting vessels that leave the kidney beside the renal artery and vein (Parker, 1935). The collecting vessels of the hilar system also empty into para-aortic nodes. Communications between the capsular and hilar system have been reported in the dog (Bell et al., 1968; Cockett et al., 1970; Kriz and Dieterich, 1970; Nordquist et al., 1973) although they probably only function when intrarenal lymph is diverted from one system to the other (Holmes et al., 1977).

### 2. Intrarenal Pattern

Agreement concerning the distribution of the larger renal lymphatics has existed almost since the time of their discovery by Mascagni (1787). Thus, the presence of lymphatics associated with

interlobular, arcuate and interlobar blood vessels has not been a matter of debate. What has caused considerable controversy is the question of whether or not lymphatics are present within the renal lobule and medulla.

#### a. Cortex

Using the stab injection method, Peirce (1944) completed a rigorous study of the renal lymphatics of the dog, rabbit and guinea-pig using serial sections and light microscopy. He demonstrated that lymphatics accompany the interlobular, arcuate and interlobar blood vessels, but he was unable to find tributaries to these vessels from the renal lobule. Although Peirce (1944) found occasional lymphatics close to renal corpuscles, direct connections with Bowman's capsule were never found. This study also demonstrated the difficulties with the stab injection technique. Out of 15 injection attempts, only one fulfilled the stringent criteria established by Peirce (1944) for completely successful stab injection preparations. Perhaps because of his careful approach, he may have overlooked smaller lymphatic capillaries draining the lobules.

Bell et al. (1968) used retrograde injection of contrast medium directly into capsular or hilar vessels. The photographs published by this group showed cleared kidney slices with ink in the lymphatics. The results of this study largely confirmed the results of Peirce (1944), i.e. that lymphatics are primarily distributed within the interlobular spaces and along arcuate blood vessels. Although, Bell and co-workers

(1968) concluded that lymphatics within the lobule were sparse, they did not clearly state whether intralobular vessels, as such, exist.

Using a similar technique, Cockett et al. (1970) injected vinyl-acetate into capsular lymphatics of dogs. Although the existence of intralobular vessels was not discussed, the study showed that interlobular and arcuate tributaries of the hilar system had been filled. Cockett and co-workers (1970) concluded from this evidence that connections between the hilar and capsular system existed. However, as with the report by Bell et al. (1968), it is not possible to determine from the published photographs whether the injected material filled only lymphatics or whether other vessels and tissue spaces were also filled.

In 1970, Kriz and Dieterich performed a light and electron microscopic study on a number of species, including the dog and rat. This study was performed on perfusion-fixed kidneys in the absence of manipulations to emphasize the lymphatics. The results of this study reinforced previous views that the intrarenal lymphatics followed the major blood vessels. Lymphatics were seen in association with renal corpuscles, but the authors concluded that these vessels were not within the renal lobule and were only passing renal corpuscles that happened to be close to the interlobular connective tissue.

Ohkuma (1973) utilized electron microscopy to examine the renal cortex after stab injection with ink. Although his micrographs clearly demonstrated lymphatics within the cortex and some in close relationship to nephric elements, it was not clear whether these vessels were intralobular or interlobular. This study was performed on random



samples from the cortex and no attempt was made to follow the course of identified lymphatics.

The studies by Nordquist et al. (1973, 1974) extended the work begun by Bell et al. (1968) to the ultrastructural level. This group used retrograde injection of ink into the capsular lymphatics of the canine kidney in order to increase the visibility of the intrarenal vessels. Their results supported the existence of a lymphatic network within the renal lobule and which apparently forms tributaries to vessels coursing with interlobular arteries and veins.

Rojo-Ortega et al. (1973) examined cortical lymphatics of the rat by electron microscopy after ligation of the thoracic duct. These investigators described lymphatic vessels in the vicinity of the vascular pole of the glomerulus and in the interlobular vascular areas. Although they suggested that the juxtaglomerular lymphatics were connected to lymphatics which run along the course of the afferent arteriole and interlobular vessels, they failed to identify these vessels as intralobular. This group also indicated they were unable to demonstrate an intertubular lymphatic network.

The most recent studies on the distribution of the intrarenal lymphatics were performed by Albertine and O'Morchoe (1979) who demonstrated renal cortical lymphatics by light and electron microscopy in two groups of dogs. One group of animals had previous ureteric obstruction and the other did not. The renal collecting lymphatic vessels were ligated in both groups for four to six hours to dilate the smaller vessels and make them more easily detectable in tissue section.

In this way, intralobular lymphatics associated with terminal arteries, arterioles, renal corpuscles and tubular elements would be demonstrated. This study was followed by another that examined the same vessels in dogs having unimpeded lymph and urine flow to simulate more physiological conditions (O'Morchoe and Albertine, 1980). This latter study corroborated results of their initial investigation. These two studies were also the first to apply quantitative analyses to the study of renal lymphatics. Their findings indicated that in dogs with unimpeded lymph and urine flow, lymphatics occupy approximately 0.14% of the renal volume. They also showed that interlobular lymphatics had a mean cross-sectional area ( $305 \mu\text{m}^2$ ) twice that of intralobular vessels ( $155 \mu\text{m}^2$ ).

#### b. Medulla

Renal medullary lymphatics have been reported by a number of investigators. These studies have involved pathological specimens (Rawson, 1949; Rhodin, 1965) or stab injections of tracer under pressure into the subcapsular space (Cockett et al., 1970) and into the renal pelvis (Cuttino, 1982). However, other studies also using stab injection (Peirce, 1944; McIntosh and Morris, 1971) and retrograde injection of tracer into lymphatics (Bell et al., 1968) have failed to find medullary lymphatics. An electron microscopic study by Kriz and Dieterich (1970) similarly failed to demonstrate medullary lymphatics. A detailed and systematic search for medullary vessels was conducted by Albertine and O'Morchoe (1980a) who utilized two approaches. The first

was to look for lymphatics in the medulla by electron microscopy. Of 90 blocks examined, only one instance of three lymphatics located high in the outer medulla was found. These vessels were considered part of the arcuate system. The second approach was to follow arcuate lymphatics in serial sections to look for medullary tributaries. Examination of 60 blocks which contained arcuate lymphatics failed to reveal any medullary components. Results of this study indicate medullary lymphatics do not exist, at least in the dog.

### C. Hepatic Lymph System

#### 1. General Pattern

Three networks of lymphatics are described in the liver (Comparini, 1969). The first system consists of vessels which course mainly in the interlobular connective tissue and form a complex network in relation to the interlobular arteries, veins and biliary ducts. This network converges to form lymphatic collecting vessels that leave the liver through the porta hepatis in relationship with the portal vein, hepatic artery and bile duct. These vessels drain into hepatic nodes (Yoffey and Courtice, 1970). Lee (1984) observed that the portal system is drained by one or two hepatic lymph ducts in rats. Lymph from this system ultimately empties into the thoracic duct.

The second system of lymphatic vessels follows larger tributaries of the hepatic vein and is more sparse than the portal system. The collecting vessels of this system ascend with the hepatic vein and drain

into the intrathoracic nodes around the inferior vena cava (Yoffey and Courtice, 1970). Efferent vessels of these nodes eventually join the right lymph duct. According to Ritchie et al., (1959) approximately 80% of hepatic lymph in the dog is drained by the portal system while 20% is drained by lymphatics related to the hepatic veins.

The third system is present in the fibrous capsule of the liver and drains into both the right lymph duct and the thoracic duct. Although anastomoses between the capsular and intrahepatic lymph vessels have been reported by Comparini (1969), these connections may have little functional importance. Szabo (1975) studied the lymphatic drainage of labelled protein placed in the hepatic parenchyma. After occlusion of about 70% of the hilar lymphatics, he found that the increase in the transport of labelled protein by the right lymph duct accounted for only a small fraction of the loss from the thoracic duct lymph. He concluded that lymph formed in the hepatic parenchyma is transported by vessels joining the thoracic duct and is apparently not drained by vessels that ultimately join the right lymph duct. Thus, functional division of the superficial and deep lymphatics of the liver appears to exist.

## 2. Intrahepatic Pattern

Like the controversy concerning renal lymphatics, the existence of hepatic lymph vessels within the parenchyma has been debated since before the turn of the century. Even the development of electron microscopy has not made completely clear the origin of the lymphatics in

the liver. Early studies on this problem centered on research involving the nature of the perisinusoidal space. While only Kisselew (1869) and Reinke (1887) believed the space was lined by an endothelium, many including Disse (1890) regarded it as part of the lymphatic system. Disse (1890) claimed the existence of pericapillary (perisinusoidal) cavities with walls composed of fibers and cells of the connective tissue. He believed that these cavities provided an anatomical connection between perisinusoidal spaces and true lymphatics located at the periphery of the hepatic lobules. Thus, Disse (1890) proposed that these channels formed a prescribed pathway for the formation of lymph. While Disse's anatomical description of lymphatic cavities within the hepatic parenchyma has never been substantiated, his concept of the perisinusoidal space as the source of fluid that forms hepatic lymph, still receives support.

In 1923, Lee ligated the thoracic ducts of cats and was able to demonstrate the lymphatics of the liver after careful injection of Berlin blue into mesenteric lymphatics. He confirmed a connection between portal lymphatics and vessels accompanying the hepatic veins. However, Lee (1923) was unable to trace lymphatics into the hepatic lobule and believed that an anatomical connection between the perisinusoidal space and lymphatic vessels did not exist.

A portion of the study by Elias (1949a,b), devoted to the structure of the liver, included examination of hepatic lymph vessels. Utilizing stab injections of ink, Elias described the vessels as forming a network within the interlobular spaces and sending occasional branches

into the interior of the lobule. These intralobular lymph vessels, as he called them, accompanied the intralobular arterioles and ductules. Although Elias (1949a) used serial sections to examine the parenchymal structure, he apparently did not follow lymphatics in the same sequential manner. This study remains as the only recent study to describe lymphatics within the hepatic lobule.

The most complete description of the hepatic lymph system was reported by Comparini (1969) who examined serial sections of human liver by light microscopy. This work established the concept of three hepatic networks of lymphatic vessels. Comparini (1969) was unable to demonstrate lymphatic vessels in the hepatic parenchyma and concluded that portal lymphatics start in the areolar tissue of the portal canals. He thus refuted Elias' (1949b, 1963) earlier description. However, assessment of this study must take into account a previous report by Comparini and Bastianini (1965). This earlier study described the attempt to make three-dimensional reconstructions of hepatic vessels based on light microscopic examination of serial sections. The diagrams published in this study depict a hepatic lymph system much more extensive than any shown before or since. These investigators may have mistaken tissue spaces or other vessels for lymphatics. Whether Comparini (1969) used the same criteria in his later study to identify lymphatics is not known.

Experimental lymph stasis induced by occlusion of the hilar lymph vessels and bile ducts was used by Huth et al. (1972) to demonstrate the hepatic system. This group found no lymphatic tributaries from the

parenchyma but did find separation of the lymphatic endothelial junctions, enlargement of the space of Disse and clefts next to the central veins. They also concluded that no permanent pathological change was produced by lymphostasis alone and apparent regeneration of the lymphatics occurred after two weeks.

The ultrastructural morphology of lymphatics in the hepatic interlobular connective tissue of rabbits was examined by Fujikawa and Magari (1975). Their description of these vessels is similar to that of lymphatics found elsewhere in the body (see next section). Notably, areas of thin and thick endothelium, numerous pinocytotic vesicles and caveolae were observed. But unlike other reports, this group observed large ( $1300 \text{ \AA}$  in diameter) coated vesicles arranged in a bead-like manner within the endothelial cell.

Schatzki (1975) also used electron microscopy to examine lymphatics of the porta hepatis at the junction with the hepatic parenchyma of rats. He found that the vessels were similar to those seen by Fujikawa and Magari (1975). Additionally, Schatzki observed that the endothelial cells were bound together by maculae adherentes and zonulae occludentes. He did not find communications between lymphatics and the spaces of Mall and Disse and concluded that lymphatics were present only in collagenized portal areas.

Cremer (1974) ligated the thoracic duct of rats and examined the hepatic lymph vessels located in the portal tracts and along the hepatic veins. Like other investigators, he did not find lymphatics in the parenchyma but observed dilation of the spaces of Disse and Mall.

Cremer (1974) found that fluid in the bile ducts and in surrounding lymphatics had the same color, which he claimed was indicative of lymphobiliary fistulae. However, he did not further describe the nature of this possible connection between bile ducts and lymphatics.

#### D. Translymphatic Transport

##### 1. Ultrastructure of the Lymphatic Capillary

Early ultrastructural reports described lymphatics as being very similar to blood vessels except that lymphatics had a more irregular shape and a poorly developed basal lamina (Palay and Karlin, 1959; Casley-Smith and Florey, 1961; Fraley and Weiss, 1962). With improved fixation and staining techniques, a clearer description of lymphatic ultrastructural morphology has emerged from studies on vessels of the diaphragm (Casley-Smith, 1964; Leak and Rahil, 1978), dermis (Cliff and Nichol, 1970; Leak, 1970), lung (Lauweryns and Boussauw, 1969; Leak and Januar, 1983), heart (Leak et al., 1971; Bullon and Huth, 1972), testis (Fawcett et al., 1973), intestines (Dobbins and Rollins, 1970; Collan and Kalima, 1974), kidney (Albertine and O'Morchoe, 1980a), liver (Schatzki, 1978), and skeletal muscle (Skalak et al., 1984).

The lymphatic capillary is composed of a non-fenestrated endothelial cell lining that lacks a continuous basal lamina. This endothelium is extremely thin over large portions of its circumference, but thicker in the region where the nucleus is located. The thin region measures 50 to 100 nm while the thicker areas may measure up to 3  $\mu\text{m}$ .



Cytoplasmic projections that extend into the lumen or interstitium may be present. Plasmalemmal invaginations or caveolae are a prominent feature of the luminal and abluminal surface of lymphatic capillaries. Uncoated vesicles are found in association with the caveolae and deeper within the cytoplasm. Also within the cytoplasm, common cellular organelles are found. The rough endoplasmic reticulum is sparse and is randomly dispersed throughout the cell. Ribosomes occur as single units and as polyribosomes. The mitochondria, which are oval and elongated, are concentrated near the nucleus but also can be found scattered throughout the cytoplasm. A small Golgi and a pair of centrioles are also located in the cytocentrum.

One of the unique features of lymphatic vessels is the presence of anchoring filaments. The intimate association between extracellular components and the lymphatic wall was first described by Pullinger and Florey (1935), who observed collagen and reticulum fibers in close proximity to the lymphatic endothelium. Casley-Smith and Florey (1961), with the aid of electron microscopy, found that lymphatics were indeed surrounded by collagen and finer fibers but were not able to demonstrate the close relationship between the fibers and the endothelium suggested by Pullinger and Florey (1935). Later, with improved electron microscopic techniques, Leak and Burke (1965, 1966, 1968) and Burke and Leak (1970) demonstrated that fine filaments insert within a densely staining substance on the abluminal surface of lymphatic vessels and extend for various distances into the surrounding interstitium between collagen bundles and connective tissue cells. These filaments, ranging

from 6 to 10 nm in diameter, are thought to provide a structural basis for maintaining a connection between the lymphatic endothelium and the surrounding connective tissue (Leak and Burke, 1968). The presence of anchoring filaments and the absence of a complete basal lamina are the most common criteria by which morphologists distinguish lymphatics from blood capillaries (Leak, 1980; O'Morchoe, 1984).

## 2. Transport Pathways Across the Lymphatic Endothelium

The routes by which fluid and macromolecules enter the lymphatic lumen have been extensively studied (Casley-Smith, 1964, 1965; Leak, 1971; Albertine and O'Morchoe, 1980a; Yang et al., 1981; O'Morchoe et al., 1984). According to these studies the principal pathways are between adjacent endothelial cells and within endocytotic vesicles. Azzali (1982a,b,c) has recently suggested that lipid may enter intestinal vessels by a unique specialization of the lymphatic wall.

### a. Intercellular Channels

The contact between adjacent endothelial cells varies in complexity from simple abutment to intricate interdigitations. In lymphatics of the canine kidney, these intercellular contacts have been classified according to their ultrastructural appearance by Albertine and O'Morchoe (1980a). Three types have been described and listed from simplest to most complex, these are: 1) end-to-end; 2) overlapping; and 3) interdigitating. The usual space between cells is about 15 - 20 nm wide, although wider gaps reaching several micrometers have been

observed in diaphragmatic vessels (Casley-Smith, 1964). These wider clefts are known as open intercellular junctions and have been implicated in the formation of lymph (see Formation of Lymph). According to many investigators, the open junction represents a patent cleft that permits large molecules and particulate substances to enter the lymphatic lumen. However, the existence and significance of this type of intercellular contact in the kidney is considered to be minor (Albertine and O'Morchoe, 1980a; Yang et al., 1981).

#### b. Vesicular System

The plasmalemmal invaginations found on both luminal and abluminal surfaces of the endothelium range in size from small depressions to almost complete vesicles. These caveolae are thought to give rise to membrane-bound vesicles (70 - 100 nm in diameter) found deeper in the cytoplasm. Presumably, the caveolae round up, become completely enclosed and detach from the cell surface to form vesicles. The transport of substances by endocytotic (plasmalemmal, cytoplasmic, micropinocytotic, endothelial) vesicles was first proposed by Palade (1953, 1961) in blood capillaries. He considered that the vesicles were in a constant state of motion, shuttling fluid and solutes across the endothelium "like diffusion in quanta." Studies by Casley-Smith (1964), Dobbins and Rollins (1970), Leak (1972), Yang et al. (1981), Jones et al. (1983), O'Morchoe et al. (1984) indicate vesicles may perform a similar function in lymphatic vessels. However, other studies on blood and lymphatic capillaries suggest that the vesicles may not be discrete

entities but part of a more complex structure that retains connections to the cell surface. Palade et al. (1979) has suggested that the vesicles not only transport material as discrete structures but may fuse and create patent channels from one side of the endothelium to the other side. The existence of trans-endothelial channels has been disputed by others. Bundgaard and co-workers (1983) examined frog mesenteric and rat heart blood capillaries by three-dimensional reconstruction based on ultrathin serial sections and concluded that all vesicular profiles were parts of the surface membrane either as simple caveolae or as part of a more complex system of invaginations. The study by Jones et al. (1983) on lymphatic endothelium indicates most (80% - 90%) of the vesicles that appear to be free in the cytoplasm in electron micrographs actually have a connection to the surface. On the other hand, fusion of individual vesicles is considered to be an artifact of chemical fixation (Wagner and Casley-Smith, 1981). Wagner and Robinson (1984) examined the endothelial vesicles of blood capillaries by high-voltage electron microscopy and concluded that not all vesicles are conjoined nor maintain connections with the cell surface. These authors claim that a dynamic interaction between simple and compound vesicular forms exists, where discrete vesicles apparently fuse and refuse with more complex structures. Thus, the vesicular system as depicted by high-voltage electron microscopy provides, at least in blood capillaries, a discontinuous pathway across the endothelial cell.

### c. Intraendothelial Channels

Studies by Azzali (1982a,b) have demonstrated a possible new mechanism of transport for lipid in lymphatics of the intestinal villus. Azzali observed that lipid droplets passed into lacteals of milk-fed kittens and bats by way of large intraendothelial channels. The luminal surface of the structure is formed by the normal lymphatic wall and the abluminal surface by cytoplasmic processes of the endothelial cells. The entire canalicular structure is held together by junctional complexes. The channels which were found to be 0.19 - 0.30  $\mu\text{m}$  wide and 8 - 14  $\mu\text{m}$  long, were oriented parallel to the long axis of the lacteal. The opening to the interstitium is directed toward the apical end of the villus. Azzali (1982b) found similar, but fewer structures in starved animals. Lymphatics of the small intestine submucosal and serosal-muscular layers also had these openings (Azzali, 1982c).

### 3. Formation of Lymph

At the present time, three principal theories of lymph formation exist. According to the first theory (Leak, 1972; Guyton and Barber, 1980), hydrostatic pressure is responsible for the flow of fluids into lymphatics. This theory is based upon the periodic compression of lymphatic vessels by the action of surrounding tissues or the pulsation of adjacent arterioles (Intaglietta and Gross, 1982; Skalak et al., 1984). Upon the release of compression, the anchoring filaments which connect the lymphatic wall to the surrounding interstitium pull the vessel open. This action has two effects. The first is to lower the

intraluminal pressure below that of the interstitium and the second is to increase the distance between adjacent endothelial cells. The combination of greater hydrostatic pressures outside the lymphatic and open intercellular junctions causes fluid and macromolecules to move into the lumen. However, evidence that the intralymphatic pressure falls below that of the interstitium is lacking. Zweifach and Prather (1975) measured the pressure within mesenteric lymphatics and found that they were atmospheric. On the other hand, studies by Guyton (1963) and Guyton et al. (1971) indicate interstitial pressures are subatmospheric (-6 mm Hg) and are, thus, apparently lower than intralymphatic pressures.

The second theory, advanced by Casley-Smith (1977) is similar to the first because it too is based on cyclic compression of the lymphatics and changes in the opening between endothelial cells. However, according to Casley-Smith (1977) the driving force behind the formation of lymph is oncotic pressure created by protein concentration differences inside and outside the lymphatic rather than hydrostatic pressure. This theory maintains that protein enters the lymphatic lumen by way of open intercellular junctions. Upon compression of the vessel the open intercellular junctions are closed and lymph is forced along the lymphatic or back into the interstitium. Because the closed junctions permit only the passage of solvent and not protein, the latter are concentrated within the lymphatic. When the compression is released and the intercellular junctions are once more open, fluid is drawn into the vessel by oncotic pressure. This theory has not attracted much

support and there is some evidence against it. Rutili and Arfors (1977) were unable to find protein concentration differences between interstitial fluid and lymph. Nicolaysen et al. (1975) did not find lymph protein concentration differences between different lymphatics, although the cyclic nature of this theory would suggest that differences should exist. Michel (1974) has questioned whether oncotic forces could be maintained across open intercellular junctions.

The third theory proposes that the vesicular system provides a major pathway across lymphatic endothelium (Dobbins and Rollins, 1970; Albertine and O'Morchoe, 1980a, 1981; Yang et al., 1981; Jones et al., 1983; O'Morchoe et al., 1984). According to this theory, fluid and macromolecules, especially protein, are transported across the endothelium by vesicles which may be discrete or fused to form trans-endothelial channels. The evidence for this theory is that tracers like horseradish peroxidase and ferritin, when applied to the abluminal surface of lymphatics, are readily taken up by caveolae and vesicles. This tracer subsequently appears in vesicles distributed throughout the cytoplasm and eventually within the lymphatic lumen. Vesicular transport is a passive process, that appears to require no metabolically derived energy (Williams et al., 1979). O'Morchoe et al. (1984) demonstrated that the transport of protein across lymphatic endothelium is temperature dependent, which suggests a cytoplasmic process of lymph formation. These results were interpreted by O'Morchoe et al. (1984) as providing support for the vesicular theory of lymph formation. However, only minor significance is attached to the

transport of protein by cytoplasmic vesicles by proponents of the other two theories (Leak, 1984; Casley-Smith, 1964).



## CHAPTER III

### PURPOSE OF STUDY

The kidney and liver are relatively unusual organs in that they are enclosed by a tight connective tissue capsule and have a tissue hydrostatic pressure that is believed to be positive. In other regions of the body, e.g. dermis, tissue hydrostatic pressure is normally subatmospheric (Guyton et al., 1971). However, during trauma or in states of edema, the hydrostatic pressure may increase above atmospheric. Under these conditions lymph is formed by the movement of interstitial fluid and macromolecules through open junctions between lymphatic endothelial cells. Open junctions, however, are rarely seen in renal lymphatics and, thus, lymph is most likely to be formed by a different route in the kidney (Albertine and O'Morchoe, 1980a, 1981; Yang et al., 1981). Casley-Smith (1982) has proposed that the mechanism of lymph formation in the kidney and possibly the liver is different from that found in tissues where the hydrostatic pressure is subatmospheric.

The general purpose of the present study was to obtain a detailed morphological description of the lymphatics of the kidney and liver in order to determine whether or not the mechanism of lymph formation in these organs is similar from a structural point of view. Central to the

issue of the way lymph is formed is to determine the source of fluid that contributes to lymph formation and the rate at which lymph is formed.

A. The specific aims of the study of the kidney were:

1) To examine the structure, pattern and distribution of lymphatics in the renal cortex of the rat, hamster and rabbit. Particular attention was paid to the existence of lymphatics within the lobules and their relationship to nephric elements. This purpose was related to the question of whether renal lymph is formed from tubular reabsorbate as well as plasma filtrate and to determine whether species differences exist.

2) To determine the size and extent of lymphatics within the renal cortex of the rat, hamster and rabbit. Cross-sectional area, maximum diameter, volume density and profile density were measured. This purpose was to determine whether species differences exist and to calculate the rate of renal lymph formation in rats.

B. The specific aims of the study of the liver were:

1) To examine the structure, pattern and distribution of lymphatics in the rat liver. The relationship between the spaces of Disse and Mall and the initial lymphatic capillaries in the rat liver

was closely examined. This purpose was directed at the question of whether the fluid in the space of Disse is the major source of hepatic lymph.

2) To determine the size and density of lymphatics within the rat liver. The same parameters measured in lymphatics of the kidney were measured in the liver. This purpose was to calculate the rate of hepatic lymph formation and to compare the lymphatic system in the liver with that in the kidney.

3) To examine and quantify the potential morphologic transport routes for fluid and macromolecules across hepatic lymph vessels. The pathways (vesicles, normal intercellular channels and open gaps) that have been described in other lymphatics were quantified. This purpose was directed at the question of whether the transport pathways across hepatic vessels are like those of renal lymphatics.

## CHAPTER IV

### THE RENAL CORTICAL LYMPHATIC SYSTEM

#### IN THE RAT, HAMSTER AND RABBIT

##### Abstract

Rat, hamster and rabbit renal cortical lymphatics were examined by light and electron microscopy. Cross-sectional area, maximum diameter, volume density and profile density were determined by stereological measurements using a computer-based image analyzer. These data were used to calculate the rate of lymph formation in lymphatics of the rat renal cortex. Rat and hamster kidneys possessed both intra- and interlobular lymphatics that were structurally similar. Ultrastructural examination of the hamster lymphatic endothelium, however, revealed an unusual arrangement of cytoplasmic extensions not seen in the other two species. The intralobular lymphatics were related primarily to tubules, afferent arterioles and renal corpuscles and were consistent with lymph formation from plasma filtrate and tubular reabsorbate. Interlobular lymphatics were seen in connective tissue associated with the interlobular blood vessels. Rabbit cortex contained only interlobular lymphatics. Among kidneys fixed by retrograde perfusion the cortical lymphatic system was most extensive, both in maximum diameter, volume

density and profile density, in the hamster. It was smallest in the rabbit, and intermediate in the rat. Lower volume and profile density were found for rat kidneys fixed by the dripping technique. It was concluded that: 1) tubular reabsorbate may contribute to renal lymph in the rat and hamster but not in the rabbit; 2) significant differences exist between the renal lymphatic systems of the three species with the hamster kidney having the richest network and the rabbit the poorest; 3) the method of fixation influenced the measured size and density of renal cortical lymphatics; and 4) the rate of lymph formation in the kidney of the rat is comparable to that in the dog (O'Morchoe et al., 1982).

### Introduction

Several questions on the role of the lymphatic system in renal function have yet to be answered. One is the relative extent to which plasma filtrate and tubular reabsorbate contribute to renal lymph. A morphological approach to the problem is to examine the inter-relationships between lymphatics and other structures in the kidney: such an approach is reported here.

Studies on the pattern and distribution of the larger intrarenal lymphatics of the mammalian kidney are mainly in agreement (Peirce, 1944, Bell et al., 1968, Kriz and Dieterich, 1970, Albertine and O'Morchoe, 1979, O'Morchoe, 1984). In general these lymph vessels accompany the blood vasculature. Thus, the pattern of interlobular, arcuate, and interlobar lymphatics parallels the system of blood vessels

in the kidney. The existence of lymphatics within the lobule has been more controversial. They have been described in the dog by Nordquist et al. (1973) and later by Albertine and O'Morchoe (1979) and O'Morchoe and Albertine (1980) in more comprehensive studies. These lymphatics, termed intralobular by the latter authors, are described as tributaries of interlobular lymphatics that lie scattered among the small blood vessels and tubules and around the periphery of renal corpuscles. Their importance stems from the intimate relationship they have with parts of the nephron and thence the likelihood that the lymph formed in them contains tubular reabsorbate. Previous work on the rat kidney leaves in doubt the existence of intralobular lymphatics in that species. Kriz and Dieterich (1970) did not find lymphatics in the vicinity of afferent arterioles, the juxtaglomerular apparatus or tubules and thus concluded intralobular lymphatics did not exist. Ohkuma (1973) examined cortical lymphatics in a random fashion but did not distinguish intralobular lymphatics as such. Rojo-Ortega et al. (1973) found occasional lymphatics lying adjacent to afferent arterioles and glomeruli but did not determine whether these were parts of interlobular or intralobular lymphatics. Thus, the debate concerning the existence of lymphatics within the rat renal lobule remains unsettled.

Data on the extent of the intrarenal lymphatic system is also deficient. To date quantitative estimates of the system have been confined to the dog. They indicate that the lymphatic system comprises approximately 0.14% of the renal volume which is roughly equivalent to 1% of the volume of blood in the cortical peritubular capillaries

(Albertine and O'Morchoe, 1979; O'Morchoe and Albertine, 1980a). The rate of lymph formation in the canine kidney is approximately 1  $\mu\text{l}/\text{min}/\text{cm}^2$  of lymphatic endothelium (O'Morchoe et al., 1982).

The intent of the present study was to examine the cortical lymphatic system of the rat, hamster, and rabbit in order to address two main questions. First, what is the pattern and distribution of the initial renal lymphatics in these three species - do they or do they not commence within the lobules? This purpose was concerned with whether or not a component of tubular reabsorbate contributes to renal lymph. Second, what is the size and quantity of the intrarenal lymphatic vessels? This purpose was to derive data that could be used to calculate the rate of lymph formation. The present study was originally confined to the rat but was extended to include the hamster and rabbit because these three species are not only common laboratory animals used in renal function studies but they also have markedly different capacities to concentrate urine (Schmit-Nielsen and O'Dell, 1961; Munkacsı and Pallovits, 1977). The approach used was a qualitative and quantitative morphological method recently developed in our laboratory (Niro et al., 1982). Previous efforts to find renal lymphatics and examine their distribution have been hindered by the difficulty in distinguishing lymphatics from blood capillaries in light microscopic tissue sections (Rusznyak et al., 1967). Our approach utilizes the most useful features of light and electron microscopy to allow a comprehensive search for renal lymphatics in serial sections.

## Materials and Methods

### Qualitative study

Nine adult male Sprague-Dawley rats (Harlan) weighing 215 - 300 g (mean wt. = 247 g), two adult female New Zealand white rabbits and two adult female Syrian golden hamsters were anesthetized by intraperitoneal injection of sodium pentobarbital (Nembutal; Abbott Labs: 50 ml/kg body wt.). Both kidneys from six rats were prepared for light and electron microscopic examination by dripping 8% acrolein in .15M cacodylate buffer onto the ventral surface of the organs. This fixation technique was chosen in order to preserve the luminal contents of blood vessels and thereby facilitate the light microscopic identification of the more pale-staining lumens of lymphatic vessels. After the initial drip-fixation, the renal pedicles were tied and the kidneys removed and immersed in fresh acrolein for four hours. Both kidneys of rabbits, hamsters and three rats were fixed by retrograde vascular perfusion through the abdominal aorta with 4% glutaraldehyde also in cacodylate buffer. In this technique, 0.9% saline was perfused for one minute followed by fixative for ten minutes. A total of 25-50 ml of saline and 250-500 ml of glutaraldehyde were used in each animal. The perfusion pressure was 120 mm Hg. The rat kidneys were fixed in this manner to compare the effects of the two fixation techniques, i.e. vascular perfusion versus drip-fixation on the size and extent of lymphatic vessels. Hamster and rabbit kidneys were prepared by perfusion fixation because in pilot studies they were not adequately fixed by the drip



technique. After the initial fixation by perfusion or dripping, all kidneys were handled in the same manner.

Small blocks (1.5mm X 1.5mm) of tissue from various parts of each kidney were cut out and further fixed overnight in 4% glutaraldehyde. The next day, the blocks were post-fixed in 1% OsO<sub>4</sub>, dehydrated in a graded series of acetone and embedded in a mixture of Poly/Bed 812 and Araldite 502 (Poly/Bed 812, Polysciences, Inc was substituted for Epon 812 in Mollenhauer's formula for Epon/Araldite, Mollenhauer, 1964). The tissue blocks were embedded so that when cut, sections were obtained tangential to the surface of the kidney. Thick (3- $\mu$ m) serial sections were cut with glass knives and alternate sections were saved for light and electron microscopy on separate glass slides. Thick sections were stained with toluidine blue. Those sections saved for light microscopy were cover-slipped and examined for vessels that looked like lymphatics. These vessels were subsequently examined for positive identification in the adjacent section located on the uncovered slide reserved for electron microscopy. To achieve this, an inverted BEEM capsule containing unpolymerized embedding medium was placed over the uncovered adjacent section. The medium was then polymerized in place so that the BEEM capsule when removed contained the reembedded section. These reembedded sections were then trimmed and sectioned by routine methods for examination on a Siemens 1A or Hitachi H600 electron microscope. In this way, the lymphatic in question was either rejected or confirmed by standard ultrastructural criteria - principally by the absence of endothelial fenestrations and the lack of a continuous basal lamina.

Quantitative study

Lymphatics positively identified by electron microscopy were then reexamined by light microscopy in the serial sections cut from the original block. The vessels were followed in both directions. Some lymphatics in the rat kidney were followed through more than 200 alternate thick (3  $\mu\text{m}$ ) sections for a distance of about 1.2 mm which represents about 85% of the rat cortical thickness (W.R. Jones, personal communication). When the lymphatic vessel and its relationships were examined over many sections, a determination of its type (intralobular versus interlobular) could be made. Lymphatics associated with afferent arterioles, related to the periphery of Bowman's capsule or lying among the tubules were considered to be of the intralobular variety. Interlobular lymphatics could readily be recognized by their proximity to interlobular arteries and veins. Each lymphatic was measured in every section in which it could be seen using a microscope fitted with a drawing tube, which was positioned over the digitizing tablet of a Zeiss Videoplan image analyzer. The maximum diameter and cross-sectional area were automatically determined by the image analyzer for each lymphatic vessel.

For determination of the lymphatic volume density ( $V_V$ ) and profile density ( $N_A$ ), four blocks were systematically chosen from each kidney. Thin-sections were cut from the blocks and mounted on formvar-coated, one-hole grids. The thin-sections were then examined by electron microscopy and every lymphatic was photographed at a fixed magnification. Micrographs of the lymphatics were then measured with

the image analyzer to obtain cross-sectional areas. The area of the thin-section was also measured on the image analyzer. The total cross-sectional area of all lymphatics in a thin-section when divided by the total area of the thin-section gave an estimate of the areal density which is directly related to the volume density ( $A_A = V_V$ , Weibel, 1973). The profile density of lymphatics was estimated by dividing the number of lymphatics in a thin-section by the area of the thin-section. Statistical significance of maximum diameter and cross-sectional area between interlobular and intralobular lymphatics were determined by the Student's t-test. The volume density and profile density were analyzed by the one-way analysis of variance and significance was determined by the least significant differences (Steel and Torrie, 1960).

### Results

#### Qualitative

A total of 77 lymphatics in 18 kidneys from nine rats, 24 lymphatics in four kidneys from two rabbits and 83 lymphatics in four kidneys from two hamsters were examined in this study. The larger cortical lymphatics of the three species followed a pattern and distribution similar to that described by earlier investigators for several mammalian species including the rat, dog and human. Interlobular lymphatics were seen in a paravascular position, typically dividing and rejoining several times before forming arcuate lymphatics. No valves were observed in interlobular lymphatics of any of the three

species examined. The arcuate lymphatics also followed the course of arcuate blood vessels to form the interlobar lymphatics.

Several new findings were seen in the present study. First, intralobular lymphatics were observed in the rat and hamster. These tributaries of the interlobular lymphatics were primarily associated with the afferent arteriolar branches of the interlobular arteries (Figs. 1 and 2). Thus, lymphatics were found beside occasional afferent arterioles and could be traced back toward the renal corpuscles. Lymphatics in the hamster and rat were also found amongst tubules and peritubular capillaries deep within the renal lobules and unrelated to arteries or veins (Fig. 3). A striking finding was that intralobular lymphatics were never seen in the rabbit kidneys.

Second, interlobular lymphatics of the hamster were more obvious and were grouped together in greater numbers than in the rat or rabbit. These interlobular vessels were usually found one or two at a time in the rat and rabbit (Figs. 1 and 4) while in the hamster, groups of three to five vessels were commonly seen around the interlobular vasculature (Fig. 5). The interlobular lymphatics in the hamster also appeared to branch more frequently and thus had a more complex appearance adjacent to and surrounding the blood vessels.

Thirdly, hamster interlobular lymphatics had a unique ultrastructural feature not seen in either the rat or rabbit (Fig. 6). At points of contact between adjacent endothelial cells, one of the cells sometimes bifurcated into two separate cytoplasmic processes. One process joined the adjacent endothelial cell by an end to end,

Fig. 1. Light micrograph from a drip-fixed rat kidney showing an intralobular tributary (arrow) of an interlobular lymphatic (L). The intralobular branch lies next to an afferent arteriole (AA) and the interlobular lymphatic is next to an interlobular artery (A). Serial sections demonstrated that the afferent arteriole was a branch of the artery and supplied the renal corpuscle (RC) at the top. (X625)

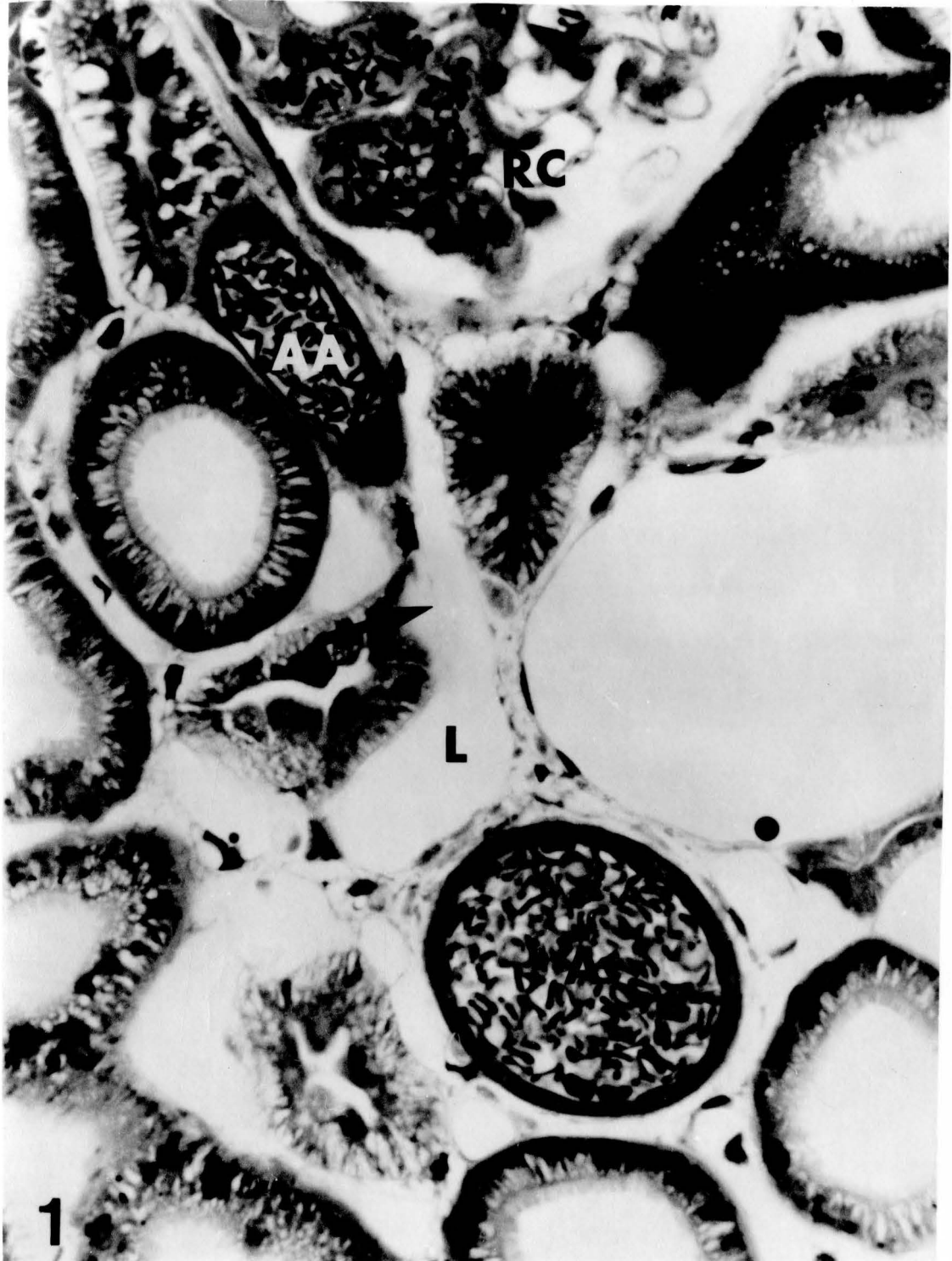


Fig. 2. Light micrograph showing an intralobular lymphatic (L) in the hamster kidney. The lymphatic lies adjacent to an afferent arteriole (AA) which supplies the renal corpuscle (RC) at the upper left. (X625)

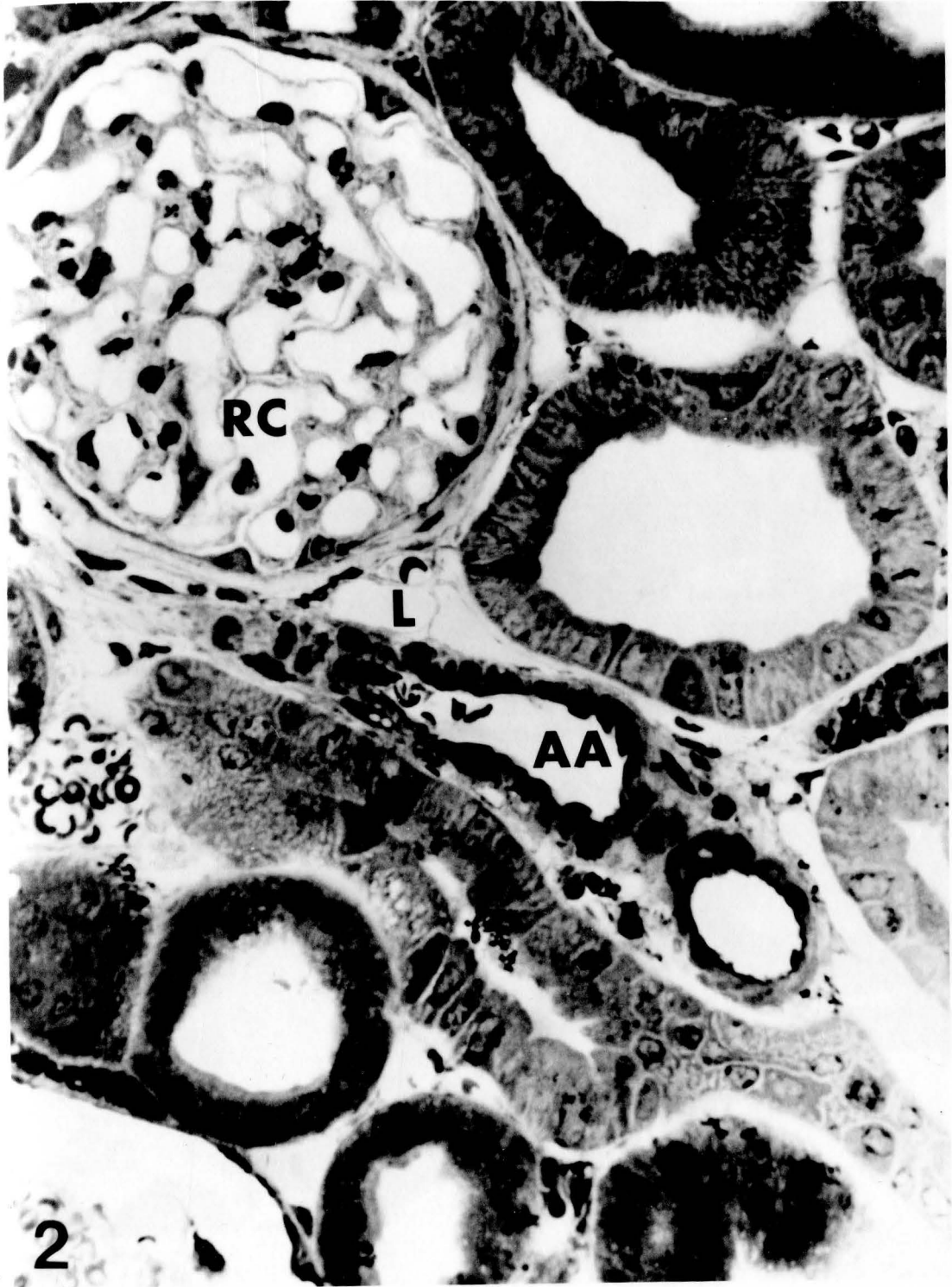



Fig. 3. Light micrograph showing intralobular lymphatics (arrows) related to tubules and blood capillaries only. All three lymphatics were confirmed as such by electron microscopy. (X810) a) Drip-fixed rat kidney. b) Perfusion-fixed rat kidney. c) Hamster kidney.

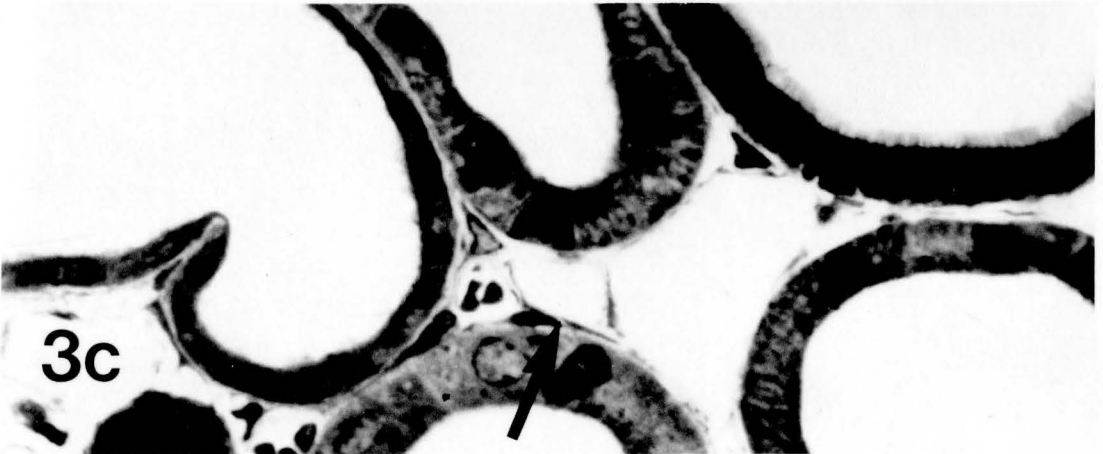
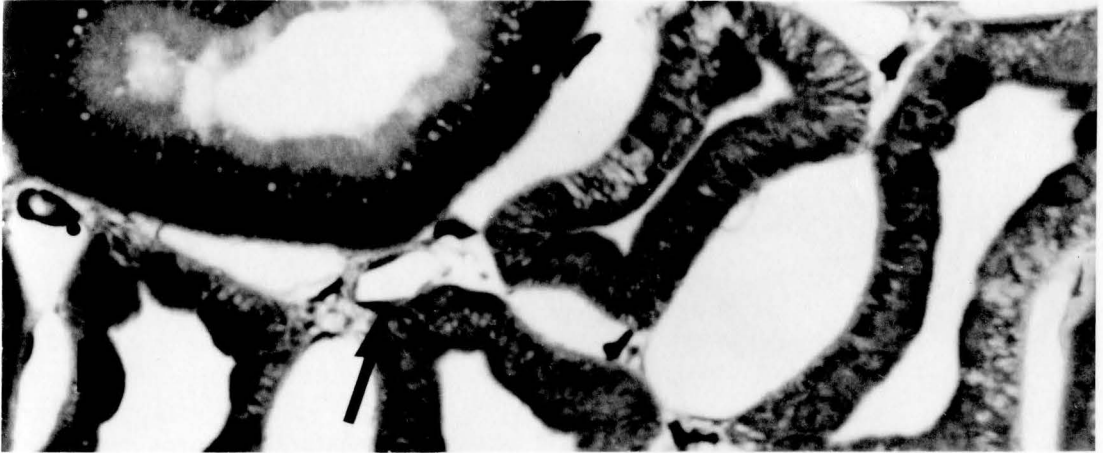
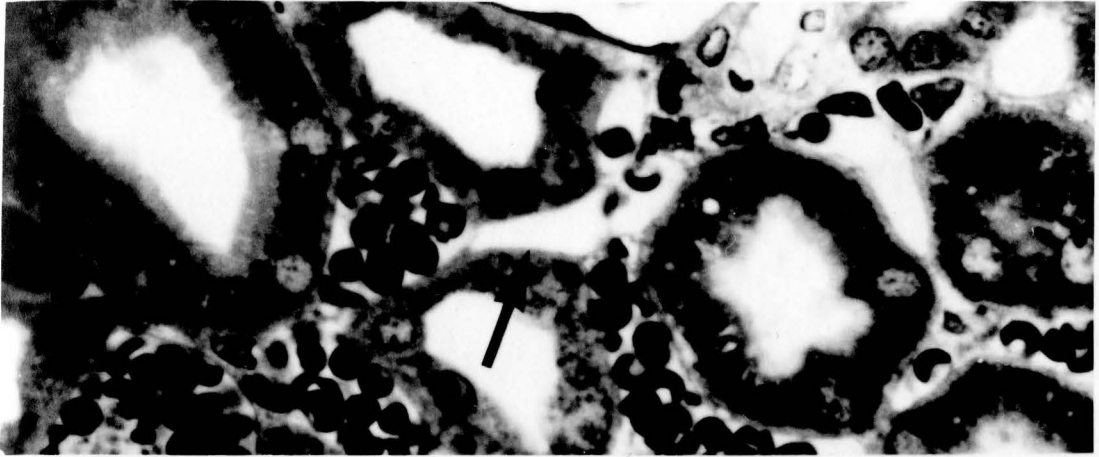


Fig. 4. Light micrograph showing an interlobular lymphatic in the rabbit kidney. The lymphatic (L) is associated with an interlobular artery (A) and vein (V). (X625)

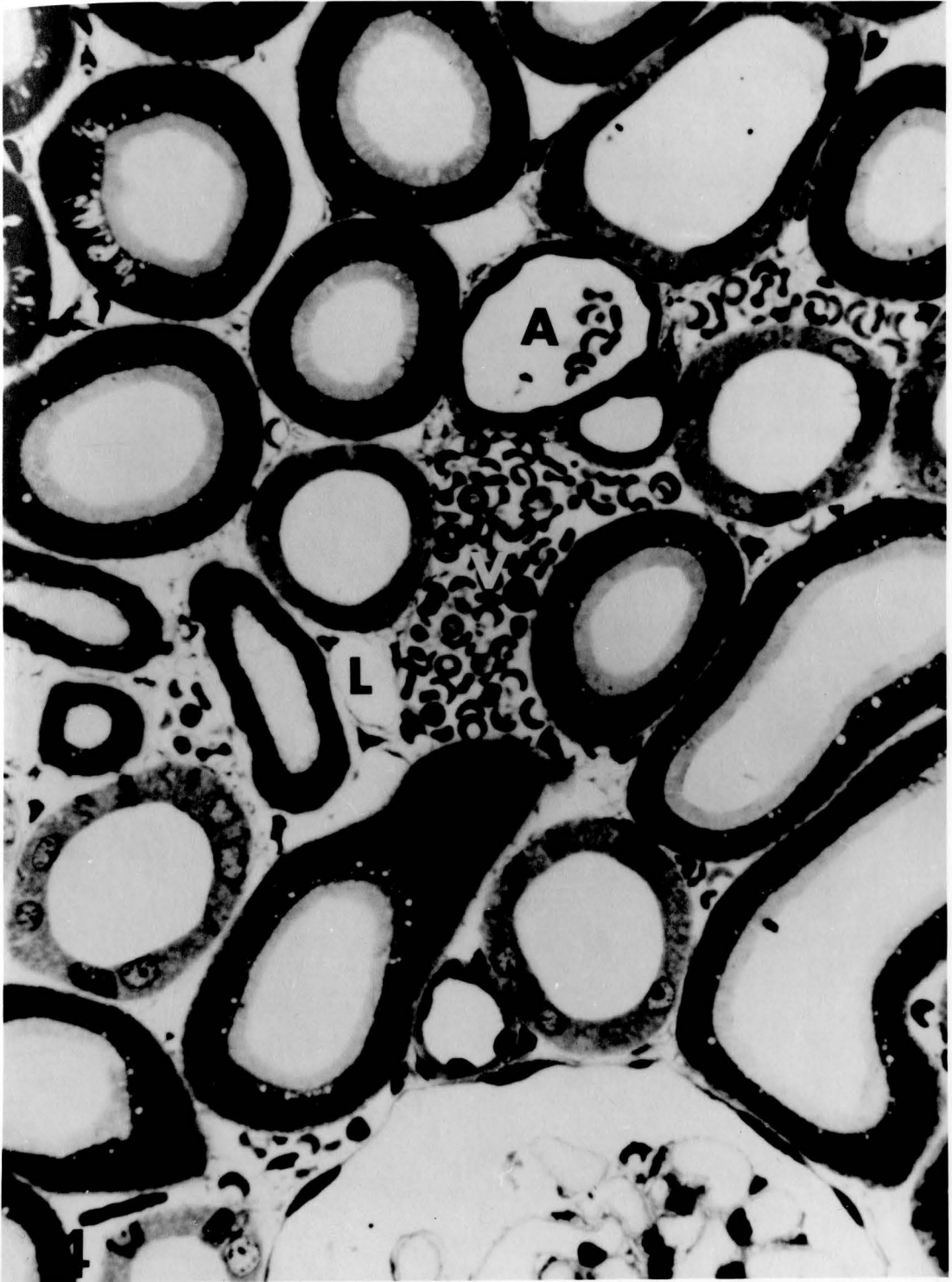


Fig. 5. Light micrograph showing interlobular lymphatics in the hamster kidney. Several lymphatics (L) are associated with an interlobular artery (A) and vein (V) (Compare to Figs. 1 and 4). Lymphatic near the bottom (arrow) could be an intra-lobular lymphatic related to tubules only but it could not be followed in serial sections. (X625)

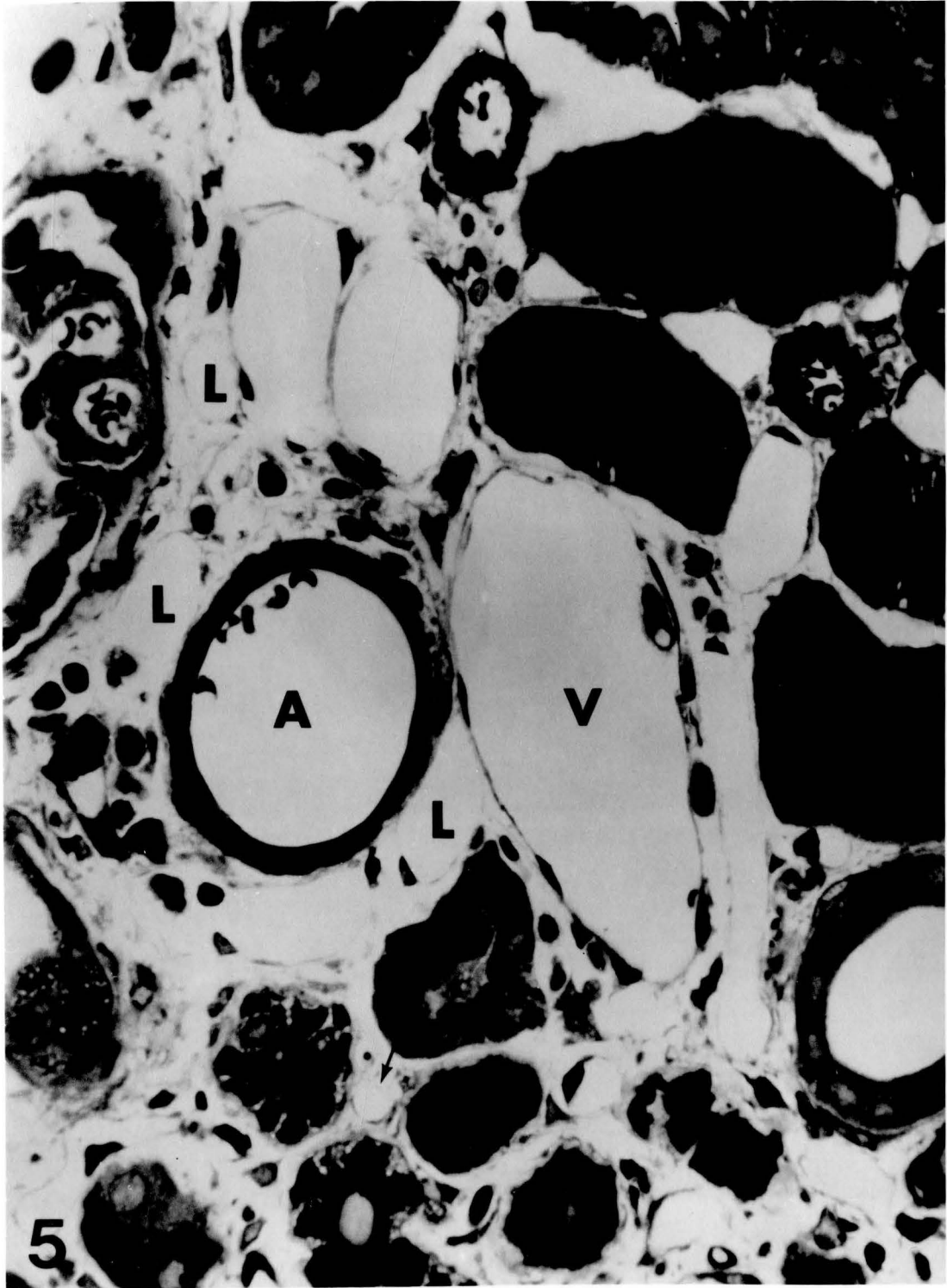


Fig. 6. Electron micrographs showing channel-like structures formed by hamster lymphatic endothelium. (X16,000)

a) Arrows point to ends of endothelial processes that partially enclose the interstitial space. Cytoplasmic process of a fibroblast (arrowhead) appears to complete the enclosure.

b) Endothelial processes (arrows) partially enclose the interstitial space. c) Completely enclosed structure.

L = Lumen of lymphatic vessel.

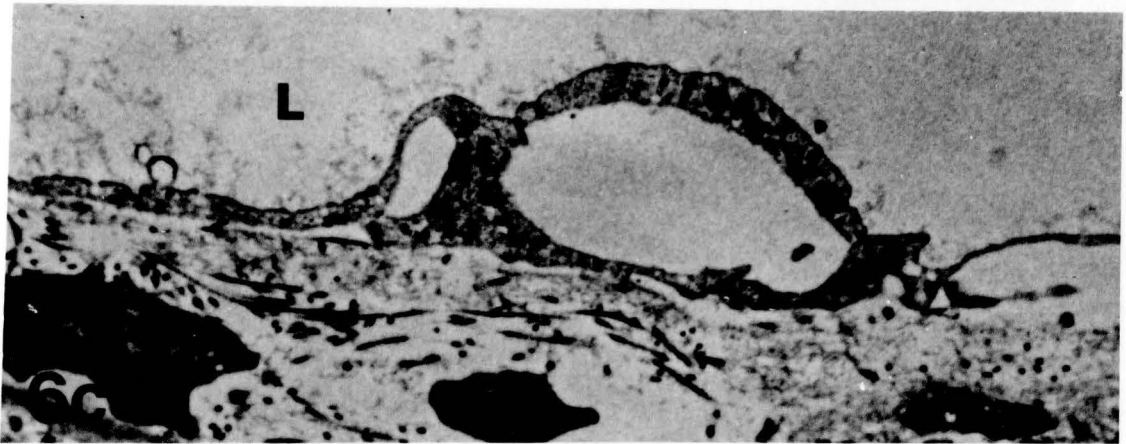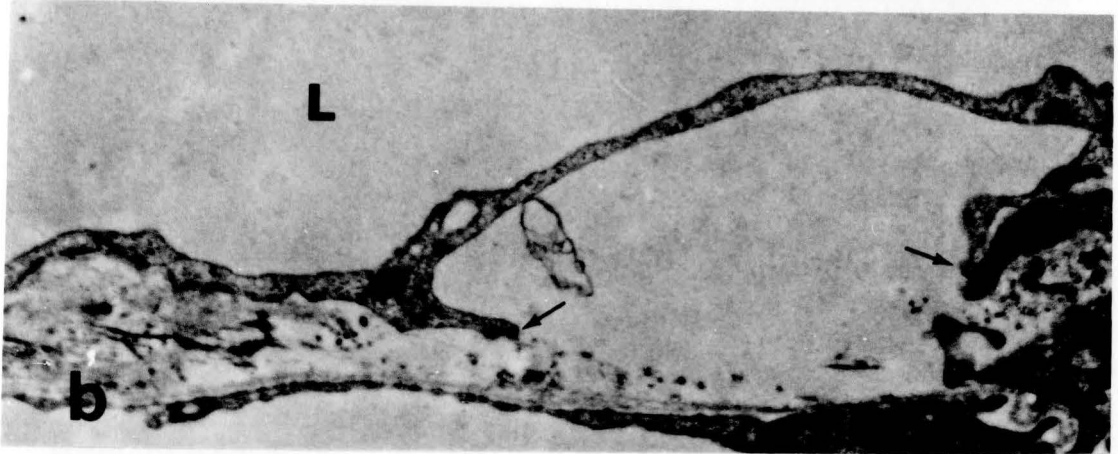
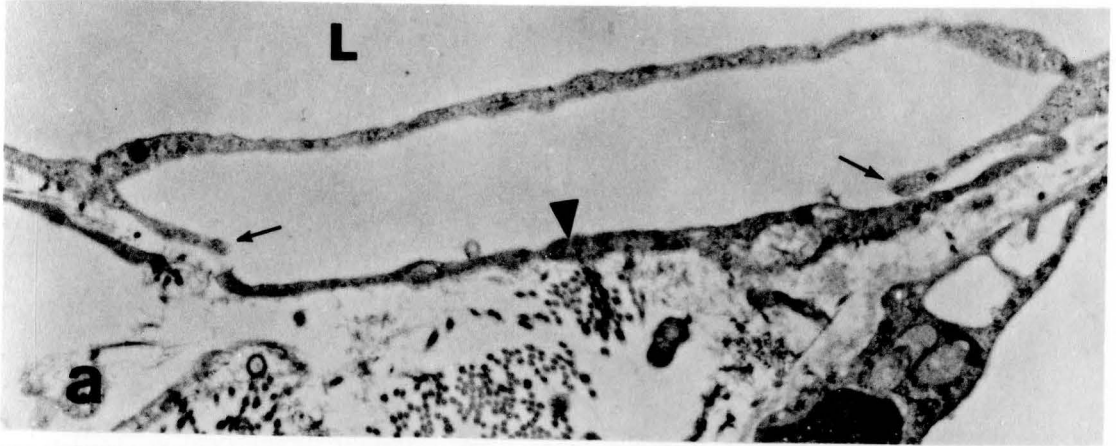
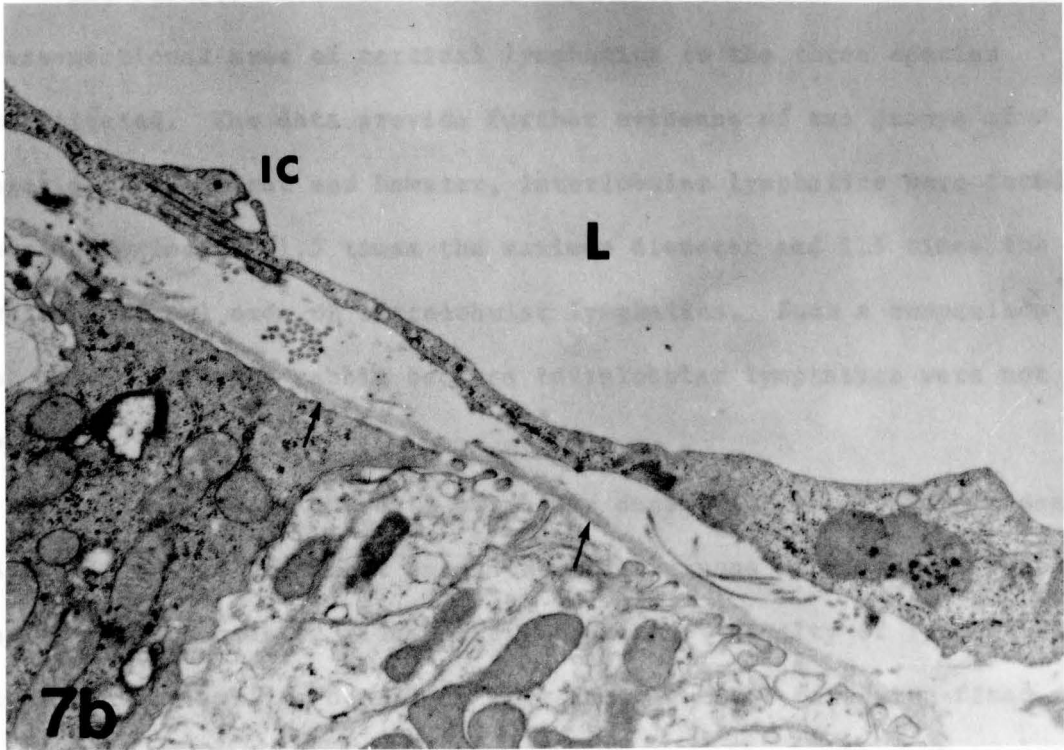
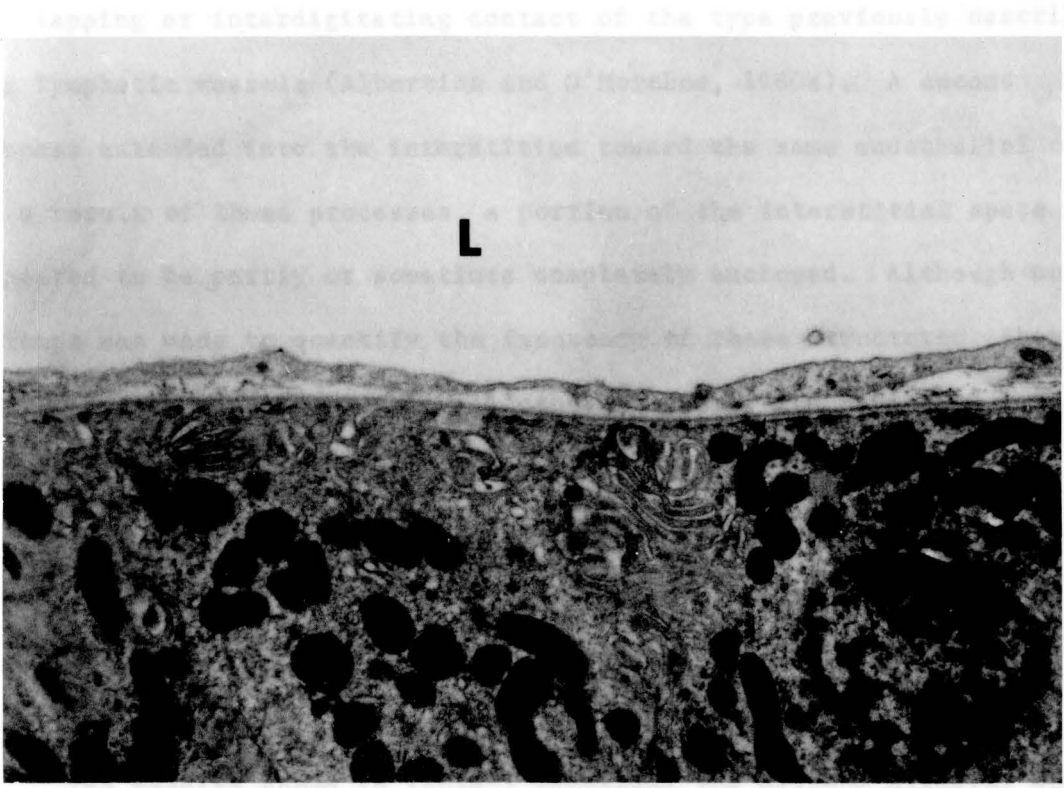




Fig. 7. Ultrastructure of lymphatics. (X16,000)

a) Electron micrograph of an intralobular lymphatic seen in Fig. 3a from rat kidney. The endothelium is non-fenestrated and lacks a basal lamina. Arrows point to the basal lamina of a renal tubule cell. b) Electron micrograph of an interlobular lymphatic seen in Fig. 4 from rabbit kidney. An intercellular contact (IC) connects two endothelial cells. Arrows point to a basal lamina of a renal tubule cell. L = Lumen of lymphatic vessel.



7b

the rabbit kidney had the least of the three. The earlier observation

overlapping or interdigitating contact of the type previously described for lymphatic vessels (Albertine and O'Morchoe, 1980a). A second process extended into the interstitium toward the same endothelial cell. As a result of these processes, a portion of the interstitial space appeared to be partly or sometimes completely enclosed. Although no attempt was made to quantify the frequency of these structures, they were a common occurrence. In all other respects, lymphatics of rat and rabbit kidneys (Figs. 7a and 7b) were ultrastructurally similar to hamster vessels. All lymphatics had a thin wall consisting of a single layer of continuous endothelium and lacked a continuous basal lamina.

#### Quantitative

The results shown in Table I represent the maximum diameter and cross-sectional area of cortical lymphatics in the three species investigated. The data provide further evidence of two groups of vessels. In the rat and hamster, interlobular lymphatics were found to have approximately 1.5 times the maximum diameter and 2.5 times the cross-sectional area of intralobular lymphatics. Such a comparison is not possible in the rabbit because intralobular lymphatics were not found.

Table II shows the data on volume density ( $V_V$ ) and profile density ( $N_A$ ). It can be seen that among the three groups of kidneys fixed by perfusion, the hamster kidney had the greatest density of lymphatics. Significantly smaller densities were found for the perfusion-fixed rat; the rabbit kidney had the least of the three. The earlier observation

that hamster interlobular lymphatics appeared in larger numbers was confirmed by the values given for  $N_A$ . Table I and II also demonstrate that the method of fixation influenced the measured cross-sectional area and density of renal lymphatics. The perfused rat kidney had larger interlobular lymphatics than did the drip-fixed organ (235.5 versus  $171.6 \mu\text{m}^2$ ,  $p < .01$ ) as well as a larger volume density ( $1.1$  versus  $0.2 \mu\text{m}^3/\mu\text{m}^3 \times 10^{-3}$ ,  $p < .01$ ). The size of intralobular lymphatics appear to be unaffected by the method of fixation.

Table I: MEAN SIZE OF CORTICAL LYMPHATICS

Species	#Ly	Maximum Diameter ( $\mu\text{m} \pm \text{SEM}$ )	Cross-sectional Area ( $\mu\text{m}^2 \pm \text{SEM}$ )
<b>Hamster</b>			
Interlobular	9	22.3 $\pm$ 1.6 <sup>a</sup>	285.6 $\pm$ 36.6 <sup>g</sup>
Intralobular	10	14.7 $\pm$ 0.8 <sup>b</sup>	118.7 $\pm$ 9.5 <sup>h</sup>
<b>Rat-Perfused</b>			
Interlobular	16	20.4 $\pm$ 0.9 <sup>c</sup>	235.5 $\pm$ 15.2 <sup>i</sup>
Intralobular	20	12.2 $\pm$ 0.6 <sup>d</sup>	77.9 $\pm$ 6.3 <sup>j</sup>
<b>Rat-Dripped</b>			
Interlobular	15	19.7 $\pm$ 0.6 <sup>e</sup>	171.6 $\pm$ 9.8 <sup>k</sup>
Intralobular	11	12.0 $\pm$ 0.5 <sup>f</sup>	76.6 $\pm$ 4.8 <sup>l</sup>
<b>Rabbit</b>			
Interlobular	13	14.2 $\pm$ 0.3	92.5 $\pm$ 3.7

$a > b$        $g > h$   
 $c > d$        $i > j$   
 $e > f$        $k > l$

}  $p < .01$

Ly - lymphatic vessels

Table II: DENSITY OF CORTICAL LYMPHATICS

Species	#Ly	Volume Density ( $V_V$ ) ( $\mu\text{m}^3/\mu\text{m}^3 \times 10^{-3} \pm \text{SEM}$ )	Profile Density ( $N_A$ ) ( $\# \text{Ly}/\text{mm}^2 \pm \text{SEM}$ )
Hamster	83	$3.7 \pm 0.01^a$	$16.4 \pm 0.8^d$
Rat-perfused	53	$1.1 \pm 0.16^b$	$5.3 \pm 0.8^e$
Rat-dripped	24	$0.2 \pm 0.01^c$	$3.5 \pm 0.8$
Rabbit	22	$0.2 \pm 0.01$	$3.3 \pm 0.1$

$a > b > c$   
 $d > e$

}  $p < .01$

Ly - lymphatic vessels

Discussion

The method employed in the present study, whereby the electron microscope is used to identify lymphatics in tissue sections and the light microscope to trace these vessels in serial sections, permits known lymphatics to be followed for considerable distances through tissue. This ability to follow renal lymphatics more deeply towards the medulla and superficially toward the capsule may explain why we were able to identify small intralobular lymphatics that might otherwise have been overlooked in our studies. Thus, our more systematic and methodical approach may explain the discrepancy between our studies and those of other investigators who failed to find intralobular lymphatics in the rat.

The reason we did not find rabbit intralobular lymphatics is unclear. On the one hand, they simply may not exist. On the other hand, if rabbit intralobular lymphatics do exist, they must be smaller than the smallest lymphatics we were able to find and trace in this study. This latter possibility seems unlikely since initial lymphatics are of a comparable size in most mammalian species studied. In addition, rabbit interlobular lymphatics are approximately the same size (maximum diameter = 14.2  $\mu\text{m}$ ) as hamster (14.7  $\mu\text{m}$ ) and rat (12.1  $\mu\text{m}$ ) intralobular lymphatics. From a morphological standpoint intralobular lymph, because of the close association between lymphatic and nephric elements (Fig. 7), is likely to derive a component from tubular reabsorbate. The dog kidney, for example, contains intralobular

lymphatic vessels and there is much evidence that canine renal lymph has a tubular component (O'Morchoe, 1985). In this respect, it is significant that intralobular lymph vessels were not found in the rabbit in the present study and that two published reports (Gartner et al., 1973; Vogel et al., 1974) conclude that tubular reabsorbate does not contribute to renal lymph in that species.

The lymphatics from all three species examined in this study had ultrastructural features typical of such vessels generally (Leak, 1980; Courtice, 1981; O'Morchoe, 1984). However, the hamster lymphatics also showed an arrangement of endothelial processes not seen in either the rat or rabbit. Since, electron microscopic serial sections were not examined in this study, the three-dimensional character of these endothelial arrangements was not clear. However, they appeared to fit the description of intraendothelial channels by Azzali (1982a,b) in the small intestine of several animals. He proposed that these channels provide a conduit for the open flow of lipid and other substances from the interstitium to the lumen of lymphatic vessels. It is unclear from our studies whether the structures seen in hamster kidney provide an open conduit for transendothelial transport but at no time was direct communication seen between interstitium and lumen.

Quantitatively, hamster cortical lymphatics were also found to be different from the rat and rabbit. The hamster, which has the highest urinary concentrating capacity (UCC) of the three species, also has the highest density of cortical lymphatics. The rabbit, with the lowest UCC of the species included in this study, also has the lowest cortical



lymphatic density. The rat has both a UCC and lymphatic density intermediate between the hamster and the rabbit. A previous study on canine intrarenal lymphatics (O'Morchoe and Albertine, 1980) determined a volume density of 0.14%. This value is consistent with our data placing the canine kidney in the mid-range for both UCC and lymphatic density (Table III). How or why the density of the intrarenal lymphatic system might be related to the urinary concentrating capacity of the kidney is not at present clear.

We also found, in the present study, that lymphatics of perfusion-fixed rats have a larger cross-sectional area, volume and profile density than lymphatics of drip-fixed rats. Thus fixation technique had a significant effect upon the measured size and density of renal cortical lymphatics. The most likely explanation is that alterations of hydrostatic and oncotic pressures in the kidney during perfusion cause fluid to leak from the blood vasculature and enter the interstitium. This edema-like process causes the anchoring filaments to pull apart the walls of the lymphatics and thus distend the vessels (Leak, 1976). In this way the perfusion-fixed lymphatics could have larger cross-sectional areas, yet similar maximum diameters, than would their drip-fixed counterparts which tend to be collapsed within the tissues. A round lymphatic vessel can have the same maximum diameter but a significantly smaller cross-sectional area than a collapsed lymphatic. Another factor promoting collapse would be the swelling of adjacent tubules caused by relatively poor fixation in the dripping method. Further, completely collapsed lymphatic vessels in such preparations

**Table III: URINARY CONCENTRATING CAPACITY, LYMPHATIC VOLUME DENSITY AND PROFILE DENSITY IN FOUR SPECIES OF LABORATORY ANIMALS**

Species	UCC (mOsm/L)	$V_V$ ( $\mu\text{m}^3/\mu\text{m}^3$ )	$N_A$ (#/mm <sup>2</sup> )
Hamster	5,340 <sup>1</sup>	.0037	16.4
Rat-perfused	3,250 <sup>1</sup>	.0011	5.3
Dog	2,400 <sup>2</sup>	.0014 <sup>3</sup>	-
Rabbit	1,390 <sup>1</sup>	.0002	3.3

Abbreviations: UCC = urinary concentrating capacity;  $V_V$  = volume density;  $N_A$  = profile density.

<sup>1</sup>Munkasci and Palkovits (1977)

would be hard to find and could thus account for the lower profile density. This combination of fewer and smaller lymphatics in drip-fixed rat kidneys can explain their smaller volume density.

If the above explanation is correct it would seem that the  $V_V$  for perfusion-fixed rats may be an over-estimate of the living state because of the distention of the vessels; conversely the  $N_A$  for drip-fixed rats may be too low because not all lymphatics were identified. In vivo values may therefore lie between the values we obtained.

Finally, the data we have obtained in this study can be used to calculate the rate of lymph formation (volume of lymph per time per area of endothelium) in renal cortical lymphatics of the rat. This rate is simply the cortical lymph flow divided by the total lymphatic endothelial surface area contained in the cortex. The cortical lymph flow is estimated to be 1.0  $\mu\text{l}/\text{min}/\text{g}$  renal cortex or about 75% of the total renal lymph flow of 1.4  $\mu\text{l}/\text{min}/\text{g}$  kidney (Deen et al., 1976), since cortical lymphatics represent about 75% of total intrarenal lymphatic surface area (O'Morchoe et al., 1982). Additionally, Wolgast (1973) found that the cortex is about 70% of the total renal weight in rats.

The lymphatic endothelial surface area of the cortex can be estimated in two ways. The first is according to the equation:  $S_V = (4 \times B_A) / \pi$  (Weibel, 1973), where  $S_V$  is surface density and  $B_A$  is defined as the length of all profiles (in this case lymphatics) per unit area. For the present calculation,  $B_A$  is equal to the average lymphatic perimeter (50 $\mu\text{m}$ ) times the lymphatic profile density (5.3 lymphatics/ $\text{mm}^2$ ). Thus,  $S_V$  is about 0.00034  $\mu\text{m}^2/\mu\text{m}^3$  or 3.4  $\text{cm}^2/\text{g}$  renal cortex if the density of

the renal cortex is assumed to be one ( $1 \text{ g/cm}^3$ ). The second way of estimating the surface area is the method used by O'Morchoe et al. (1982). These investigators reasoned that all lymphatics in a specific region could be treated as a single cylinder having the radius equal to the average radius of all lymphatics in that region. The surface area ( $A_c$ ) of such a cylinder is equal to  $(2 \times V)/r$ , where  $V$  is the volume of the cylinder and  $r$  is the radius of the cylinder. Thus, cortical lymphatics can be treated as two cylinders, one having the volume and average radius of intralobular lymphatics, the second having the volume and average radius of interlobular lymphatics. According to O'Morchoe and Albertine (1980a), the volume occupied by cortical lymphatics is divided approximately one-third to two-thirds between intralobular and interlobular lymphatics, respectively. For the present calculation, assuming that the density of the renal cortex is again  $1 \text{ g/cm}^3$ , intralobular lymphatics occupy approximately  $0.00035 \text{ cm}^3/\text{g}$  renal cortex while interlobular lymphatics occupy about  $0.00075 \text{ cm}^3/\text{g}$  renal cortex. The surface area of intralobular lymphatics (average radius =  $0.0006 \text{ }\mu\text{m}$ ) is then  $1.2 \text{ cm}^2/\text{g}$  renal cortex and that of interlobular lymphatics (average radius =  $0.001 \text{ }\mu\text{m}$ ) is  $1.5 \text{ cm}^2/\text{g}$  renal cortex for a total of  $2.7 \text{ cm}^2/\text{g}$  renal cortex.

Based on the present data, the rate of lymph formation in the renal cortex of the rat is approximately  $0.3$  to  $0.4 \text{ }\mu\text{l}/\text{min}/\text{cm}^2$  of lymphatic endothelium. This rate is somewhat smaller than that calculated for canine renal lymphatics ( $1 \text{ }\mu\text{l}/\text{min}/\text{cm}^2$ , O'Morchoe et al., 1982). However, this difference cannot, at this time, be considered

significant because of errors inherent in the morphometric study of structures as sparse as renal lymphatics. The data obtained in the present study do provide reasonable working estimates until more accurate methodologies become available.

In summary, it was concluded that: 1) tubular reabsorbate may contribute to renal lymph in the rat and hamster but not in the rabbit; 2) significant differences exist between the renal lymphatic systems of the three species with the hamster having the richest network and the rabbit the poorest; 3) the method of fixation influenced the measured size and density of renal cortical lymphatics; and 4) the rate of lymph formation in the kidney of the rat is comparable to that in the dog (O'Morchoe et al., 1982).

## CHAPTER V

### THE PATTERN AND DISTRIBUTION OF INTRAHEPATIC LYMPH VESSELS IN THE RAT

#### Abstract

The pattern and distribution of intrahepatic lymph vessels were examined by light and electron microscopy in rat livers fixed by perfusion through the portal vein. Lymph vessels were found in the connective tissue of larger portal canals where they coursed in close association with branches of the hepatic artery. Of the portal canals which lacked a lymphatic, over 50% also lacked an arterial component. The smallest portal canals contained no lymphatics. Direct connections between the lymphatic lumen and the space of Disse or Mall were not observed but lymphatics were found close to Mall's space, separated by only a sparse connective tissue space containing a few collagen fibrils. Lymphatics were neither seen within the parenchyma, nor associated with intercalated (sublobular) veins. Cross-sectional area ( $223.2 \pm 48.7 \mu\text{m}^2 \pm \text{SEM}$ ), maximum diameter ( $20.5 \pm 2.0 \mu\text{m}$ ), volume density ( $0.00098 \pm 0.00046 \mu\text{m}^3/\mu\text{m}^3$ ) and profile density ( $1.8 \pm 0.3 \text{ lymphatics}/\text{mm}^2$ ) of hepatic lymph vessels were determined by stereological measurement using a computer-based image analyzer. These data were used to estimate the

rate of lymph formation in the liver. It was concluded that (1) initial lymphatics probably originate in the portal canals; (2) the concept that fluid in the space of Disse can be regarded as the principal source of fluid forming hepatic lymph is questioned since initial lymphatics appear to be separated from the space of Disse by hepatocytes and the space of Mall; and (3) the rate of lymph formation in the liver of the rat is approximately 0.06 to 0.08  $\mu\text{l}/\text{min}/\text{cm}^2$  of lymphatic endothelium.

### Introduction

The pattern and distribution of the initial elements of the intrahepatic lymphatic system have not been fully described. Thus, although most descriptions of the system (Elias, 1963; Rusznyak et al., 1967; Yoffey and Courtice, 1970; Barrowman, 1978) acknowledge the presence of lymphatic vessels within the portal canals and associated with tributaries of the hepatic vein, the origin of these vessels is not known. Elias (1949b) maintained that small lymphatics accompany the branches of hepatic arterioles (arterial capillaries) and tributaries of bile ducts as they enter the lobule. Failure since then, however, to find lymphatics within the parenchyma suggests that they do not start within the traditional hepatic lobule (e.g. Comparini, 1969; Schatzki, 1978). Thus, Elias' concept no longer receives support, the current view being that lymphatic vessels are confined to connective tissue outside the lobule.

The absence of lymphatics from the traditional hepatic lobule raises questions about the origin and transport of hepatic lymph. According to the most widely held concept, the fluid from which lymph is formed in the liver, begins with the filtration of blood plasma through the discontinuous sinusoids into the perisinusoidal space of Disse. Once in the space of Disse, the filtrate moves toward the periphery of the lobule and thence to the periportal space of Mall. From there it diffuses through the connective tissue in the portal canals to reach lymphatic vessels. Confirmation of this theory requires a better understanding of the exact anatomical relationship between the initial lymphatics and the spaces of Disse and Mall (Rusznyak et al., 1967).

One reason for the lack of knowledge on the extent of lymphatics within the hepatic parenchyma is the difficulty in distinguishing them from blood vessels in tissue sections by light microscopy. Electron microscopy is a more precise tool for the identification of lymphatics, but this technique is limited because the small specimens provide little information on the distribution of the vessels. We have recently devised a technique that combines the most advantageous features of light and electron microscopy and which overcomes these problems (Niro et al., 1982). This method permits verification of lymphatics at the ultrastructural level, with subsequent tracing of the same lymphatics through serial thick-sections by light microscopy.

Morphological quantitative data on the extent of the intrahepatic lymph system are also lacking. Such data are desirable in order to compare the system in the liver to that in other organs and tissues, for



example, by volume density, profile density and rate of lymph formation. The only quantitative data available have come from functional studies in which the rate of flow and composition of the lymph were measured (Ritchie et al., 1959; Friedman et al., 1959; Lee, 1984).

The primary purpose of the present study was to examine intrahepatic lymph vessels in the rat, utilizing our light and electron microscopic technique in order to address the two problems presented above. First, what is the pattern and distribution of initial lymphatics within the liver with special reference to their relation with the spaces of Disse and Mall? Second, what is the extent and quantity of the intrahepatic lymph system?

A second purpose of the present work was to obtain quantitative data that could be used to determine the rate of lymph formation. The intent was to calculate the surface area across which lymph is formed and to utilize published data on the flow of lymph (Friedman et al., 1959; Lee, 1984) to estimate lymph capillary permeability in terms of volume of fluid per time per unit area of endothelium.

## Materials and Methods

### General

Eight adult male Sprague-Dawley rats (Harlan) weighing 225-330 g (mean wt. = 273) were anesthetized with intraperitoneal sodium pentobarbital (50 mg/kg body weight). The portal vein was approached through a ventral midline incision and cannulated with a PE 90

polyethylene tube. The cannula connected by a three-way stopcock to two one-liter bottles, one containing heparinized physiologic saline and the other containing 2% glutaraldehyde in .16M sodium cacodylate buffer, pH 7.4. All visible tributaries to the portal vein were ligated. The perfusion was initiated with saline (approximately 10 ml) for 30 seconds or until the livers blanched and then switched to fixative.

Simultaneously with the start of the perfusion, the vena cava caudalis was cut and the celiac artery clamped. Perfusion with fixative at a pressure of 40 mm Hg was continued for an average of 15 minutes, until 100-150 ml had been administered to each animal. At the end of perfusion, the liver was light brown in color and firm to the touch. The organs were excised and blocks (2x2 mm) of well-fixed tissue were removed from various regions of the liver. The tissue blocks were immersed for one hour in 2% glutaraldehyde, post-fixed for one hour in 1% osmium tetroxide, dehydrated in acetone and embedded in epoxy resin (Kushida, 1971).

### Light Microscopy

Blocks were oriented so that the most obvious macroscopically visible blood vessels were cut in cross-section. Thick (3 $\mu$ m) serial sections were cut and collected alternately on two series of glass slides. One series contained all the odd numbered sections and was reserved for light microscopy. This set of sections was stained with toluidine blue. The other series contained all even numbered sections and was reserved for electron microscopy. These sections were stained

but not covered. Thus, for any two adjacently cut sections, one was intended for light microscopy and the other was saved for electron microscopy.

### Electron Microscopy

Electron microscopy was performed on thin sections cut from thick sections that had been removed from the glass slides and reembedded. This was done by placing an inverted BEEM capsule over the uncovered section and filling it with embedding medium. After the medium was polymerized, the capsule containing the section was removed from the slide with a razor blade. The reembedded sections were then trimmed, re-cut at 70 - 90 nm and stained with uranyl acetate and lead citrate and mounted on coated one-hole grids (Galey and Nilsson, 1966) for examination in a Hitachi H600 electron microscope. Positive identification of lymphatics was based on standard ultrastructural criteria (Leak, 1984). These vessels were then followed by light microscopy in serial thick sections and whenever the path of lymphatics was in doubt, electron microscopy was used to re-locate its position. Lymphatics were followed over 75 - 100 alternate sections or approximately 450 - 600  $\mu\text{m}$ .

### Morphometry

Stereological measurements were made from thick sections by light microscopy on a Zeiss Videoplan image analyzer fitted with a drawing tube. A total of 32 thick sections from different blocks, four from

each liver, were chosen at random and examined for lymphatics by light microscopy. Possible lymphatics were then studied in adjacent sections by electron microscopy. For determination of volume density, the cross-sectional area of each lymphatic in a section as well as the total area of the thick section was measured on the image analyzer. The areal density was determined by dividing the area of the section occupied by lymphatic vessels by the total area of that section. The volume density is directly related to the areal density ( $A_A = V_V$ , Weibel, 1973). The profile density was estimated by dividing the number of lymphatic vessels in a section by the area of the section.

The cross-sectional area and maximum diameter of lymphatic vessels, bile ducts and interlobular arteries were measured by light microscopy on the image analyzer in 56 portal canals which were judged to be cut in cross-section.

## Results

### Light Microscopy

Ninety-five ultrastructurally verified intrahepatic lymph vessels were examined and followed in serial sections by light microscopy. Lymphatics were found only within the connective tissue of portal canals where they formed a network related to the terminal branches of the hepatic artery, portal vein, and bile duct (terminology according to Rappaport, 1973) (Fig. 1). Tributaries extending from the parenchyma and joining these lymphatics were not found. Branches of the hepatic

arteriole were found to enter the lobule, but lymphatics were never seen in association with these branches.

As portal canals and the vessels within them were followed toward their finer ramifications, the size of the lymphatic vessels decreased (Fig. 2). The smallest portal canals contained no lymphatics. The course of lymphatics within the portal canals appeared to follow most closely the path of the hepatic arteriole. An indication of the relationship between lymphatics and the hepatic arteriole is seen in Table I, which shows that in 58 portal canals that lacked a lymphatic, 31 also lacked an arteriole.

Occasionally, cleft-like spaces were observed surrounding intercalated veins and in the periportal space of Mall, but closer examination by electron microscopy failed to detect an endothelial lining to these spaces. Thus, they were not regarded as lymphatic vessels and were not pursued further.

### Electron Microscopy

The lymphatics observed in this study were structurally similar to lymphatics seen elsewhere in the body (Fig. 3). The non-fenestrated endothelium was thin (0.1-0.5  $\mu\text{m}$ ) and lacked a continuous basal lamina, although patches of granular material, collagen and reticular fibers were intimately associated with the abluminal surface (Fig. 4). At some points along the endothelium, collagen and reticular fibers appeared to be in intimate contact with the abluminal surface (Fig. 5). The endothelial cells were joined to each other by three types of

Figure 1. Light micrograph from a larger portal canal showing portal vein (PV), lymphatics (L), hepatic arterioles (A), bile ducts (BD) and blood capillaries (BC). X460.

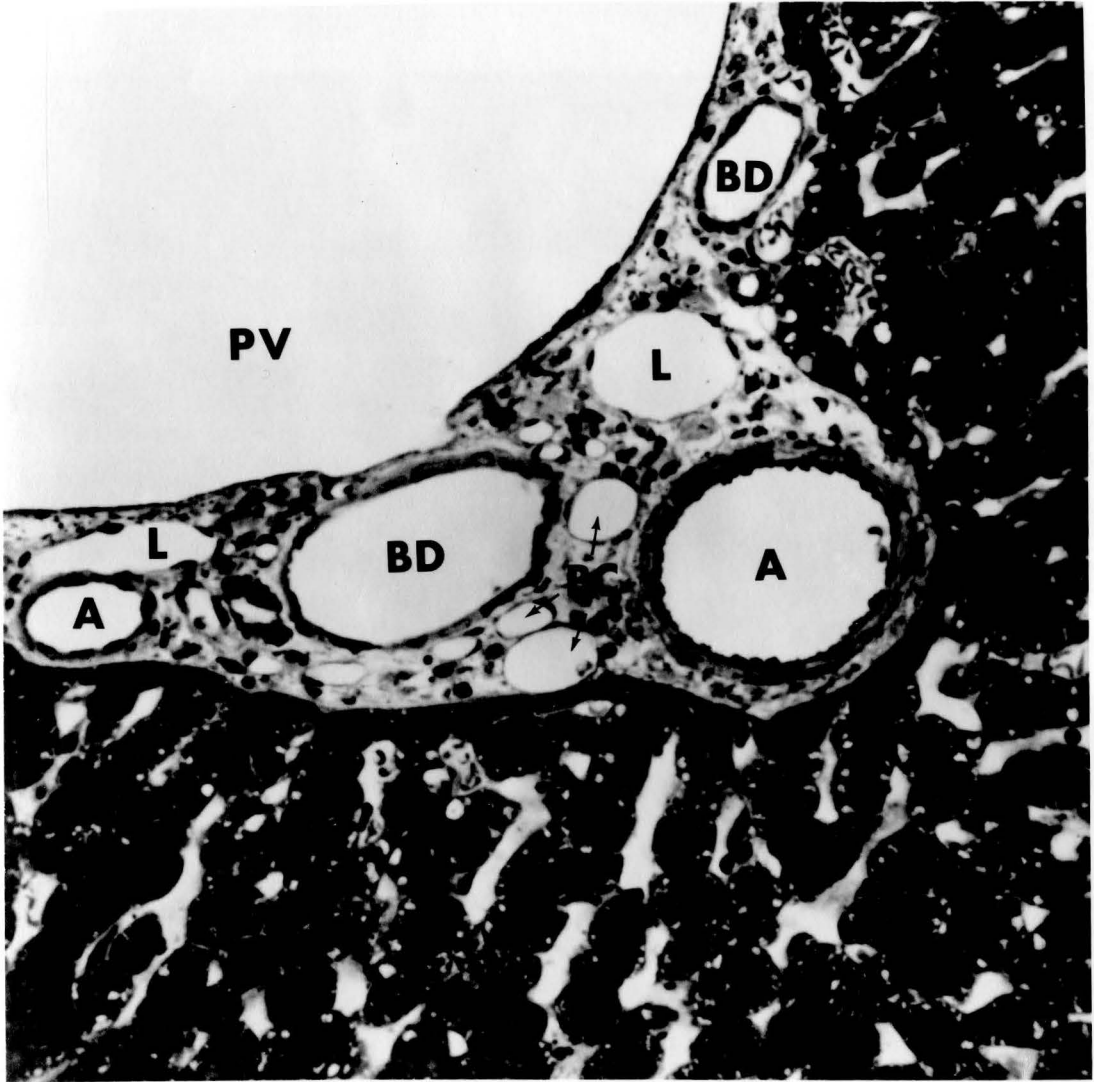


Figure 2. Light micrograph from a small portal canal showing portal vein (PV), bile duct (BD), hepatic arteriole (A) and lymphatic (L). X920.



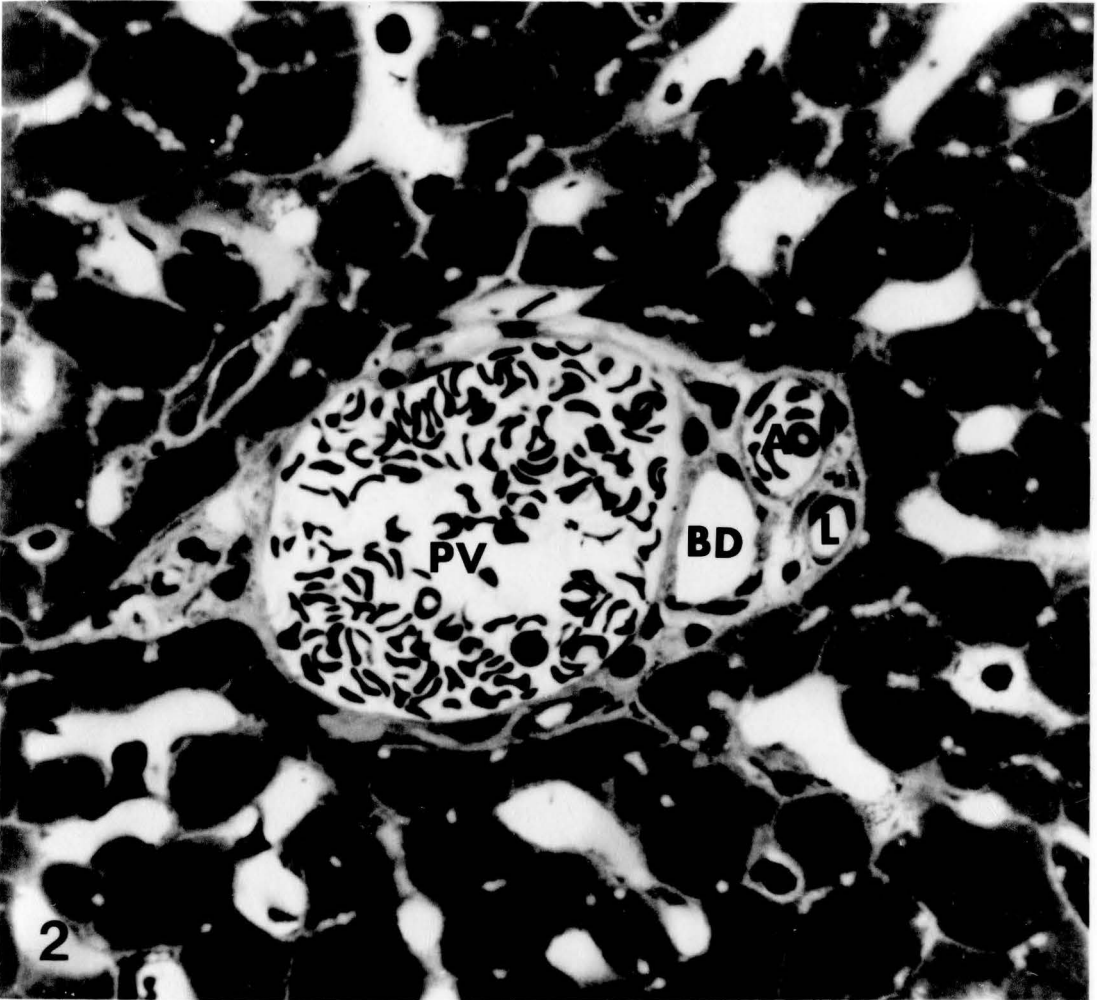


Figure 3. Low power electron micrograph showing portal vein (PV), lymphatic (L), bile duct (BD) and hepatic arteriole (A). X3,300.

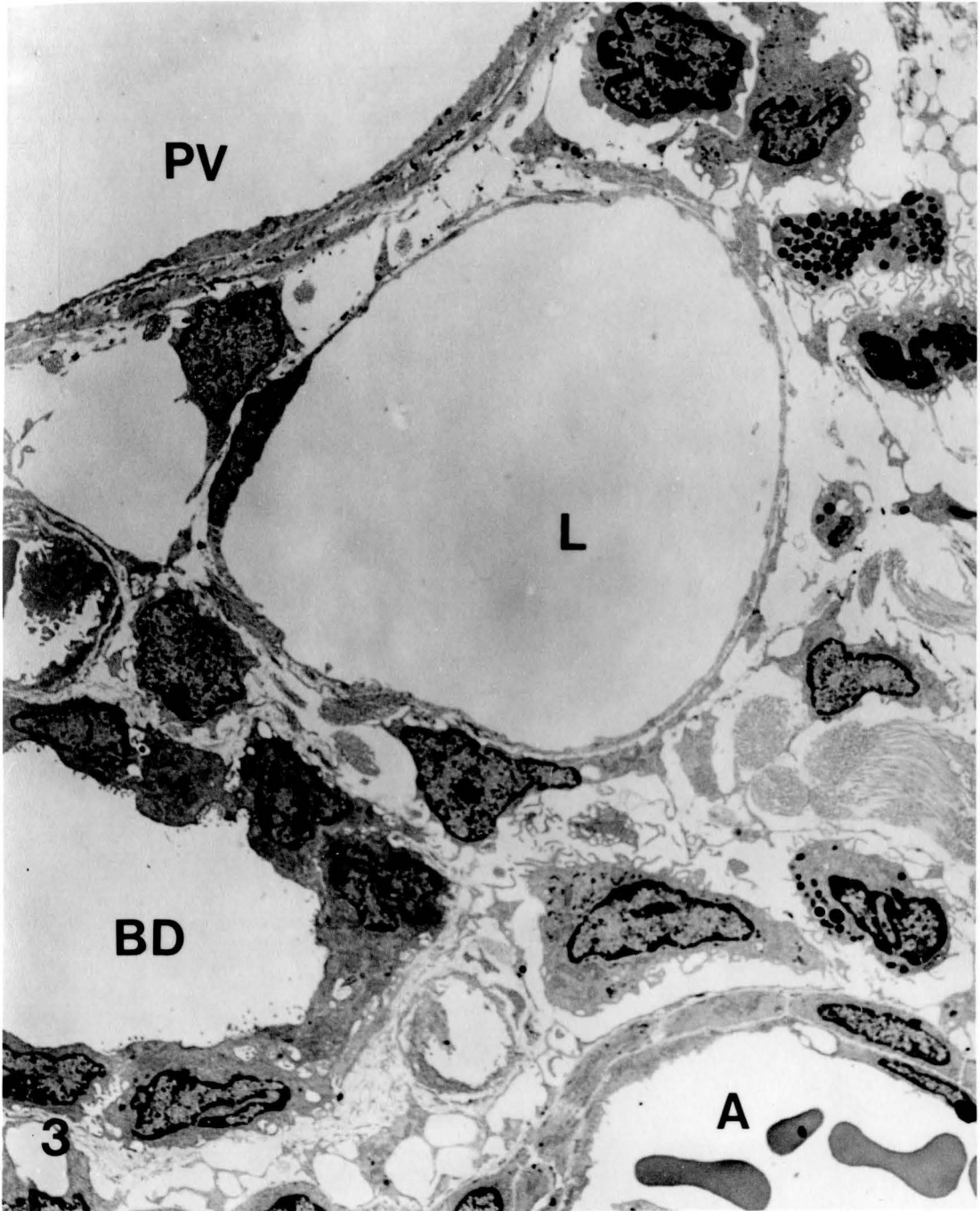


Figure 4. Electron micrograph showing usual arrangement between lymphatic (L) and spaces of Mall (M) and Disse (D). Collagen fibrils (CF), a hepatocyte (H) and a sinusoid (S) are also seen. X21,000.

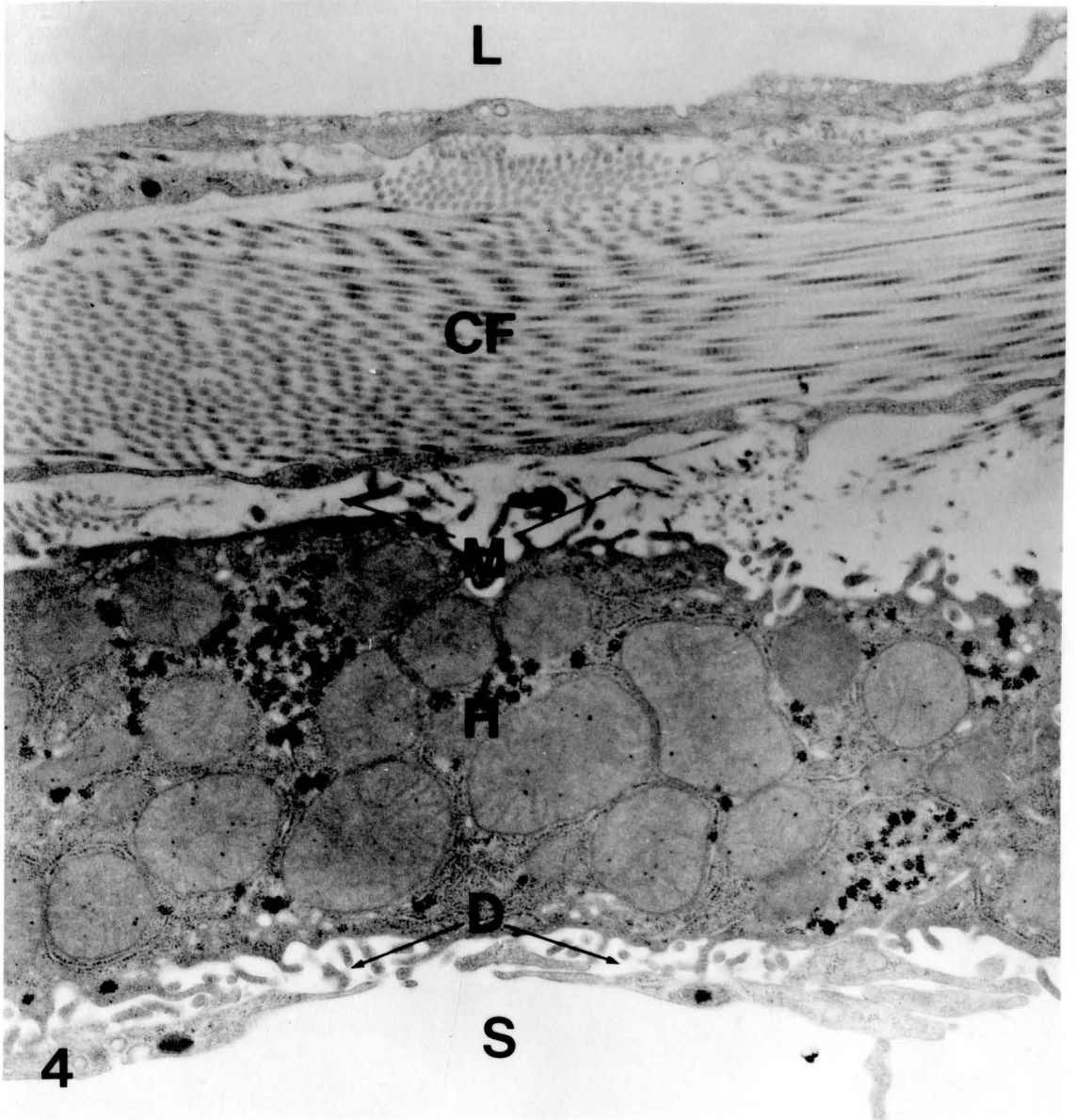


Figure 5. Electron micrograph showing intimate association between collagen fibrils (light arrows), reticular fibers (heavy arrows) and lymphatic endothelium. Lymphatic lumen (L), coated vesicles (cv), mitochondrion (m) and uncoated vesicles (v) are also shown. X48,000

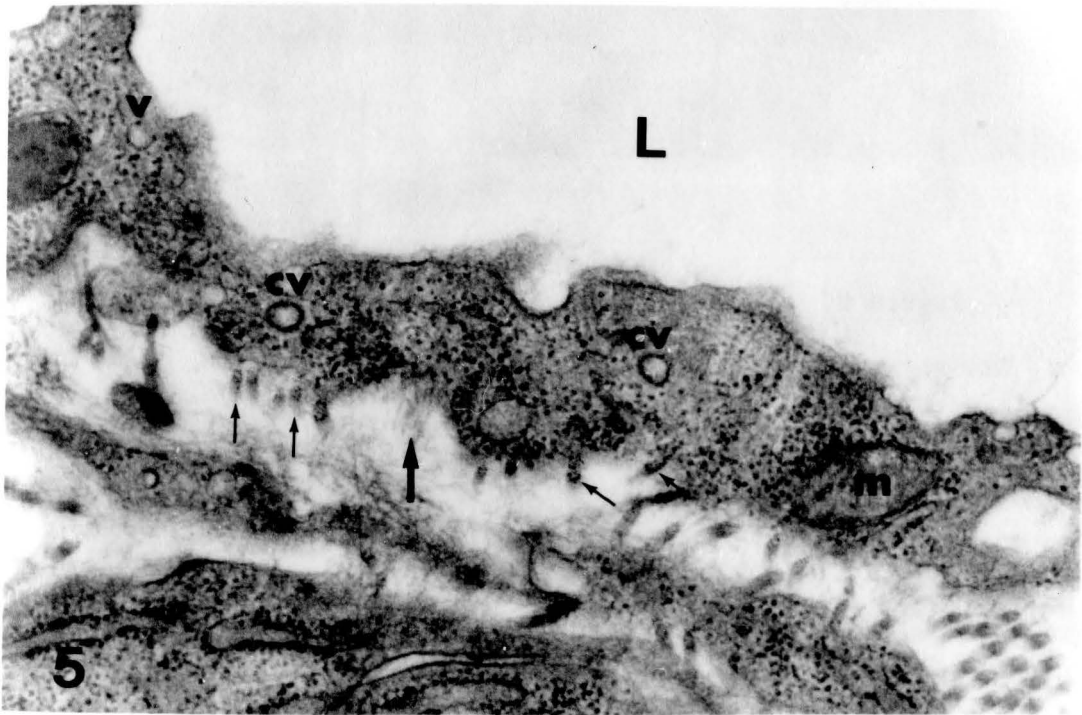
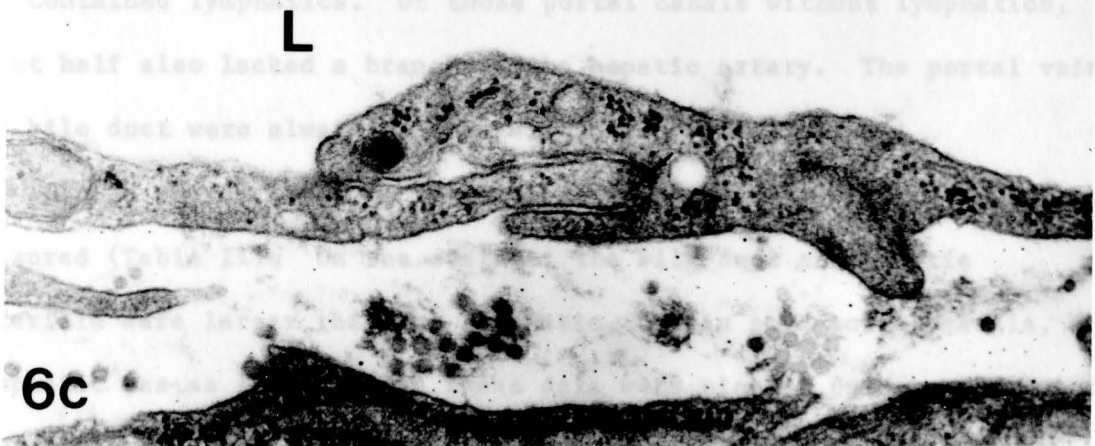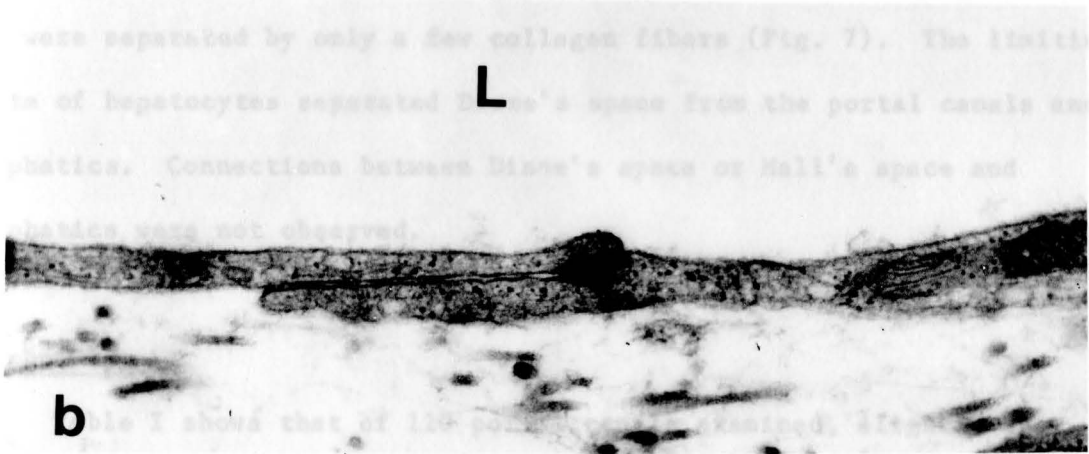

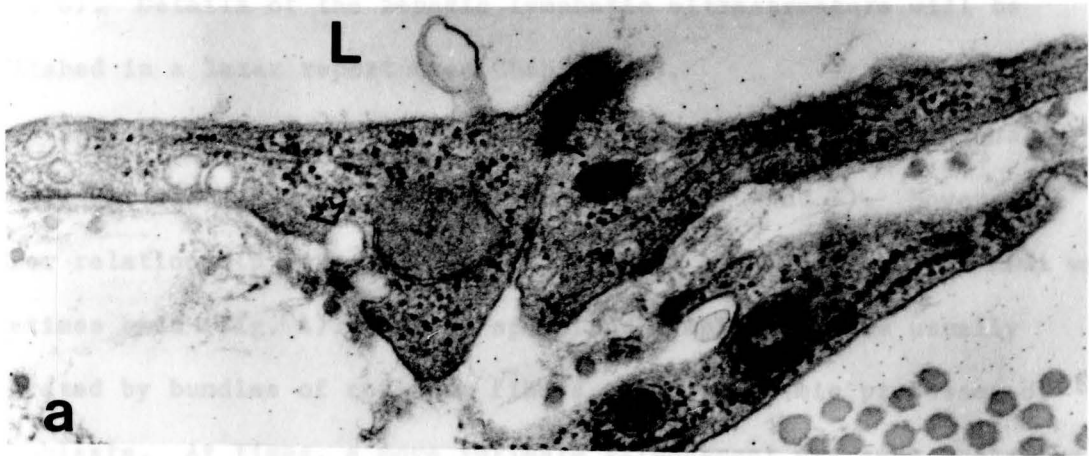
Figure 6. The types of intercellular contacts.

a) End-to-end junction, b) Overlapping junction,  
c) Interdigitating junction. Small arrows indicate  
specialized junctional complexes. Large arrows indicate  
uncoated vesicles. L = Lumen of lymphatic vessel. X48,000.





vessels was observed (Figs. 8 and 9).

intercellular contacts - end-to-end, overlapping and interdigitating (Fig. 6). Details of the hepatic lymphatic ultrastructure will be published in a later report (see Chapter VI).

The course of lymphatic vessels within the portal canals was usually far removed from the hepatocytes (Figs. 1 and 3). However, a closer relationship between lymphatic vessels and the spaces of Mall was sometimes seen (Fig. 4). Mall's space and lymphatics were usually separated by bundles of collagen fibers and cytoplasmic processes of fibroblasts. At times, a more intimate arrangement was seen where the two were separated by only a few collagen fibers (Fig. 7). The limiting plate of hepatocytes separated Disse's space from the portal canals and lymphatics. Connections between Disse's space or Mall's space and lymphatics were not observed.

### Morphometry

Table I shows that of 120 portal canals examined, slightly over 50% contained lymphatics. Of those portal canals without lymphatics, about half also lacked a branch of the hepatic artery. The portal vein and bile duct were always present within the portal canal.

In 56 portal areas, a lymphatic, bile duct and arteriole were measured (Table II). On the average, the bile duct and hepatic arteriole were larger than the lymphatic, but in some portal canals, the lymphatic was as large. When these data were plotted on a scatter-plot, a close correlation between the cross-sectional areas of the three types of vessels was observed (Figs. 8 and 9).

The volume density of intrahepatic lymph vessels was found to be  $0.00098 \pm 0.00046 \mu\text{m}^3/\mu\text{m}^3 \pm \text{SEM (N=8)}$ . The profile density was  $1.8 \pm 0.3 \text{ lymphatics/mm}^2 \pm \text{SEM (N=8)}$ .

Figure 7. Electron micrograph showing close relationship between lymphatic (L), Mall's space and hepatocyte (H). Arrows indicate coated vesicles. X43,000.

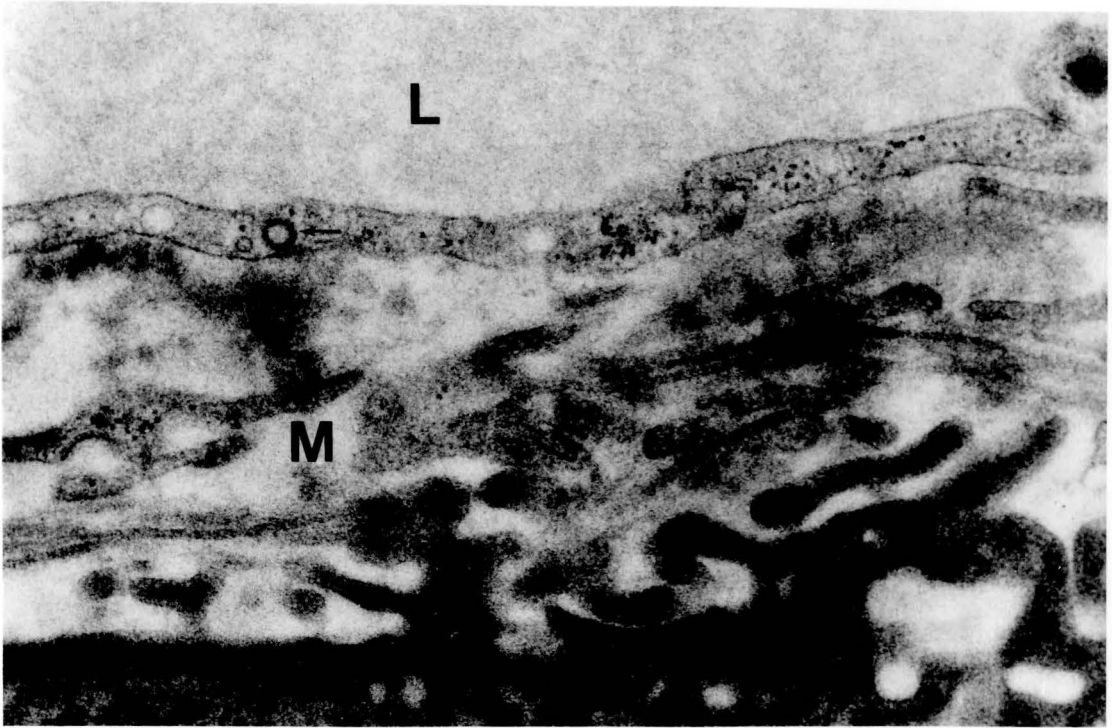


Figure 8. Scatter-plot demonstrating relationship between cross-sectional area of hepatic arterial branch and lymphatic. Dashed-line indicates regression line ( $r = .877$ ).

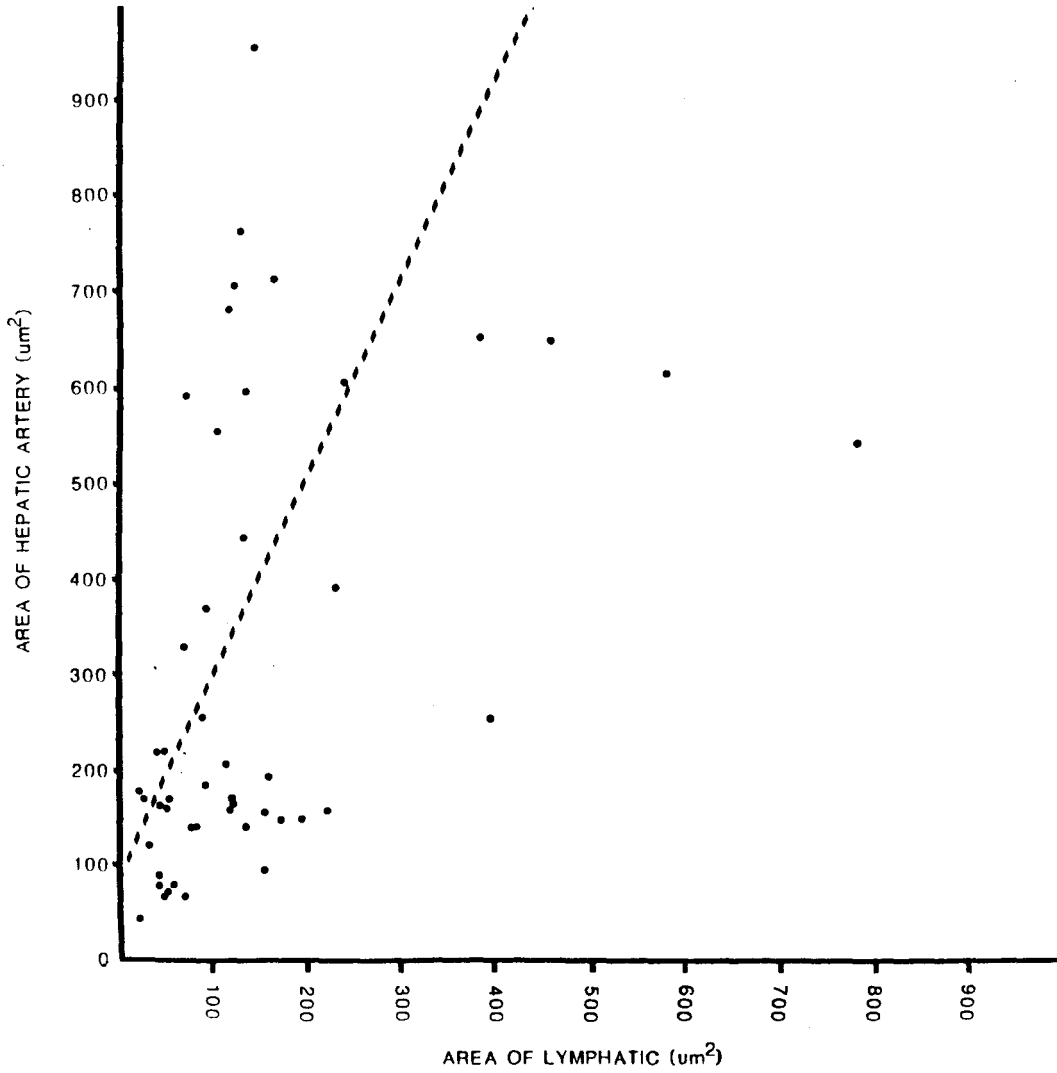


Figure 9. Scatter-plot demonstrating relationship between cross-sectional area of bile duct and lymphatic. Dashed-line indicates regression line ( $r = .908$ ).



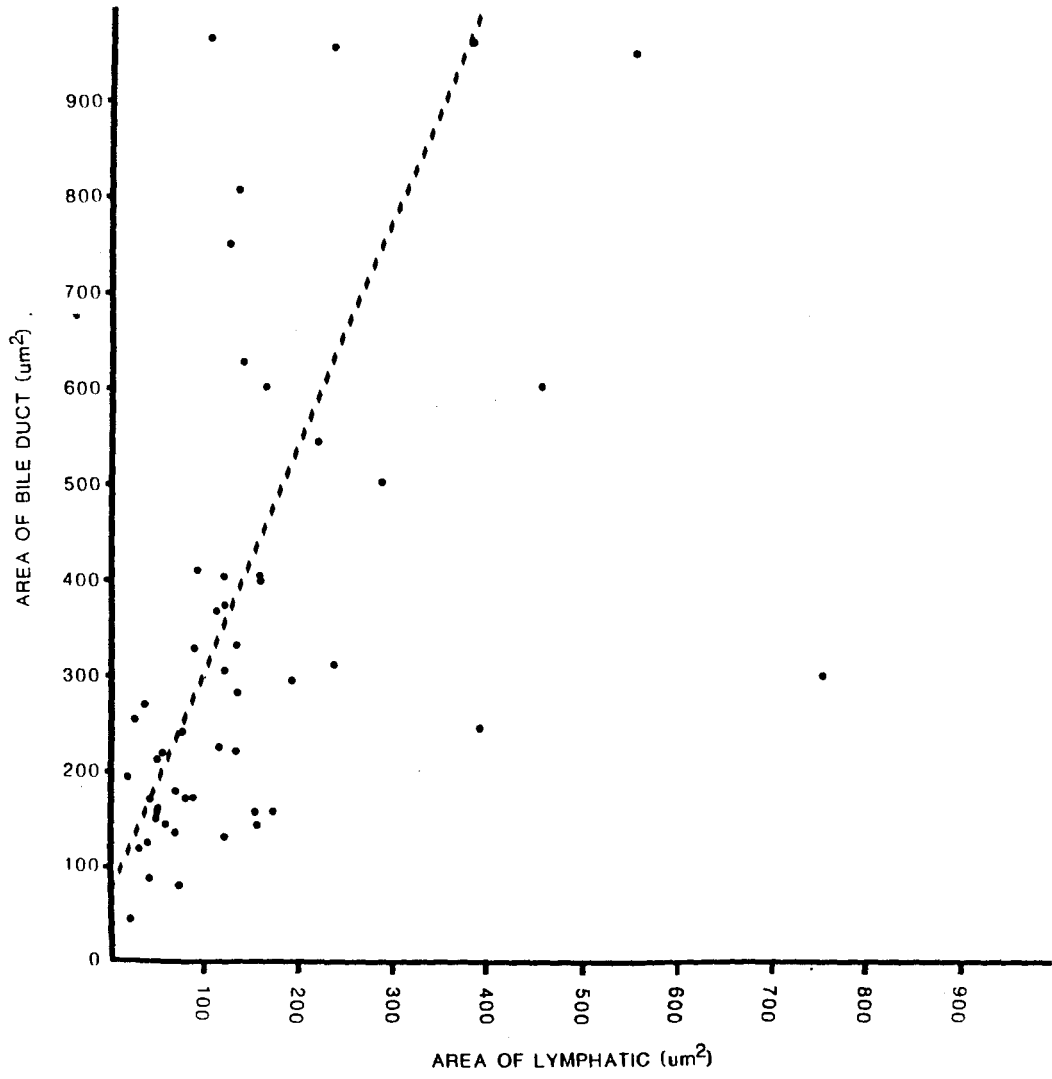


Table I: FREQUENCY OF HEPATIC LYMPH VESSELS

<u>PC</u>	<u>PC WITH LY</u>	<u>PC WITHOUT LY</u>	<u>PC WITHOUT LY AND W/O HA</u>	<u># OF LY</u>
120	62(51.7%)	58(48.3%)	31	95

**abbreviations:**

PC - PORTAL CANALS

LY - LYMPHATICS

HA - HEPATIC ARTERIOLE

Table II: SIZE OF VESSELS IN HEPATIC PORTAL CANAL

	AREA ( $\mu\text{m}^2 \pm \text{SEM}$ )	MAXIMUM DIAMETER ( $\mu\text{m} \pm \text{SEM}$ )
LYMPHATIC	223.2 $\pm$ 48.7	20.5 $\pm$ 2.0
BILE DUCT	585.8 $\pm$ 123.7	30.8 $\pm$ 2.8
HEPATIC ARTERIOLE	552.0 $\pm$ 116.6	27.1 $\pm$ 2.5

N = 56

### Discussion

Previous studies on the intrahepatic lymph system have employed techniques that have been criticized for creating artifacts that can lead to misinterpretation of results (Rusznyak et al., 1967). For example, Elias (1949b) used injection of India ink. Although, he does not describe what type of injections he used, both stab injection and retrograde injection require high pressure that may result in the creation of artificial spaces or rupture of lymphatics. Magari et al. (1979) employed the resin casting method for demonstrating the three-dimensional arrangement of the hepatic lymph system. Cast preparations are difficult to interpret because non-vascular structures are removed and so normal relationships are lost. Furthermore, because Magari and co-workers (1979) used retrograde injection of the casting material, they may have identified extravasated resin as lymphatic vessels. Others have employed electron microscopy (Fujikawa and Magari, 1975; Schatzki, 1978) but these studies do not describe the full pattern and extent of lymphatics within the liver. A more methodical approach was used by Comparini (1969) who examined serial sections by light microscopy. However, identification of lymphatics solely by light microscopy is difficult, at best (Rusznyak et al., 1967; Huth and Bernhardt, 1977; O'Morchoe, 1984). The technique employed in the present work permitted the systematic study of large lengths of ultrastructurally verified lymphatics by light microscopy. Intrahepatic lymph vessels were not difficult to identify because their

ultrastructure is similar to that of lymphatics elsewhere in the body (Leak, 1984).

The morphological picture obtained in the present study brings into serious question the idea that the space of Disse is the primary source of macromolecules and fluid that contribute to hepatic lymph. There are several reasons. First, the space of Disse is separated from initial lymphatics by at least a plate of hepatocytes and the space of Mall. These potential obstacles may prevent fluid and, especially, macromolecules from reaching initial lymphatics. Second, because of this physical separation and distance involved, the composition of the fluid that finally reaches the initial lymphatics may be quite different from that in the space of Disse. The limiting plate of hepatocytes, the space of Mall and the interstitium of the portal canal, one of these or all, may influence to some degree the composition of fluid that contributes to hepatic lymph. Although some investigators cite the high protein content of hepatic lymph as evidence that fluid in the space of Disse is the source of hepatic lymph, in fact, the protein content of hepatic lymph might be expected to be even closer to that of plasma. Third, because of their proximity to lymphatics, blood capillaries in the portal canals cannot be discounted as possibly providing a significant contribution to hepatic lymph.

In comparison to the rat renal cortical lymphatic system (Niro et al., 1985), the intrahepatic system had a similar volume density ( $0.00098 \mu\text{m}^3/\mu\text{m}^3$  in the liver versus  $0.0011$  in the perfusion fixed kidney) but a significantly smaller profile density ( $1.8 \text{ lymphatics}/\text{mm}^2$

in the liver versus 5.6 in the perfusion fixed kidney,  $p < .001$ ). Thus, the typical cross-section of rat kidney contains more numerous but on the average smaller lymphatics than a cross-section of rat liver. This situation can be explained by the fact that the renal system consists of both interlobular vessels and smaller intralobular vessels while only interlobular vessels exist in the liver. Renal interlobular vessels measured  $235.5 \mu\text{m}^2$  in cross-sectional area compared to hepatic interlobular vessels which measured  $232.2 \mu\text{m}^2$ . Renal intralobular vessels measured  $77.9 \mu\text{m}^2$  in cross-sectional area.

From data obtained in this study and previous measurements on the rate of hepatic lymph flow by Lee (1984), the rate of lymph formation in the liver can be estimated. In terms of volume of lymph per time per unit area of lymphatic endothelium, this rate is equal to the flow of lymph ( $0.66 \text{ ml}/100 \text{ g liver/hr}$ , Lee, 1984) divided by the lymphatic surface area. The lymphatic surface area can be estimated in two ways. The first is according to the equation:  $S_v = (4 \times B_A)/\pi$  (Weibel, 1973); where  $B_A$  is defined as the length of all profiles (in our case lymphatics), per unit area. For hepatic lymph vessels,  $B_A$  is equal to the average perimeter ( $58.1 \mu\text{m}$ ) times the profile density ( $1.8 \text{ lymphatics}/\text{mm}^2$ ). Thus,  $S_v$  of lymphatic endothelium is  $0.00013 \mu\text{m}^2/\mu\text{m}^3$  which can be re-expressed as  $1.3 \text{ cm}^2/\text{g liver}$ , if the density of liver is assumed to be one ( $1 \text{ g}/\text{cm}^3$ ). The second method of estimating the lymphatic surface area is that used by O'Morchoe et al. (1982). According to these investigators, the lymphatic surface area is equal to  $(2 \times V)/r$ , where  $V$  is the volume occupied by lymphatics and  $r$  is the

average lymphatic radius. For the present calculation, the volume occupied by hepatic lymph vessels is  $0.00098 \text{ cm}^3/\text{g}$  liver, assuming that the density of the liver is again  $1 \text{ g/cm}^3$ , and the average radius is  $0.001 \text{ }\mu\text{m}$ . The lymphatic surface area is, thus, about  $2.0 \text{ cm}^2/\text{g}$  liver. Finally, based on the two methods of calculating the lymphatic surface area, the rate of lymph formation in the liver of the rat is approximately  $0.06$  to  $0.08 \text{ }\mu\text{l/min/cm}^2$  of lymphatic endothelium. In comparison, rates of  $1 \text{ }\mu\text{l/min/cm}^2$  have been estimated for lymphatics of the canine kidney (O'Morchoe et al., 1982) and  $0.3$  to  $0.4 \text{ }\mu\text{l/min/cm}^2$  for vessels of the rat kidney (Niiro et al, 1985).

In contrast to Comparini's (1969) report of "central lymphatics" next to sublobular (intercalated) veins, such vessels were not found in the present study. Although we do not dispute the existence of lymphatics associated with the hepatic vein or its larger tributaries, we cannot agree with Comparini's description. Cleft-like spaces next to sublobular veins were observed by light microscopy but, electron microscopy revealed that these spaces lacked an endothelial lining. Since Comparini's (1969) study on human liver relied solely on light microscopy, it is possible that he may have mistaken such clefts for lymphatics. The origin of lymphatics associated with the hepatic veins requires further study, thus, it is our conclusion that they do not start at the level of the intercalated vein.

It was concluded that (1) lymphatics in the rat liver are confined to the portal canals and probably originate within these connective tissue areas; (2) the concept that the space of Disse is the source of

macromolecules and fluid that forms hepatic lymph requires serious reconsideration; and (3) the rate of lymph formation in the liver of the rat is approximately 0.06 to 0.08  $\mu\text{l}/\text{min}/\text{cm}^2$  of lymphatic endothelium.



## CHAPTER VI

### AN ULTRASTRUCTURAL STUDY ON THE TRANSENDOTHELIAL PATHWAYS FOR LYMPH FORMATION IN THE LIVER OF THE RAT

#### Abstract

Hepatic lymph vessels in the rat were examined by qualitative and quantitative analyses in order to obtain data pertinent to the mechanism of lymph formation. The ultrastructurally visible transport pathways across these vessels appeared to be by way of intracytoplasmic vesicles (89.6  $\mu\text{m}$  mean diameter) and normal channels (22.6  $\mu\text{m}$  wide) between endothelial cells. Three types of intercellular contacts were seen, end-to-end, overlapping, and interdigitating. Only one open junction (>30 nm) was seen in 226 contacts examined. Specialized junctional complexes, either fasciae occludentes or fasciae adherentes, were seen in 65% of the contacts. Approximately one-third of the contacts had a dilation along part of their length separating the opposing endothelial cells. Vesicles occupied 3.5% of the endothelial cytoplasmic volume and were distributed as follows: 40% opening onto or touching the luminal membrane, 34% without visible connection to either surface, 23% opening onto or touching the abluminal membrane, and less than 3% associated with membranes forming intercellular contacts. The transport pathways

observed in the present study were similar to routes seen in renal lymphatics of the dog (Albertine and O'Morchoe, 1980a, 1981) and rat (Yang et al., 1981), but were different from those seen in dermal (Leak and Burke, 1966, 1968) or diaphragmatic vessels (Casley-Smith, 1964), where open junctions appear to be of greater importance. It was concluded that the mechanism of lymph formation in the liver is similar to that in the kidney and different from that in the dermis or diaphragm.

#### INTRODUCTION

The movement of macromolecules from interstitium to lymph can occur, according to morphological studies, by one or both of two transendothelial routes. One is the potential pathway provided by the intracytoplasmic vesicular system (Dobbins and Rollins, 1970; Jones et al., 1983; O'Morchoe et al., 1984); the other comprises the space that intervenes between adjacent endothelial cells. This space may appear in electron micrographs either as normal intercellular channels of about 15 to 20 nm wide (Albertine and O'Morchoe, 1980a; 1981; Yang et al., 1981) or as larger gaps of more than 30 nm, commonly referred to as open junctions (Leak and Burke, 1966, 1968; Casley-Smith, 1977). The relative preponderance of these two forms of intercellular space has implications for the way that lymph is formed. The presence of open junctions, as a major pathway favors the view that lymph formation is primarily an intercellular phenomenon (Casley-Smith, 1977). Such is apparently the case in lymph vessels of the dermis (Leak, 1966, 1976)

and the diaphragm (Casley-Smith, 1964). In contrast, these open junctions are rarely seen in renal cortical lymphatics (Albertine and O'Morchoe, 1980a, 1981; Yang et al., 1981) suggesting that the intercellular route is of less importance in the kidney. In an attempt to reconcile these disparate observations, Casley-Smith (1982) postulated that initial lymphatics functioned in two modes depending upon the local tissue hydrostatic pressure. He suggested that in encapsulated organs, like the kidney where tissue hydrostatic pressure is considered to be higher than atmospheric, fluid enters the lymphatics continuously through intercellular channels down a pressure gradient. In contrast, in regions where interstitial pressure is subatmospheric, fluid enters lymphatics intermittently (force pumps) and so may require potentially wider spaces between cells. Studies by Albertine and O'Morchoe (1980a, 1981), Yang et al. (1981) and O'Morchoe et al. (1984) indicate that the vesicular system plays an important role in lymph formation, especially where open junctions are not present.

The primary purpose of the present study was to examine the transport pathways across hepatic lymph vessels in the rat by qualitative and quantitative analyses. The liver was chosen because it, as Casley-Smith (1982) suggests, is similar to the kidney in that both organs are enclosed by a connective tissue capsule and so are thought to have a positive tissue hydrostatic pressure. Thus, hepatic vessels might be expected to bear a structural similarity to renal lymphatics rather than to dermal or diaphragmatic vessels, at least as far as intercellular junctions are concerned. The endothelial vesicular system

was also studied quantitatively. According to the most widely accepted theory of lymph formation in the liver (Rusznyak et al., 1967; Yoffey and Courtice, 1970), hepatic lymph is principally derived from protein-rich interstitial fluid from the space of Disse. If protein stimulates an increase in the apparent number of vesicles as suggested by Yang et al. (1980), hepatic vessels might be expected to have a prominent vesicular system.

### Materials and Methods

Livers of eight male Sprague-Dawley rats (Harlan), weighing 225-330 g (mean wt. = 273 g) and anesthetized with intraperitoneal sodium pentobarbital (50 mg/kg body weight), were fixed by vascular perfusion through the portal vein. The portal vein was cannulated (PE 90) through a ventral midline incision. A one-liter bottle containing heparinized physiologic saline and another one-liter bottle containing 2% glutaraldehyde in .16 M sodium cacodylate buffer, pH 7.4 were connected to the cannula with a three-way stopcock. Tributaries to the portal vein were ligated. The perfusion was initiated with saline for 30 seconds or until the livers blanched and then switched to fixative. Immediately after the perfusion was started, the vena cava caudalis was cut and the celiac artery clamped. Perfusion continued for approximately 15 minutes, during which, 100-150 ml of fixative were used. A perfusion pressure of 40 mm Hg was maintained throughout the

procedure. At the end of the perfusion, the livers were light brown in color and firm to the touch.

The perfused livers were excised and 2x2 mm blocks of well-fixed tissue were immersed for an additional hour in 2% glutaraldehyde, post-fixed for one hour in 1% osmium tetroxide, dehydrated in acetone and embedded in epoxy resin (Kushida, 1971). Thin sections were cut, stained with uranyl acetate and lead citrate and examined with a Hitachi H600 electron microscope.

The frequency of three types of intercellular contacts - end-to-end, overlapping and interdigitating, as well as evidence of the so-called "open" (> 30 nm wide) junction was manually tabulated from the micrographs. The presence of specialized junctional complexes and dilations within the intercellular contacts were also recorded. For quantification of the vesicular system, forty lymphatics, five from each of the eight livers, were examined. For each lymphatic, 10 random micrographs were taken and printed at a final magnification of 58,700X. The following parameters were measured from the micrographs using a Zeiss Videoplan image analyzer: 1) maximum and minimum non-nuclear endothelial thickness, and 2) mean maximum diameter, volume and numerical densities of small uncoated endocytotic vesicles. The distribution of the vesicles was also determined by assigning each one to a category on the basis of whether it touched the luminal, abluminal or junctional membrane or whether it appeared to lie free within the cytoplasm.

## Results

Lymphatics showing a typical ultrastructural appearance were found within the connective tissue of portal canals. The endothelial lining was thin, non-fenestrated and lacked a continuous basal lamina (Fig. 1). Fine anchoring filaments and collagen fibrils connected the endothelial wall to the interstitium. The cytoplasmic organelles included mitochondria, rough endoplasmic reticulum, lysosomes and vesicles, being generally comparable to those in lymphatic endothelium elsewhere in the body.

Three morphological types of intercellular contacts were seen, end-to-end, overlapping and interdigitating (Fig. 2). Table I demonstrates the relative frequency of each type of contact. Only one "open" type junction having a gap greater than 30 nm was seen. Specialized junctional complexes, either fasciae occludentes (tight junctions) or fasciae adherentes (intermediate junctions), were associated with 147 (65.0%) intercellular contacts (Fig. 3). In 65 (28.8%) contacts it was not possible to determine whether or not a junctional complex was present due to the plane of section. Junctional complexes were absent in 14 (6.2%) contacts. The average width of the intercellular channel was  $22.6 \text{ nm} \pm 0.4$  (SEM) although dilations (Fig. 4) were present in 74 (32.7%) contacts.

The endothelium measured at non-nuclear areas was  $0.1 \text{ } \mu\text{m} \pm 0.004$  (SEM) at its minimum thickness and  $0.5 \pm 0.02 \text{ } \mu\text{m}$  at its maximum. Within the cytoplasm, coated and uncoated endocytotic vesicles were observed.

The larger vesicles (200-400 nm in diameter) had a fuzzy coating and were infrequently seen. The coated vesicles were not analyzed further. The distribution, volume density, numerical density and mean diameter of the small uncoated vesicles are given in Table II. A greater number of uncoated vesicles were associated with the luminal surface of the endothelium than the abluminal surface. Approximately one third of the vesicles appeared to lie free within the endothelial cytoplasm. A small percentage of vesicles were distributed along intercellular contact surfaces of the cell. The volume and numerical density data also reflect a higher proportion of vesicles associated with the luminal surface.

Figure 1. Electron micrograph of part of a hepatic lymph vessel. The endothelium (E) lacks a basal lamina, however, collagen fibrils (C) and fine anchoring filaments (arrows) are intimately related to the abluminal surface. The lymphatic lumen (L), a fibroblast (F), and smooth muscle (M) are also seen. X14,400.



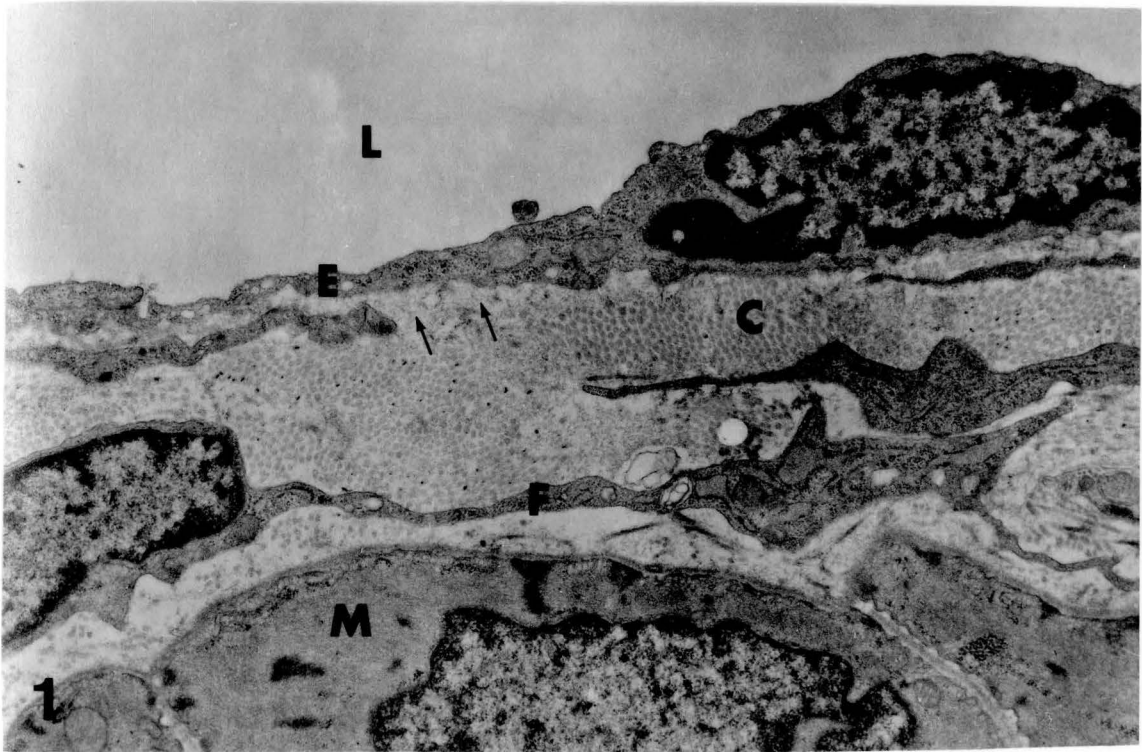


Figure 2. The three types of intercellular contacts (arrowheads): (a) end-to-end; (b) overlapping; and (c) interdigitating. The lymphatic lumen (L) and small uncoated vesicles (v) are also seen. X56,000.

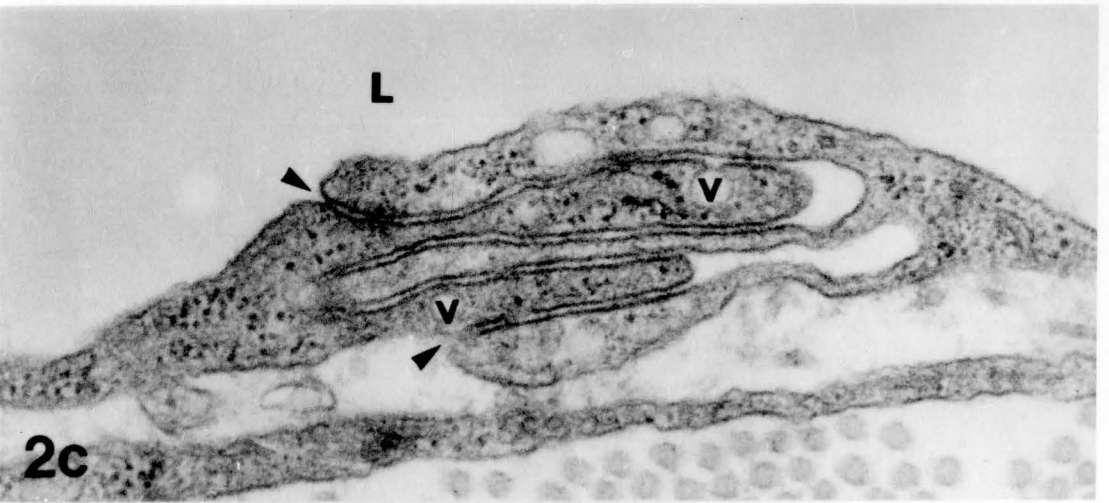
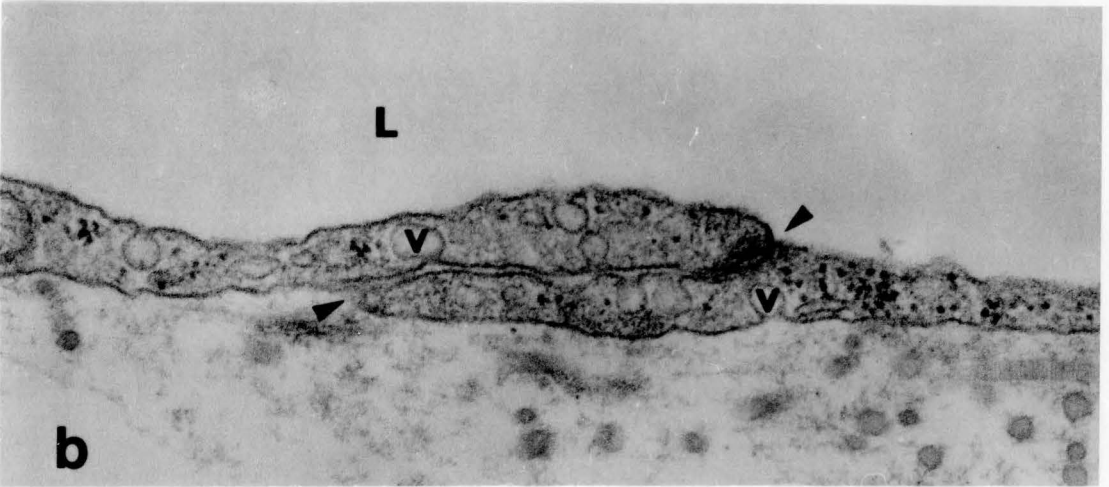
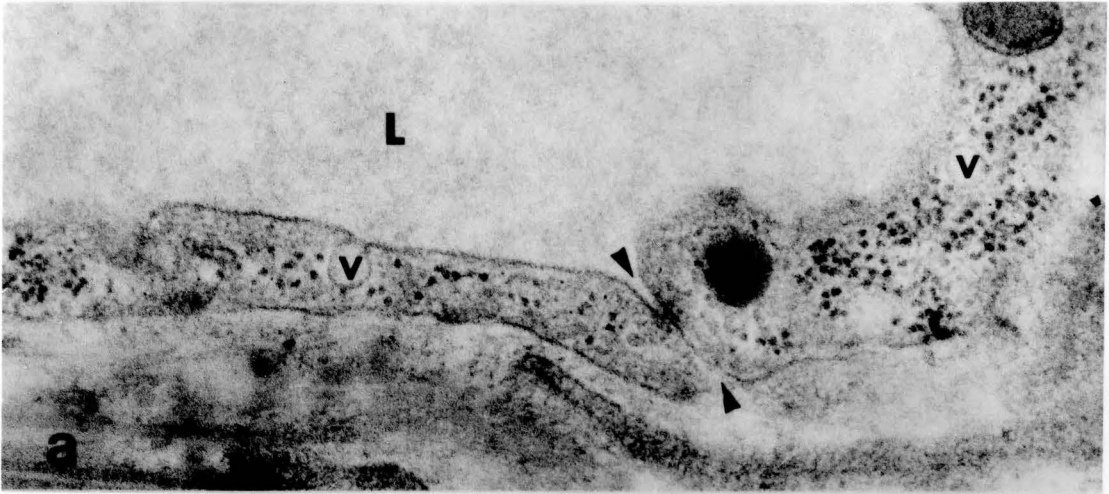


Figure 3. Electron micrograph of a specialized junctional complex within an interdigitating type of intercellular contact. A fascia occludens (large arrowheads) and a fascia adherens (small arrowheads) are seen between two contiguous endothelial cells. Numerous small uncoated vesicles (v) are present within the cytoplasm. X86,000.

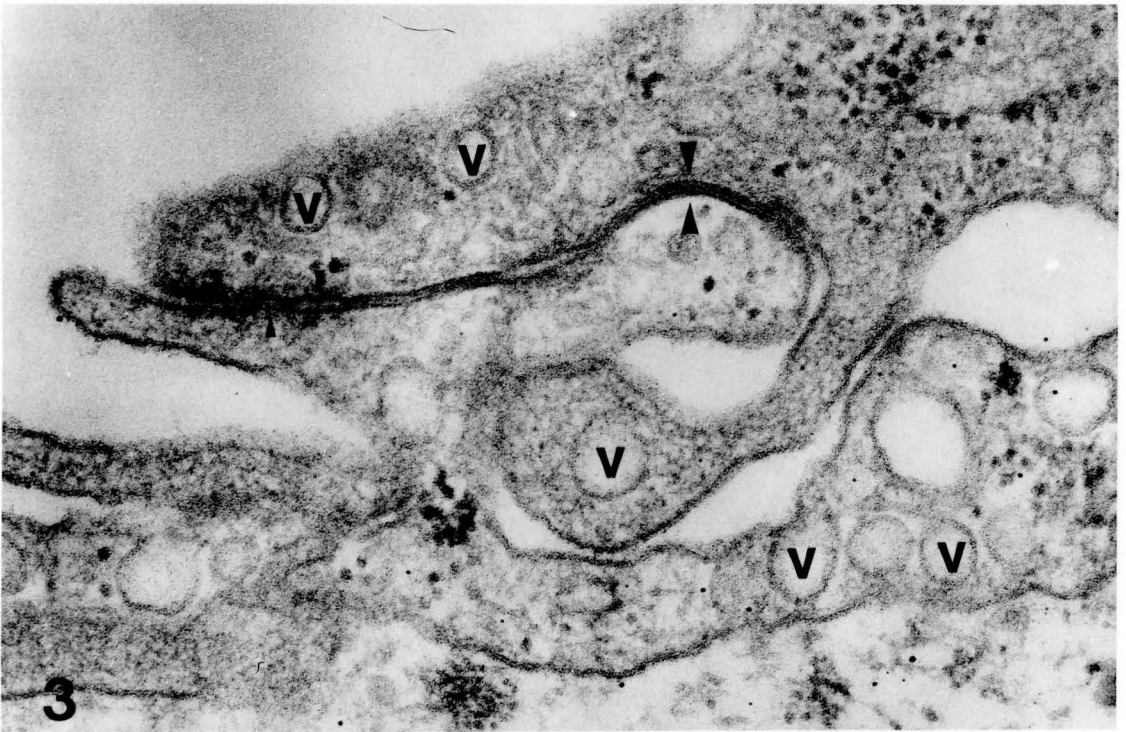

Figure 4. Dilations (\*) within the three types of inter-cellular contacts (arrowheads): (a) end-to-end; (b) overlapping; and (c) interdigitating. The lymphatic lumens (L) and small uncoated vesicles (v) are also seen. X65,000.

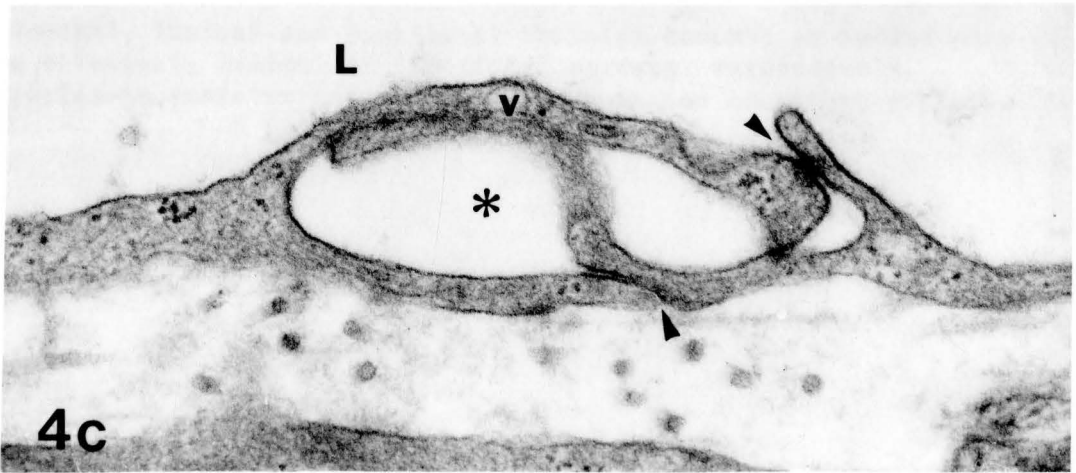
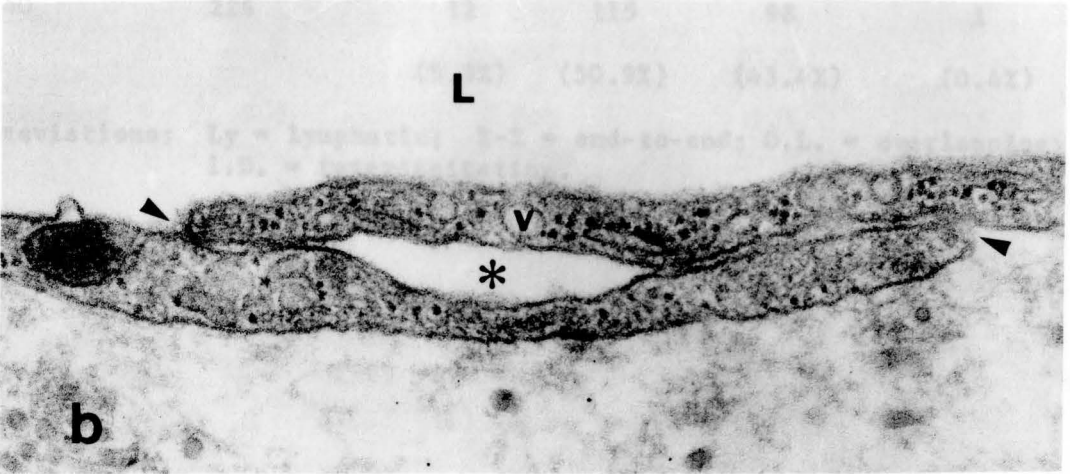
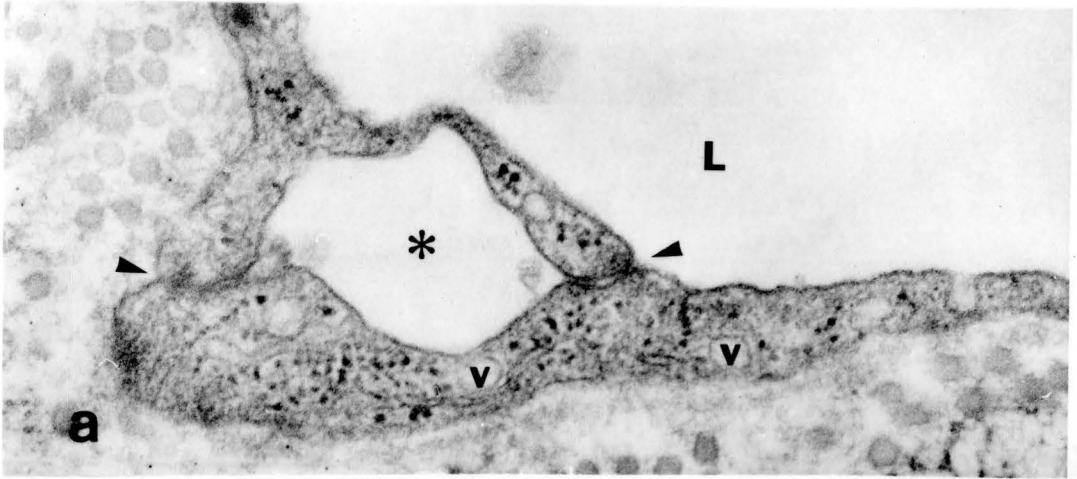


Table I: INTERCELLULAR CONTACTS

<u>No. Ly</u>	<u>No. Contacts</u>	<u>E-E</u>	<u>O.L.</u>	<u>I.D.</u>	<u>OPEN (&gt;30nm)</u>
40	226	12	115	98	1
		(5.3%)	(50.9%)	(43.4%)	(0.4%)

Abbreviations: Ly = lymphatic; E-E = end-to-end; O.L. = overlapping;  
I.D. = interdigitating.



Table II: DISTRIBUTION AND MORPHOMETRY  
OF ENDOCYTOTIC VESICLES

	Distribution <sup>1</sup> (%)	$V_V$ ( $\mu\text{m}^3/\mu\text{m}^3$ )	$N_V$ ( $\#/ \mu\text{m}^3$ )	D (nm)
Abluminal	22.5 <u>+1.3</u>	0.009 <u>+0.001</u>	17.9 <u>+2.0</u>	90.6 <u>+0.2</u>
Cytoplasmic	34.0 <u>+2.2</u>	0.013 <u>+0.001</u>	23.2 <u>+2.0</u>	93.6 <u>+0.2</u>
Luminal	40.9 <u>+2.0</u>	0.014 <u>+0.001</u>	29.9 <u>+3.0</u>	91.3 <u>+0.2</u>
Junctional	2.8 <u>+0.4</u>	0.001 <u>+0.0002</u>	2.3 <u>+0.4</u>	88.0 <u>+0.2</u>
TOTAL (3028 vesicles)	100% <u>+0.035</u>	0.035 <u>+0.003</u>	74.6 <u>+6.2</u>	89.6 <u>+0.1</u>

Abbreviations:  $V_V$  = volume density;  $N_V$  = numerical density;  
D = mean diameter.

Data is expressed as mean  $\pm$  SEM of 40 lymphatics.

<sup>1</sup> Abluminal, luminal and junctional vesicles touched or opened onto the abluminal, luminal or junctional surface, respectively. Cytoplasmic vesicles had no obvious connection to either surface.

Discussion

The major routes of translymphatic transport in renal lymphatics of the dog (Albertine and O'Morchoe, 1980a, 1981) and rat (Yang et al., 1981) are provided by normal intercellular channels and intracytoplasmic vesicles. In the present study, qualitatively and quantitatively similar pathways were observed in hepatic lymph vessels of the rat. Like renal lymphatics, hepatic vessels possessed principally three types of intercellular contacts that are held together by specialized junctional complexes. In contrast, the incidence of open junctions, a major thoroughfare across lymphatics of the dermis (Leak and Burke, 1966, 1968) and diaphragm (Casley-Smith, 1964) was found to be extremely low as it is in renal vessels (Albertine and O'Morchoe, 1980a, 1981; Yang et al., 1981). Also, the average width of intercellular channels (22.6 nm) measured in the present study resembled that found in renal vessels (5 - 30 nm). Although some of the contacts possessed dilations, these spaces never completely separated adjacent endothelial cells. Whether these dilations represent patent clefts for transport like those in intestinal lymphatics (Azzali, 1982a,b) is unclear from the present study.

The other major pathway in renal lymphatics, the vesicular system, was a prominent feature of hepatic vessels. Their volume density in hepatic lymph vessels (3.5%) is similar to that in rat renal cortical (2.8%, Yang et al., 1981) and canine renal cortical lymphatics (3.0% - 4.9%, Albertine and O'Morchoe, 1980a). The distribution of these

vesicles is also like that of some renal vessels. For example, the percentage of vesicles without a visible connection to either luminal or abluminal surface was 34% in hepatic vessels in comparison to 43% in arcuate, 31% in interlobar, 38% in hilar and 36% in capsular lymphatics of the canine kidney (Albertine and O'Morchoe, 1981). A higher percentage of apparently free vesicles was seen in cortical lymphatics of the dog (62%, Albertine and O'Morchoe, 1980a) and rat (64%, Yang et al., 1981).

Two of the three principal theories of lymph formation require the presence of large intercellular clefts which are open at least part of the time. The hydrostatic and oncotic pressure theory postulate that lymph is formed on a cyclical basis through these large openings. On the other hand, the third theory holds that transport by the vesicular system represents a major pathways across lymphatics and does not require the existence of large gaps between endothelial cells. The vesicular theory was advanced to account for a component of the macromolecular transport in the kidney where open junctions are rare. By the same reasoning and evidence presented here, vesicular transport may be largely responsible for lymph formation in the liver as well. Vesicular movement of molecules is an especially attractive concept in the liver for two reasons. First, the transport of protein by vesicles, at least in blood capillaries, has been suggested by many (e.g., see review by Wagner and Casley-Smith, 1981) and hepatic lymph contains a relatively high percentage of protein (Barrowman, 1978; Lee, 1984). Secondly, if hepatic lymph is indeed formed by vesicles, this finding

would support Casley-Smith's theory that the mechanism of lymph formation in the liver and kidney is comparable, yet different from that elsewhere in the body.

An obvious question which arises from this work is whether or not perfusion fixation had either a qualitative or quantitative effect on the observed transport pathways. If perfusion had caused edema or other trauma (no morphological evidence of edema was seen), an increase in the frequency of open junctions might have been expected (O'Morchoe et al., 1980; Leak, 1984). However, since only one was seen, it appears the intercellular contacts were not affected by perfusion. Likewise, the presence of dilations, although unexpected, has been previously reported in immersion-fixed tissue (Azzali, 1982a; O'Morchoe, 1984). The effects of perfusion fixation on the vesicular system are less clear. Not only is the discreteness of the plasmalemmal vesicles themselves questioned (Bundgaard et al., 1983; Jones et al., 1983), but Mazzone and Kornblau (1981) detected considerably more vesicles in blood capillaries of rabbit lungs fixed by vascular perfusion than after rapid freezing. Therefore, the volume density of endothelial vesicles may, in fact, be lower than the 3.5% found in the present study.

In conclusion, the present study provides morphological evidence that the mechanism of lymph formation in the liver is similar to that in the kidney but unlike that found in the dermis or diaphragm. If lymph can be formed in more than one way, the conflicting theories of lymph formation, presently advanced, may be equally valid depending on local factors. These factors include tissue hydrostatic pressure

(Casley-Smith, 1982), interstitial protein (O'Morchoe et al., 1984), and edema induced by local trauma (Casley-Smith, 1965; O'Morchoe et al., 1980).

## CHAPTER VII

### DISCUSSION

Traditional methods of tracing the distribution of lymphatic vessels in organs like the kidney and liver have limited application and their use can lead to conflicting results. For example, two commonly used techniques, stab and retrograde injection of tracer are criticized because of their potential for creating artifacts that can be mistaken for lymphatics. Preparation of serial sections, although tedious and time consuming, and their study by light microscopy is, perhaps, the most suitable means of determining the extent of lymphatics in organs. However, without electron microscopic examination, positive identification of lymphatic vessels is difficult. The current study demonstrates that the distribution of lymphatics in the kidney and liver can be determined by this combined use of light and electron microscopy. Furthermore, by reembedding thick sections, so that they can be retrimmed and recut for electron microscopy, quantitative as well as qualitative data can be retrieved from the same set of tissue sections. In the present study, volume density and profile density of lymphatic vessels were determined by this method.

The morphologic description of the pattern and distribution of lymphatics provided by this study has different implications for the

kidney and liver. An intralobular lymphatic network was demonstrated in the kidneys of rats and hamsters. These initial lymphatics were seen not only in relationship to afferent arterioles but also close to renal tubules and unrelated to arteries and veins. Only a small interstitial space and the basal lamina of renal tubule cells separated the lymphatics from tubules. These findings suggest that renal lymph has a tubular component, at least in some species. They corroborate previous morphological reports on the dog (Albertine and O'Morchoe, 1979) and evidence based on the composition of renal lymph (O'Morchoe et al., 1975). Furthermore, that intralobular lymphatics were not found in the rabbit is consistent with the results obtained by Gartner et al. (1973) and Vogel et al. (1974). These investigators, utilizing a functional approach, concluded that tubular reabsorbate does not contribute to renal lymph, at least, in the rabbit. The morphological evidence obtained in the present study strongly supports this conclusion.

On the other hand, an intralobular network of lymphatics was not observed in the liver. The initial lymphatics appeared to begin in the portal canals. If macromolecules and fluid in the space of Disse is the source of hepatic lymph, it must first pass around the limiting plate of hepatocytes, through Mall's space and through the portal canals to reach the initial lymphatics. Because of this lengthy route, the composition of the fluid finally reaching the lymphatics may be very different from that in the space of Disse. Also, the proximity of initial lymphatics to blood vessels of the portal canals suggest that serious consideration must be given to the latter as a prime source of fluid that contributes

to lymph formation. Thus, the concept that macromolecules and fluid in the space of Disse is the principal source of hepatic lymph needs to be re-examined in light of the present study.

The quantitative data obtained in this study (Table I) provide new insight on the extent of the renal and hepatic lymph systems. These data indicate that the lymphatic volume density of the canine and rat kidney and that of the rat liver are reasonably comparable. Lymphatics occupy about 0.1% of the total volume in these organs. However, the hamster kidney has a much more extensive lymphatic system ( $V_V = 0.37\%$ ). Thus, significant species differences appear to exist. The data obtained for the rate of lymph formation in the rat kidney and liver are new and have not been found for lymphatics of any organ except for that in the dog kidney (O'Morchoe et al., 1982). The rates predicted in the present study (0.3 to 0.4  $\mu\text{l}/\text{min}/\text{cm}^2$  in the kidney and 0.06 to 0.08  $\mu\text{l}/\text{min}/\text{cm}^2$  in the liver) appear to be reasonably consistent with that previously found in canine renal lymphatics (1  $\mu\text{l}/\text{min}/\text{cm}^2$ ) by O'Morchoe et al. (1982). Critics of this study may argue that morphometric analyses of structures as sparse as lymphatics are subject to large errors. However, until more accurate techniques become available, data obtained in this study provide reasonable working estimates.

Comparison of the ultrastructure of renal cortical and hepatic lymphatics demonstrate that the two are very much alike. In particular, open junctions are a rare occurrence in both renal and hepatic vessels. In other organs (e.g., dermis and diaphragm), open junctions are an important pathway for lymph formation. But, in view of two current



theories of lymph formation, it should not be surprising that open junctions exist in these tissues. Both the hydrostatic pressure theory and oncotic pressure theory postulate that alternating compression and relaxation provide the necessary mechanism for the formation of lymph via open junctions. Certainly, these cyclical events are present in the diaphragm and most likely in the dermis due to the movement of adjacent musculature. However, the kidney and liver because they are enclosed by a capsule are not subjected to a significant extent to alternating periods of compression and relaxation except for that due to arterial pulsation. Thus, it is reasonable to assume that the hydrostatic pressure theory and oncotic pressure theory are not applicable to the kidney or liver and that open junctions should not be expected in renal and hepatic lymph vessels.

What, then, is the mechanism of lymph formation in the liver? Studies by Albertine and O'Morchoe (1980a, 1981), Yang et al. (1981) and O'Morchoe et al. (1984) indicate that as much as 50% of protein entering renal lymph may be transported by the vesicular system. The main evidence is twofold. The first is that protein tracers like horseradish peroxidase and ferritin enter endocytotic vesicles and appear to be transported lumenally. The second is that protein transport to some extent is temperature dependent which suggests a cytoplasmic process. Whether discrete vesicles or transendothelial channels are responsible for protein transport is not known but either is consistent with the vesicular theory of lymph formation. The present study demonstrates that hepatic lymphatics are structurally like renal vessels. The

hepatic vessels have numerous vesicles and normal intercellular channels and lack open junctions. These findings indicate that the mechanism of lymph formation in the liver is the same as that in the kidney.

In conclusion, the lymphatic system of the kidney and liver have structural parallels which indicate that the mechanism of lymph formation is the same in each and different from that found elsewhere in the body. Whether these differences indicate a special role for lymphatics of the kidney and liver is unknown. O'Morchoe (1982) has suggested that renal lymph may not have a special role in renal function. Its purpose in the kidney is similar to that of lymph within the rest of the body, returning fluid and macromolecules to the blood circulation. However, he adds, that because the kidney receives 20% - 25% of cardiac output and is enclosed by a capsule, minor fluctuations in the flow and pressure of blood can lead to major changes in the balance of tissue fluid. Thus, O'Morchoe (1982) concludes that the role of lymphatics in control of renal interstitial homeostasis may be more important than in other organs. The current study suggests that the situation in the liver is like that in the kidney. The liver also receives a large regional blood flow, is also surrounded by a capsule, and is drained by a lymphatic network that is qualitatively and quantitatively similar to that in the kidney. Thus, it is reasonable to suppose that the lymphatic system of the liver plays a significant role in interstitial fluid dynamics.

**Table I: COMPARISON OF PERFUSION-FIXED RENAL  
AND HEPATIC LYMPH SYSTEMS OF THE RAT**

	<u>Kidney</u>	<u>Liver</u>
Volume Density ( $\mu\text{m}^3/\mu\text{m}^3$ )	0.0011	0.00098
Profile Density ( $\#Ly/\text{mm}^2$ )	5.3	1.8
Surface Density ( $\mu\text{m}^2/\mu\text{m}^3$ )	0.00035	0.00013
Maximum Diameter Lymphatics ( $\mu\text{m}$ )	20.4 - inter 12.2 - intra	20.5 - inter
Width of Intercellular Channels (nm)	16 - 18 <sup>1</sup>	22.6
Open Junctions	rare <sup>1</sup>	rare
Vesicle Volume Density ( $\mu\text{m}^3/\mu\text{m}^3$ )	0.028 <sup>1</sup>	0.035
Vesicle Numerical Density ( $\#Ves/\mu\text{m}^3$ )	16 <sup>1</sup>	75
Maximum Vesicle Diameter (nm)	80 - 100 <sup>1</sup>	89.6
Calculated Rate of Lymph Formation ( $\mu\text{l}/\text{min}/\text{cm}^2$ endothelium)	0.3 - 0.4	0.06 - 0.08

<sup>1</sup> Yang et al., 1981, kidneys were dripped-fixed

Abbreviations: Ly - Lymphatic, Ves - Vesicles,  
Inter - Interlobular lymphatic  
Intra - Intralobular lymphatic

## CHAPTER VIII

### SUMMARY AND CONCLUSIONS

A. The findings in the kidney were:

1) Lymphatics, situated within the renal lobule and primarily related to afferent arterioles and tubules, were observed in the kidneys of rat and hamster, but not rabbit. The relationship between these intralobular vessels and renal tubules suggests that a tubular reabsorbate contribution to renal lymph in the rat and hamster is likely.

2) In terms of lymphatic vessel size and density, the hamster kidney has the richest lymphatic system. It was poorest in the rabbit and intermediate in the rat. Kidneys of rats fixed by vascular perfusion appear to have a more extensive lymphatic system than kidneys fixed by dripping. It was concluded that: a) significant species differences exist which may be related to urinary concentrating capacity; b) the method of fixation influenced the measured size and density of renal cortical lymphatics; and c) the rate of lymph formation in the perfusion fixed rat kidney is approximately 0.3 to 0.4  $\mu\text{l}/\text{min}/\text{cm}^2$  of lymphatic endothelium.

B. The findings in the liver were:

1) Lymphatics in the liver of rats were found in the portal canals and appeared to represent initial vessels. These lymphatics sometimes coursed very close to Mall's space, separated by a small amount of connective tissue containing sparse collagen fibrils. Lymphatics were not found in the hepatic parenchyma. It was concluded that if fluid in Disse's space contributes to hepatic lymph, it must first percolate through Mall's space and the interstitium of the portal canals to reach the initial lymphatics.

2) The lymphatic system of the liver has a comparable volume density to that of the renal lymphatic system of rats. However, because the hepatic system consists of only interlobular lymphatics and both intra- and interlobular lymphatics are found in the kidney, the profile density of hepatic vessels is less than that of renal lymphatics. It was concluded that the surface density of lymphatic endothelium is less in the liver than in the kidney. The rate of lymph formation in the rat liver is approximately  $0.06$  to  $0.08 \mu\text{l}/\text{min}/\text{cm}^2$  of lymphatic endothelium.

3) The ultrastructurally visible transport pathways across hepatic lymph vessels appear to be the same as those described in renal lymphatics. Open junctions were rarely seen. It was concluded that the mechanism of lymph formation in the liver is similar to that in the

kidney different from that in the dermis or diaphragm. In the kidney and liver, normal intercellular contacts and the vesicular system appear to have important roles in lymph formation, whereas open junctions appear to be more important in the dermis and diaphragm.

## CHAPTER IX

### BIBLIOGRAPHY

- Albertine, K.H. and C.C.C. O'Morchoe (1979). Distribution and density of the canine renal cortical lymphatic system. *Kid. Int.* 16:470-480.
- Albertine, K.H. and C.C.C. O'Morchoe (1980a). Renal lymphatic ultrastructure and translymphatic transport. *Microvasc. Res.* 19: 338-351.
- Albertine, K.H. and C.C.C. O'Morchoe (1980b). An integrated light and electron microscopic study on the existence of intramedullary lymphatics in the dog kidney. *Lymphology* 13:100-106.
- Albertine, K.H. and C.C.C. O'Morchoe (1981). An ultrastructural study of the transport pathways across the arcuate, interlobar, hilar and capsular lymphatics in the dog kidney. *Microvasc. Res.* 21: 351-361.
- Asellius, G. (1627). *De Lacteibus sive lacteis venis Quarto Vasorum Mesaroticum genere novo invente Gasp. Asellii Cremonensis Antomici Ticiensis Qua Sententiae Anatomicae multae, nel perperam receptae illustrantur. Mediolani, apud Jo. Baptistam Bidellium.* Cited by Y. Nisimaru. IN: Summary of our studies concerning the structure and function of lymphatic system. *Hiroshima J. Med. Sci.* 31:145-160, 1982.
- Azzali, G. (1982a). The ultrastructural basis of lipid transport in the absorbing lymphatic vessel. *J. Submicrosc. Cytol.* 14:45-54.
- Azzali, G. (1982b). The transendothelial transport of lipids in the absorbing lymphatic vessel. *Experientia* 38:275-277.
- Azzali, G. (1982c). Ultrastructure of small intestine submucosal and serosal-muscular lymphatic vessels. *Lymphology* 15:106-111.
- Babics, A. (1951). Lymphatic circulation of the kidneys. *Acta Med. Acad. Sci. Hung.* 2:1-20.
- Barrowman, J.A. (1978). Physiology of the Gastrointestinal Lymphatic System. Cambridge University Press, Cambridge. pp. 229-255.

- Barsky, S.H., A. Baker, G.P. Siegel, S. Togo, L.A. Liotta (1983).  
Use of antibasement membrane antibodies to distinguish blood vessel capillaries from lymphatic capillaries. *Am. J. Surg. Pathol.* 7:667-677.
- Bell, R.D., M.J. Keyl, F.R. Shrader, E.W. Jones and L.P. Henry (1968).  
Renal lymphatics: The internal distribution. *Nephron* 5:454-468.
- Bullon, A. and F. Huth (1972). Fine structure of lymphatics in the myocardium. *Lymphology* 5:42-48.
- Bundgaard, M., P. Hagman and C. Crone (1983). The three-dimensional organization of plasmalemmal vesicular profiles in the endothelium of rat heart capillaries. *Microvasc. Res.* 25:358-368.
- Burke, J.F. and L.V. Leak (1970). Lymphatic capillary function in normal and inflamed states. IN: Progress in Lymphology, vol. II, M. Viamonte, P.R. Kochler, M. Witte and C. Witte, eds. George Thieme, Stuttgart. p.81.
- Casellas D. and A. Mimran (1981). Shunting in renal microvasculature of the rat: A scanning electron microscopic study of corrosion casts. *Anat. Rec.* 201:237-248.
- Casley-Smith, J.R. (1964). Endothelial permeability. I. The passage of particles into and out of diaphragmatic lymphatics. *Quart. J. Exp. Physiol.* 49:365-383.
- Casley-Smith, J.R. (1965). Endothelial permeability. II. The passage of particles through the lymphatic endothelium of normal and injured ears. *Brit. J. Exp. Pathol.* 46:35-49.
- Casley-Smith, J.R. (1969). The dimensions and numbers of small vesicles in cells, endothelial and mesothelial and the significance of these for endothelial transport. *J. Microsc.* 90:251-269.
- Casley-Smith, J.R. (1977). Lymph and lymphatics. IN: Microcirculation, G. Kaley and B. M. Altura, eds. University Park Press, Baltimore, pp. 423-502.
- Casley-Smith, J.R. (1980). Are the initial lymphatics normally pulled open by the anchoring filaments? *Lymphology* 13:120-129.
- Casley-Smith, J.R. (1982). The fine structure and fine functioning of initial lymphatics. IN: Advances in Lymphology: Proceedings of the 8th International Congress of Lymphology. V. Bartos and J.W. Davidson, eds. Avincenum, Czechoslovak Medical Press, Prague, pp. 6-13.



- Casley-Smith, J.R. and H.W. Florey (1961). The structure of normal small lymphatics. *Quart. J. Exp. Physiol.* 46:101-106.
- Cliff, W.J. and P.A. Nichol (1970). Structure and function of lymphatic vessel of the bat's wing. *Quart. J. Exp. Physiol.* 55:112-121.
- Cockett, A.T.K., A.P. Roberts and R.S. Moore (1970). Evidence for two intrarenal lymphatic networks. *Invest. Urol.* 7:266-270.
- Collan, Y. and T.V. Kalima (1974). Topographical relations of lymphatic endothelial cells in the initial lymphatics of the intestine. *Lymphology* 7:175-184.
- Comparini, L. (1969). Lymph vessels in the liver in man. *Angiologica* 6:262-274.
- Comparini, L. and A. Bastianini (1965). Graphic reconstructions in the morphological study of the hepatic lymph vessels. *Angiologica* 2:81-95.
- Courtice, F.C. (1981). The lymphatic circulation. IN: Structure and Function of the Circulation, C.J. Schwartz, N.T. Werthessen and S. Wolf, eds. Plenum Press, New York. pp. 487-602.
- Cremer, H., N. Miller and H. Bechtelsheiner (1974). Morphological studies on the rat liver and a biochemical analysis of the serum following experimental ligation of the thoracic duct. *Lymphology* 7: 69-80.
- Cuttino, J.T. (1982). Renal medullary lymphatics: do they exist? *A.J.R.* 139: 205(abstr.).
- Deen, W.M., I.F. Ueki and B.M. Brenner (1976). Permeability of renal peritubular capillaries to neutral dextrans and endogenous albumin. *Am. J. Physiol.* 231:283-291.
- Disse, J. (1890). *Über die Lymphbahnen der Säugethierleber.* *Arch. mikrosk. Anat.* 36:203-224. Cited by J.M. Yoffey and F.C. Courtice. IN: Lymphatics, Lymph and the Lymphomyeloid Complex. Academic Press, London, 1970.
- Dobbins., W.O. and E.L. Rollins (1970). Intestinal mucosal lymphatic permeability: an electron microscopic study of endothelial vesicles and cell junctions. *J. Ultrastruc. Res.* 33:29-59.
- Elias, H. (1949a). A re-examination of the structure of the mammalian liver. I. Parenchymal architecture. *Am. J. Anat.* 84:311-333.

- Elias, H. (1949b). A re-examination of the structure of the mammalian liver. II. The hepatic lobule and its relationship to the vascular and biliary systems. *Am. J. Anat.* 85:379-456.
- Elias, H. (1963). Anatomy of the liver. IN: The liver, Ch. Rouiller, ed. Academic Press, New York. pp. 41-59.
- Evan, A.P., J.A. Stoeckel, V. Loemker and J.T. Baker (1979). Development of the intrarenal vascular system of the puppy kidney. *Anat. Rec.* 194:187-199.
- Fawcett, D.W., W.B. Neaves and M.N. Flores (1973). Comparative observation of the interstitial tissue of the mammalian testis. *Biol. Reprod.* 9:500-532.
- Fraleigh, E.E. and L. Weiss (1961). An electron microscopic study of the lymphatic vessels in the penile skin of the rat. *Am. J. Anat.* 109:85-101.
- Friedman, M., S.D. Byers and C. Omoto (1956). Some characteristics of hepatic lymph in the intact rat. *Am. J. Physiol.* 184:11-17.
- Fujikawa, K. and S. Magari (1975). An electron microscopic study of the lymph capillaries in the interlobular connective tissue of the rabbit liver. *Acta Anatomica Nipponica* 50:129-137
- Galey, F.R. and S.E.G. Nilsson (1966). A new method for transferring sections from the liquid surface of the trough through staining solutions to the supporting film of a grid. *J. Ultrastruct. Res.* 14:405-410.
- Gartner, K., E. Banning, G. Vogel and M. Ulbrich (1973). The identity of interstitial fluid and hilar lymph in the kidney. *Pflugers Arch.* 343:331-340.
- Glogengiesser, W. (1944). Experimentell-morphologische und systematische Untersuchungen über die seröse Entzündung der Leber, nebst Beiträgen experimenteller Leberschädigungen durch Bakterien, Bakterientoxine und mechanischoperative Eingriffe. *Virchows Arch.* 312:64. Cited by I. Ruzsnyak, M. Foldi and G. Szabo. IN: Lymphatics and Lymph Circulation. Pergamon Press, New York, 1967.
- Granger, H.J. (1971). Physicochemical properties of the extracellular matrix. IN: Tissue Fluid Pressure and Composition, A.R. Hargens, ed. Williams and Wilkins, Baltimore. pp. 43-62.
- Guyton, A.C. (1963). A concept of negative interstitial pressure based on pressures in implanted perforated capsules. *Circ. Res.* 12:399-414.

- Guyton, A.C., H.J. Granger and A.E. Taylor (1971). Interstitial fluid pressure. *Physiol. Rev.* 51:527-563.
- Guyton, A.C. and B.J. Barber (1980). The energetics of lymph formation. *Lymphology* 13:173-176.
- Hanstede, J.G. and P.O. Gerrits (1982). A new plastic for morphometric investigation of blood vessels, especially in large organs such as the human liver. *Anat. Rec.* 203:307-315.
- Hering, E. (1867). Ueber den Bau der Wirbeltheirleber. *Arch. mikrosk. Anat.* 3:88-114. Cited by J.M. Yoffey and R.C. Courtice. IN: Lymphatics, Lymph and the Lymphomyeloid Complex. Academic Press, London, 1970.
- Holmes, M.J., P.J. O'Morchoe and C.C.C. O'Morchoe (1977). Morphology of the intrarenal lymphatic system. Capsular and hilar communications. *Am. J. Anat.* 149:333-351.
- Huth, F., A. Wilde, H.J. Schulten, S. Berger, P. Davaris and E. Baden (1972). X-ray, light and electron microscopic observations in experimental lymphostasis of the liver. *Angiologica* 9:40-52.
- Huth, F. and D. Bernhardt (1977). The anatomy of lymph vessels in relation to function. *Lymphology* 10:54-61.
- Intaglietta, M. and J.F. Gross (1982). Vasomotion, tissue fluid flow and the formation of lymph. *Int. J. Microcirc. Clin. Exp.* 1:55-65.
- Johnson, R.A. and T.M. Blake (1966). Lymphatics of the heart. *Circulation* 33:137-142.
- Jones, W.R., P.J. O'Morchoe and C.C.C. O'Morchoe (1983). The organization of endocytotic vesicles in lymphatic endothelium. *Microvasc. Res.* 25:286-299.
- Kaiserling, H. and T. Soostmeyer (1939). Die Bedeutung des Nierenlymphgefasssystem fur die Nierenfunktion. *Wiener. Klin. Wschr.* 52:113. Cited by I. Rusznyak, M. Foldi and G. Szabo. IN: Lymphatics and Lymph Circulation. Pergamon Press, New York, 1967.
- Kardon, R.H. and R.G. Kessel (1980). Three-dimensional organization of the hepatic microcirculation in the rodent as observed by scanning electron microscopy of corrosion casts. *Gastroenterology* 79:72-81.
- Kisselew, T. (1869). Ueber die Lymphgefasse der Leber. *Zentbl. med. Wiss.* 7:147. Cited by J.M. Yoffey and R.C. Courtice. IN: Lymphatics and Lymph Circulation. Pergamon Press, New York, 1967.

- Kriz, W. and H.J. Dieterich (1970). Das lymphgefäßsystem der Niere bei einigen Säugetieren. Licht- und electronenmikroskopische untersuchungen. *Z. Anat. Entwickl-Gesch* 131:111-147.
- Kushida, H. (1971). A new method for embedding with Epon 812. *J. Elec. Microsc.* 20:206-207.
- Lauweryns, J.M. and L. Boussaw (1969). The ultrastructure of pulmonary lymphatic capillaries of newborn rabbits and human infants. *Lymphology* 2:108-129.
- Leak, L.V. (1970). Electron microscopic observations on lymphatic capillaries and the structural components of the connective tissue-lymph interface. *Microvasc. Res.* 2:361-391.
- Leak, L.V. (1971). Studies on the permeability of lymphatic capillaries. *J. Cell Biol.* 50:300-323.
- Leak, L.V. (1972). The transport of exogenous peroxidase across the blood-tissue-lymph interface. *J. Ultrastruct. Res.* 39:24-42.
- Leak, L.V. (1976). The structure of lymphatic capillaries in lymph formation. *Fed. Proc.* 35:1863-1871.
- Leak, L.V. (1980). Lymphatic vessels. IN: Electron Microscopy in Human Medicine, J.V. Johannessen, ed. McGraw-Hill Co., New York. vol. 5, pp. 155-212.
- Leak, L.V. (1984). Physiology of the lymphatic system. IN: Blood Vessels and Lymphatics in Organ Systems, D. I. Abramson and P.B. Dobrin, eds. Academic Press, New York. pp. 134-164.
- Leak, L.V. and J.F. Burke (1966). Fine structure of the lymphatic capillary and the adjoining connective tissue area. *Am. J. Anat.* 118:785-810.
- Leak, L.V. and J.F. Burke (1968). Electron microscopic study of lymphatic capillaries in the removal of connective tissue fluids and particulate substances. *Lymphology* 1:39-52.
- Leak, L.V., A. Shannahan and H. Sculley (1971). Electron microscopic studies on lymphatics in the mammalian heart. *Anat. Rec.* 169:365.
- Leak, L.V. and K. Rahil (1978). Permeability of the diaphragmatic mesothelium: The ultrastructural basis for 'stomata.' *Am. J. Anat.* 151:557-593.
- Leak, L.V. and M.P. Januar (1983). Ultrastructure of pulmonary lymphatic vessels. *Am. Rev. Respir. Dis.* 128:S59-S65.

- Lee, F.C. (1923). On lymph vessels of the liver. *Contr. Embryol. Carneg. Instn.* 15:63-71. Cited by J.M. Yoffey and R.C. Courtice. IN: Lymphatics, Lymph and the Lymphomyeloid Complex. Academic Press, London, 1967.
- Lee, J.S. (1984). Hepatic lymph flow and protein concentration during intravenous saline infusion and intestinal fluid absorption. *Microvasc. Res.* 27:370-378.
- Ludwig, C. and T. Sawarykin (1863). Die Lymphwurzeln in der Niere des Säugetieres. *Sitz.-Ber. Wien. Akad. Wiss.* 47:242. Cited by I. Rusznyak, M. Foldi and G. Szabo. IN: Lymphatics and Lymph Circulation. Pergamon Press, New York, 1967.
- MacGillavry, T.N. (1864). Zur Anatomie der Leber. *Sitz.-Ber. Wien. Akad. Wiss.* 50:207-224. Cited by J.M. Yoffey and R.C. Courtice. IN: Lymphatics, Lymph and the Lymphomyeloid Complex. Academic Press, New York, 1970.
- Magari, S., K. Fujikawa, Y. Mizutani and A. Nishi (1979). Morphological studies on liver lymphatics. *Lymphology* 12:14-17.
- Mascagni, P. (1787). *Vasorum lymphaticorum corporis humani descriptio e iconographia*. Siena. Cited by I. Rusznyak, M. Foldi and G. Szabo. IN: Lymphatics and Lymph Circulation. Pergamon Press, New York, 1967.
- Mazzone, R.W. and S.M. Kornblau (1981). Pinocytotic vesicles in the endothelium of rapidly frozen rabbit lung. *Microvasc. Res.* 21:193-211.
- McIntosh, G.H. and B. Morris (1971). The lymphatics of the kidney and the formation of renal lymph. *J. Physiol.* 214:365-376.
- Michel, C.C. (1974). The transport of solute by osmotic flow across a leaky membrane and a note on the reflection coefficient. *Microvasc. Res.* 8:122-124.
- Mollenhauer, H.H. (1964). Plastic embedding mixtures for use in electron microscopy. *Stain Technol.* 39:111.
- Munkacsi, I. and M. Palkovits (1977). Measurements on kidneys and vasa recta of various mammals in relation to urine concentrating capacity. *Acta. Anat.* 98:456-468.

- Niuro, G.K., H.M. Jarosz, P.J. O'Morchoe and C.C.C. O'Morchoe (1982). Computer-assisted analysis of the rat intrarenal lymphatic system. IN: Advances in Lymphology: Proceedings of the 8th International Congress of Lymphology, V. Bartos and J. W. Davidson, eds. Avincenum, Czechoslovak Medical Press, Prague, pp. 73-79.
- Niuro, G.K., H.M. Jarosz, P.J. O'Morchoe and C.C.C. O'Morchoe (1985a). Distribution and size of renal cortical lymphatics in the rat, hamster and rabbit. In preparation.
- Niuro, G.K. and C.C.C. O'Morchoe (1985b). Pattern and distribution of hepatic lymph vessels. In preparation.
- Nicolaysen, G., A. Nicolaysen and N. Staub (1975). A quantitative radioautographic comparison of albumin concentration in different sized lymph vessels in normal mouse lungs. *Microvasc. Res.* 10:138-152.
- Nordquist, R.E., R.D. Bell, R.J. Sinclair and M.J. Keyl (1974). The distribution and ultrastructural morphology of renal lymphatic vessels proliferating in response to kidney injury in the dog. *Lymphology* 7:32-36.
- Nordquist, R.E., R.D. Bell, R.J. Sinclair and M.J. Keyl (1973). The distribution and ultrastructural morphology of lymphatic vessels in the canine renal cortex. *Lymphology* 6:13-19.
- Nuck, A. (1692). *Adenographia curiosa et uteri foeminei anatome nova*. Lugd. B. Cited by I. Rusznyak, M. Foldi and G. Szabo. IN: Lymphatics and Lymph Circulation. Pergamon Press, New York, 1967.
- Ohkuma, M. (1973). Electron microscopic observation of the renal lymphatic capillary after injection of ink solution. *Lymphology* 6:175-181.
- O'Morchoe, C.C.C. (1982). Structure and function of the renal lymphatic system. IN: Advances in Lymphology: Proceedings of the 8th International Congress of Lymphology, V. Bartos and J.W. Davidson, eds. Avincenum, Czechoslovak Medical Press, Prague, pp.67-72.
- O'Morchoe, C.C.C. (1984). The anatomy of the lymphatic system. IN: Blood Vessels and Lymphatics in Organ Systems, D.I. Abramson and P.B. Dobrin, eds. Academic Press, Inc., New York. pp. 126-133.
- O'Morchoe, C.C.C. (1985). Lymphatic drainage of the the kidney. IN: Biology of the Lymphatic Circulation. M.G. Johnson, ed. Elsevier Science Publishers, B.V., Amsterdam. pp. 261-303.

- O'Morchoe, C.C.C., P.J. O'Morchoe and E.J. Donati (1975). Comparison of hilar and capsular renal lymph. *Am. J. Physiol.* 229:416-421.
- O'Morchoe, C.C.C. and K.H. Albertine (1980). The renal cortical lymphatic system in dogs with unimpeded lymph and urine flow. *Anat. Rec.* 198:427-438.
- O'Morchoe, P.J., V.V. Yang and C.C.C. O'Morchoe (1980). Lymphatic transport pathways during volume expansion. *Microvasc. Res.* 20:275-294.
- O'Morchoe, C.C.C., K.H. Albertine and P.J. O'Morchoe (1982). The rate of translymphatic endothelial fluid movement in the canine kidney. *Microvasc. Res.* 23:180-187.
- O'Morchoe, C.C.C., W.R. Jones, H.M. Jarosz, P.J. O'Morchoe and L.M. Fox (1984). Temperature dependence of protein transport across lymphatic endothelium in vitro. *J. Cell Biol.* 98: 629-640.
- Palade, G.E. (1953). Fine structure of blood capillaries. *J. Appl. Physiol.* 24:1424.
- Palade, G.E. (1961). Blood capillaries of the heart and other organs. *Circulation* 24:368-384.
- Palade, G.E., M. Simionescu and N. Simionescu (1979). Structural aspects of the permeability of the microvascular endothelium. *Acta Physiol. Scand. Suppl.* 463:11-32.
- Palay, S.L. and K.J. Karlin (1959). An electron microscopic study of the intestinal villus. I. The foslery animal. *J. Biophys. biochem. Cytol.* 5:363-371.
- Parker, A.E. (1935). Studies on the main posterior lymph channels of the abdomen and their connections with the lymphatics of the genito-urinary system. *Am. J. Anat.* 56:409-443.
- Peirce, E.C. (1944). Renal lymphatics. *Anat. Rec.* 90:315-335.
- Pissas, A. and M. Papamiltiades (1981). Our experience on anatomical injection of the lymphatic vessels. *Lymphology* 14:145-148.
- Pullinger, P.D. and H.W. Florey (1935). Some observations on the structure and function of lymphatics: Their behavior in local edema. *Br. J. exp. Path.* 16:49-61.
- Rawson, A.J. (1949). Distribution of the lymphatics of the human kidney as shown in a case of carcinomatous permeation. *Arch. Path.* 47:283-292.

- Reinke, Fr. (1898). Ueber direkte Kernteilungen und Kernschwund der menschlichen Leberzellen. Anat. Anz. 14(Suppl):86-89. Cited by J.M. Yoffey and R.C. Courtice. IN: Lymphatics, Lymph and the Lymphomyeloid Complex. Academic Press, London, 1970.
- Rhodin, J.A.G. (1965). Fine structure of the peritubular capillaries of the human kidney. IN: Progress in Pyelonephritis, E.H. Kass, ed. F.A. Davis Company, Philadelphia. pp. 391-458.
- Ritchie, H.D., J.H. Grindley and J.L. Bollman (1959). Flow of lymph from the canine liver. Am. J. Physiol. 196:105-109.
- Rappaport, A.M. (1973). The microcirculatory hepatic unit. Microvasc. Res. 6:212-228.
- Rodrigues Grande, N., J. Ribeiro, M. Soares and E. Carvalho (1983). The lymphatic vessels of the lung: Morphological study. Acta anat. 115:302-309.
- Rajo-Ortega, J.M., E. Yeghiayan and J. Genest (1973). Lymphatic capillaries in the renal cortex of the rat. An electron microscopic study. Lab. Invest. 29:336-341.
- Rusznayk, I., M. Foldi and G. Szabo (1967). Lymphatics and Lymph Circulation, Pergamon Press, New York.
- Rutili, G. and K.E. Arfors (1977). Protein concentration in interstitial and lymphatic fluids from the subcutaneous tissue. Acta. Physiol. Scand. 99:1-8.
- Schatzki, P.F. (1978). Electron microscopy of lymphatics of the porta hepatis. Acta Anat. 102:54-59.
- Schmit-Nielsen, B. and R. O'Dell (1961). Structure and concentrating mechanism in the mammalian kidney. Am. J. Physiol. 200:1119-1124.
- Skalak, T.C., G.W. Schmid-Schonbein and B.W. Zweifach (1984). New morphological evidence for a mechanism of lymph formation in skeletal muscle. Microvasc. Res. 28:95-112.
- Steel, R.G.D. and J.H. Torrie (1960). Principles and Procedures of Statistics, McGraw-Hill, New York, p. 106.
- Szabo, G., Z. Mayyar and F. Jakob (1975). The lymphatic drainage of the liver capsula and hepatic parenchyma. Res. exp. Med. 166:193-200.



- Vogel, G., K. Gartner and M. Ulbrich (1974). The flow rate and macromolecule content of hilar lymph from the rabbit kidney under conditions of renal venous pressure elevation and restriction of renal function - Studies on the origin of renal lymph. *Lymphology* 3:136-143.
- Wagner, R.C. and J.R. Casley-Smith (1981). Endothelial vesicles. *Microvasc. Res.* 21:267-298.
- Wagner, R.C. and C.S. Robinson (1984). High-voltage electron microscopy of capillary endothelial vesicles. *Microvasc. Res.* 28:197-205.
- Weibel, E.R. (1973). Stereological techniques for electron microscopy. IN: Principles and Techniques of Electron Microscopy. Biological Application, M.A. Hayat, ed. Van Nostrand Rheinhold Co., New York, Vol. 3, pp. 237-296.
- Williams, S.K., M.A. Matthews and R.C. Wagner (1979). Metabolic studies on the micropinocytic process in endothelial cells. *Microvasc. Res.* 18:175-184.
- Wolgast, M., M. Larson and K. Nygren (1981). Functional characteristics of the renal interstitium. *Am. J. Physiol.* 241:F105-F111.
- Yang, V.V., P.J. O'Morchoe and C.C.C. O'Morchoe (1980). Influence of exogenous albumin on intraendothelial vesicles of lymphatic capillaries. *Proc. Electron Mic. Soc. of Am.* 524-525, G.W. Bailey, ed.
- Yang, V.V., P.J. O'Morchoe and C.C.C. O'Morchoe (1981). Transport of protein across lymphatic endothelium in the rat kidney. *Microvasc. Res.* 21:75-91.
- Yoffey, J.M. and R.C. Courtice (1970). Lymphatics, Lymph and the Lymphomyeloid Complex. London, Academic Press.
- Zweifach, B.W. and J.W. Prather (1975). Micromanipulation of pressure in terminal lymphatics in the mesentery. *Am. J. Physiol.* 228:1326-1335.

**APPENDIX A**

Tissue Processing Procedures and Solutions

General

1. Dice tissue in cold buffer.
2. Immerse diced tissue in 2% glutaraldehyde, overnight at 4° C.
3. Wash tissue in cold buffer (x3 for 1 hr).
4. Post-fix in 1% OsO<sub>4</sub> for 1 hr at room temperature.
5. Dehydrate and embed.

Dehydration-embedding schedule

- 25% acetone for 10 min. (x1)
- 50% acetone for 10 min. (x1)
- 75% acetone for 10 min. (x1)
- 95% acetone for 10 min. (x2)
- 100% acetone for 10 min. (x3)
- 1:1 acetone:plastic, overnight on rotary shaker.
- 1:3 acetone:plastic, next day for at least 6 hr on rotary shaker.
- 100% plastic overnight in desiccator.
- embed in fresh plastic the next morning.

Embedding Medium

Araldite-Poly/Bed 812 mixture (Poly/Bed 812, Polysciences, Inc.)

Araldite 502	20 g
Poly/Bed 812	30 g
DDSA	60 g
DMP-30	2 g

Kushida (Kushida, 1971)

NSA	25.7 g
Epon 812	20.5 g
Araldite 502	3.4 g
DMP-30	0.6 g

Buffer (0.157M Sodium Cacodylate, pH 7.4)

1. Dissolve 33.6 g sodium cacodylate in distilled water to make 1 L.  
(pH. will be about 7.8)
2. Adjust pH to 7.4 with 1.2N HCl.  
(final osmolality - 320-325 mOsm/L)

Acrolein fixative

8% acrolein in sodium cacodylate buffer. Acrolein must be fresh (clear, slightly brown) and must be stored in refrigerator until the morning of use.

Solution (con't)Glutaraldehyde fixative

2% glutaraldehyde in sodium cacodylate buffer

Osmium Tetroxide post-fixative1% Os<sub>4</sub> in sodium cacodylate buffer

Additional Notes on Renal Drip Fixation

1. Anesthetize animal with intraperitoneal injection of sodium pentobarbital (50mg/kg body wt.)
2. Place animal on operating board with limbs secured to board.
3. Make a mid-line abdominal incision.
4. Retract abdominal wall with four safety pins (be careful not to damage liver).
5. Pull out intestines onto anterior thoracic wall and cover with gauze swab soaked in warm saline. Kidneys should now be exposed. Keep the kidneys wet with warm saline.
6. Pour the acrolein fixative (room temperature) into the drip bottle on the magnetic stirrer under the hood. Thoroughly mix acrolein and buffer and continue to stir throughout the procedure. Prime both drip tubes before the start of fixation either by letting the mixture run through the tubes or if necessary by pulling it through the drip tubes with a syringe.
7. In female animals, push the tubes and ovaries as far down into the pelvis as possible and hold in place with half a dental swab on each side.
8. Place the animal under the hood.
9. Place a paper collar around the neck of the animal and place an air tube with gently blowing air at the face of the animal. This prevents the animal from directly breathing acrolein fumes.
10. Place a suction tube on each side of the abdominal cavity.
11. Place the 'drip tubes' in their holders over each kidney. Be sure that drops of acrolein do not fall on the kidney before the start of the experiment.
12. Start the suction, then the acrolein drip.

Renal Drip Fixation (con't)

13. Drip for about 15 min at 1-2 drops/second with acrolein.
  - The animal must be alive at the onset of drip.
  - Note the survival time of the animal after the start of drip, usually only about 1-2 min.
  - Make sure that the tubes and ovaries do not get caught up in the suction tube.
  - Approximately 250 ml of fixative are needed for a rat.
14. After drip is completed, tie off the renal pedicle and remove the kidneys. Remove any perirenal fat attached to the kidneys.
15. Immerse kidneys in fresh acrolein for at least 4 hr, at 4° C. Continue processing according to the general directions given at the beginning of this appendix (p. 142).

Additional Notes on Renal Perfusion Fixation

- 1-5. Same as for renal drip fixation.
6. Fill perfusion bottles with room temperature saline and 2% glutaraldehyde. Pressurize bottles to 120 mm Hg.
7. Dissect abdominal aorta from vena cava caudalis.
8. Place two ligatures (e.g., 000 silk) around the abdominal aorta, distal to the renal arteries. Separate ligatures as far as possible.
9. Tie off the most distal ligature. Rest of procedure should be completed in 2-3 min.
10. Pull up on the proximal ligature to stop blood flow in the aorta.
11. Cannulate aorta with PE 90 polyethylene tube in a retrograde direction and move the end of the cannula past the proximal ligature (be careful not to move the cannula past the renal arteries).
12. Tie cannula in place with the proximal ligature.
13. In as rapid succession as possible and in this order: start perfusion with saline, occlude the abdominal aorta just below the diaphragm, and cut the vena cava caudalis.
14. Immediately after the kidneys flush (approximately 25-50 ml of saline in 30 seconds), start perfusion with glutaraldehyde.
15. Perfuse with fixative for about 5-10 min (approximately 500 ml of fixative are needed for a rat).
16. Process tissue according to the general directions given at the beginning of this appendix (p. 142).

Additional Notes on Hepatic Perfusion Fixation

- 1-5. Same as that for renal perfusion.
6. Fill perfusion bottles with room temperature saline and 2% glutaraldehyde. Pressurize bottles to 40 mm Hg.
7. Dissect portal vein from fat.
8. Place two ligatures (e.g., 000 silk) around the portal vein. Separate ligatures as far as possible.
9. Tie off all small tributaries to the portal vein. Tie off ligature furthest from the liver.
10. Pull up on the ligature closest to the liver to prevent back flow from the liver and make a small incision in the portal vein.
11. Cannulate the portal vein with PE 90 polyethylene tubing and move the end toward the liver just past the ligature.
12. Tie the cannula in place with the ligature.
13. In as rapid succession as possible and in this order: start perfusion with saline, cut the vena cava caudalis and occlude the hepatic artery.
14. Immediately after the liver flushes (approximately 10 ml of saline in 30 seconds) start perfusion with glutaraldehyde.
15. Perfuse with glutaraldehyde for 10-15 minutes (approximately 100-150 ml of fixative are needed for a rat liver).
16. Process tissue according to the general directions given at the beginning of this appendix (p.142).



**APPENDIX B**

RENAL LYMPHATICS

RAT DRIP	BLOCKS	LYMPHATICS	VOLUME DENSITY ( $\mu\text{m}^3/\mu\text{m}^3 \pm \text{SEM}$ )	PROFILE DENSITY ( $\# \text{Ly}/\text{mm}^2 \pm \text{SEM}$ )
1	8	3	0.0012 <u>+0.0011</u>	2.32 <u>+1.76</u>
2	8	3	0.0018 <u>+0.0016</u>	2.39 <u>+1.20</u>
3	8	6	0.0015 <u>+0.0006</u>	6.14 <u>+2.09</u>
4	8	6	0.0021 <u>+0.0015</u>	5.80 <u>+3.83</u>
5	8	3	0.0015 <u>+0.0010</u>	1.76 <u>+1.24</u>
6	8	3	0.0020 <u>+0.0011</u>	2.34 <u>+1.15</u>

-----  
24 LymphaticsMean  
+SEM0.0017  
+0.00013.46  
+0.80  
-----RAT  
PERFUSED

1	8	20	0.0099 <u>+0.0038</u>	6.01 <u>+2.13</u>
2	8	20	0.0143 <u>+0.0034</u>	6.25 <u>+1.51</u>
3	9	13	0.0093 <u>+0.0048</u>	3.66 <u>+1.32</u>

-----  
53 LymphaticsMean  
+SEM0.0112  
+0.00165.31  
+0.83  
-----

RENAL LYMPHATICS (con't)

RABBIT	BLOCKS	LYMPHATICS	VOLUME DENSITY ( $\mu\text{m}^3/\mu\text{m}^3 \pm \text{SEM}$ )	PROFILE DENSITY ( $\# \text{ Ly}/\text{mm}^2 \pm \text{SEM}$ )
1	8	6	0.0023 <u>+0.0010</u>	3.24 <u>+1.22</u>
2	8	16	0.0021 <u>+0.0011</u>	3.36 <u>+1.75</u>
----- 22 Lymphatics			Mean 0.0022 <u>+SEM +0.0001</u>	3.30 <u>+0.06</u> -----

## HAMSTER

1	8	48	0.0368 <u>+0.0110</u>	15.05 <u>+2.30</u>
2	8	35	0.0366 <u>+0.0107</u>	17.18 <u>+5.03</u>
----- 83 Lymphatics			Mean 0.0367 <u>+SEM +0.0001</u>	16.41 <u>+0.76</u> -----

HEPATIC LYMPHATICS

RAT PERFUSED	BLOCKS	LYMPHATICS	VOLUME DENSITY ( $\mu\text{m}^3/\mu\text{m}^3 \pm \text{SEM}$ )	PROFILE DENSITY ( $\# \text{Ly}/\text{mm}^2 \pm \text{SEM}$ )
1	4	9	0.0024 $\pm 0.0012$	1.28 $\pm 0.64$
2	4	20	0.0353 $\pm 0.0176$	2.04 $\pm 1.02$
3	4	11	0.0096 $\pm 0.0048$	3.49 $\pm 1.74$
4	4	7	0.0025 $\pm 0.0012$	1.45 $\pm 0.72$
5	4	9	0.0015 $\pm 0.0008$	1.43 $\pm 0.72$
6	4	7	0.0008 $\pm 0.0004$	0.83 $\pm 0.72$
7	4	21	0.0242 $\pm 0.0121$	2.18 $\pm 1.09$
8	4	11	0.0020 $\pm 0.0010$	1.34 $\pm 0.67$
----- 95 Lymphatics			Mean $\pm \text{SEM}$	0.0098 $\pm 0.0046$
				1.76 $\pm 0.29$ -----

APPROVAL SHEET

The dissertation submitted by George K. Niuro has been read and approved by the following committee:

Dr. Charles C.C. O'Morchoe, Co-Director  
Director, University of Illinois College of Medicine

Dr. Faith W. LaVelle, Co-Director  
Associate Professor, Anatomy, Loyola

Dr. Patrick W. Bankston  
Associate Professor, Anatomy, Indiana University

Dr. James P. Filkins  
Professor, Physiology, Loyola

Dr. Raoul Fresco  
Professor, Pathology, Loyola

Dr. John A. McNulty  
Associate Professor, Anatomy, Loyola

Dr. Rajinder Nayyar  
Associate Professor, Anatomy, Loyola

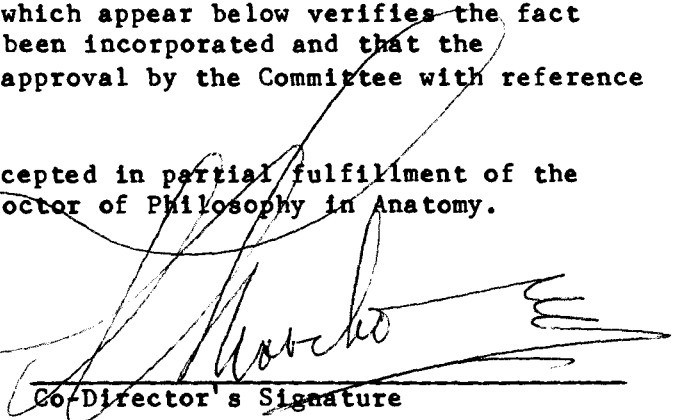
The final copies have been examined by the co-directors of the dissertation and the signatures which appear below verifies the fact that any necessary changes have been incorporated and that the dissertation is now given final approval by the Committee with reference to content and form.

The dissertation is therefore accepted in partial fulfillment of the requirements for the degree of Doctor of Philosophy in Anatomy.

Date

3/17/85

Co-Director's Signature



Date

3/22/85

Co-Director's Signature

