




1983

## Identification of Langerhans Cells in Human Gingival Epithelium

Charles Frank DeFranco  
*Loyola University Chicago*

Follow this and additional works at: [https://ecommons.luc.edu/luc\\_theses](https://ecommons.luc.edu/luc_theses)

 Part of the [Oral Biology and Oral Pathology Commons](#)

---

### Recommended Citation

DeFranco, Charles Frank, "Identification of Langerhans Cells in Human Gingival Epithelium" (1983).  
*Master's Theses*. 3361.  
[https://ecommons.luc.edu/luc\\_theses/3361](https://ecommons.luc.edu/luc_theses/3361)

This Thesis is brought to you for free and open access by the Theses and Dissertations at Loyola eCommons. It has been accepted for inclusion in Master's Theses by an authorized administrator of Loyola eCommons. For more information, please contact [ecommons@luc.edu](mailto:ecommons@luc.edu).



This work is licensed under a [Creative Commons Attribution-NonCommercial-No Derivative Works 3.0 License](#).  
Copyright © 1983 Charles Frank DeFranco

IDENTIFICATION OF LANGERHANS CELLS IN  
HUMAN GINGIVAL EPITHELIUM

BY

Charles Frank DiFranco, D.D.S.

A Thesis Submitted to the Faculty of the Graduate School  
of Loyola University of Chicago in Partial Fulfillment  
of the Requirements for the Degree of  
Master of Science

May

1983

## DEDICATION

To my wife, Kimberly, whose love and constant  
support made this all possible.

## ACKNOWLEDGEMENTS

I wish to express my sincere gratitude to Dr. Patrick Toto, a concerned teacher and researcher whose guidance helped me immeasurably.

I would also like to thank Dr. Geoffrey Rowden for his dedication to this research, his expertise and accessibility. Thanks also to the other members of the thesis committee, Dr. Anthony Gargiulo and Dr. Joseph Keene for their support.

Gratitude and special thanks to Eileen Connolly for her technical expertise and hard work.

## LIFE

The author, Charles Frank DiFranco, is the son of Paul and Geraldine DiFranco. He was born June 13, 1955 in Chicago, Illinois.

His elementary education was obtained in the Catholic and public schools of Chicago and Park Ridge, Illinois. His secondary education was obtained at Maine Township High School South of Park Ridge where he graduated in June, 1973.

In September, 1973, he entered Loyola University of Chicago. In August of 1974 he enrolled at Northwestern University, Evanston, Illinois. In September of 1975 he returned to Loyola University where he received the degree of Bachelor of Arts with a major in biology in 1977.

He entered the Loyola University School of Dentistry, Maywood, Illinois, in September 1977. He received the degree of Doctor of Dental Surgery in May 1981.

On June 6, 1981 he married Kimberly Collins in St. Paul of the Cross Catholic Church, Park Ridge, Illinois. In September of 1981 he entered a two year post graduate clinical specialty in periodontics at Loyola University School of Dentistry. On March 11, 1983 Paul Edward DiFranco the first child of Charles and Kimberly DiFranco was born.

In May, 1983, he received a Certificate of Specialty in Periodontics.

## TABLE OF CONTENTS

	PAGE
DEDICATION . . . . .	ii
ACKNOWLEDGEMENTS . . . . .	iii
LIFE . . . . .	iv
LIST OF TABLES . . . . .	vii
LIST OF FIGURES. . . . .	ix
Chapter	
I. INTRODUCTION. . . . .	1
II. LITERATURE REVIEW . . . . .	3
A. Studies in Dermatology. . . . .	3
B. Studies in Oral Mucosa. . . . .	7
C. Ultrastructural Characteristics . . . . .	10
D. Demonstration and Identification of Langerhans Cells. . . . .	15
III. MATERIALS AND METHODS . . . . .	22
A. Selection of Patients . . . . .	22
B. Experimental Design . . . . .	23
C. Staining. . . . .	25
D. Microscopic Examination . . . . .	26
E. Statistical Analysis. . . . .	28
IV. RESULTS . . . . .	30
A. Hematoxylin and Eosin . . . . .	30
B. ATPase. . . . .	30

	PAGE
C. S-100 Protein. . . . .	31
D. Ia (HLA-DR). . . . .	32
E. OKT-6. . . . .	32
F. Statistical Analysis . . . . .	34
V. DISCUSSION . . . . .	36
VI. SUMMARY AND CONCLUSIONS. . . . .	53
REFERENCES . . . . .	55
APPENDIX . . . . .	67

## LIST OF TABLES

Table	Page
1. Specimen #1 Clinically Normal. Nuclei of Epithelial Langerhans Cells Identified in Each 0.13 mm <sup>2</sup> Microscopic Field - 43 Fields Examined (Section Prepared by OKT-6 Technique and Observed at 400X) . . . . .	68
2. Specimen #1 Clinically Inflamed. Nuclei of Epithelial Langerhans Cells Identified in Each 0.13 mm <sup>2</sup> Microscopic Field - 50 Fields Examined (Section Prepared by OKT-6 Technique and Observed at 400X) . . . . .	69
3. Specimen #2 Clinically Normal. Nuclei of Epithelial Langerhans Cells Identified in Each 0.13 mm <sup>2</sup> Microscopic Field - 60 Fields Examined (Section Prepared by OKT-6 Technique and Observed at 400X) . . . . .	70
4. Specimen #2 Clinically Inflamed. Nuclei of Epithelial Langerhans Cells Identified in Each 0.13 mm <sup>2</sup> Microscopic Field - 60 Fields Examined (Section Prepared by OKT-6 Technique and Observed at 400X) . . . . .	71
5. Specimen #3 Clinically Normal. Nuclei of Epithelial Langerhans Cells Identified in Each 0.13 mm <sup>2</sup> Microscopic Field - 36 Fields Examined (Section Prepared by OKT-6 Technique and Observed at 400X) . . . . .	72
6. Specimen #3 Clinically Inflamed. Nuclei of Epithelial Langerhans Cells Identified in Each 0.13 mm <sup>2</sup> Microscopic Field - 52 Fields Examined (Section Prepared by OKT-6 Technique and Observed at 400X) . . . . .	73
7. Specimen #4 Clinically Normal. Nuclei of Epithelial Langerhans Cells Identified in Each 0.13 mm <sup>2</sup> Microscopic Field - 56 Fields Examined (Section Prepared by OKT-6 Technique and Observed at 400X) . . . . .	74
8. Specimen #4 Clinically Inflamed. Nuclei of Epithelial Langerhans Cells Identified in Each 0.13 mm <sup>2</sup> Microscopic Field - 56 Fields Examined (Section Prepared by OKT-6 Technique and Observed at 400X) . . . . .	75



Table	Page
9. Specimen #5 Clinically Normal. Nuclei of Epithelial Langerhans Cells Identified in Each 0.13 mm <sup>2</sup> Microscopic Field - 28 Fields Examined (Section Prepared by OKT-6 Technique and Observed at 400X) . . . . .	76
10. Specimen #5 Clinically Inflamed. Nuclei of Epithelial Langerhans Cells Identified in Each 0.13 mm <sup>2</sup> Microscopic Field - 28 Fields Examined (Section Prepared by OKT-6 Technique and Observed at 400X) . . . . .	77
11. Specimen #6 Clinically Normal. Nuclei of Epithelial Langerhans Cells Identified in Each 0.13 mm <sup>2</sup> Microscopic Field - 46 Fields Examined (Section Prepared by OKT-6 Technique and Observed at 400X) . . . . .	78
12. Specimen #6 Clinically Inflamed. Nuclei of Epithelial Langerhans Cells Identified in Each 0.13 mm <sup>2</sup> Microscopic Field - 28 Fields Examined (Section Prepared by OKT-6 Technique and Observed at (400X). . . . .	79
13. Specimen #7 Clinically Normal. Nuclei of Epithelial Langerhans Cells Identified in Each 0.13 mm <sup>2</sup> Microscopic Field - 28 Fields Examined (Section Prepared by OKT-6 Technique and Observed at 400X) . . . . .	80
14. Specimen #7 Clinically Inflamed. Nuclei of Epithelial Langerhans Cells Identified in Each 0.13 mm <sup>2</sup> Microscopic Field - 41 Fields Examined (Section Prepared by OKT-6 Technique and Observed at 400X) . . . . .	81
15. Nuclei of Epithelial Langerhans Cells Anticipated in 1.0 mm <sup>2</sup> Microscopic Fields Prepared by the OKT-6 Technique and Observed at 400X . . . . .	82

## LIST OF FIGURES

Figure	Page
1. Hematoxylin and Eosin (Clinically Normal) 2.5X . . . . .	83
2. Hematoxylin and Eosin (Clinically Normal) 10X. . . . .	84
3. Hematoxylin and Eosin (Clinically Inflamed) 2.5X . . . . .	85
4. Hematoxylin and Eosin (Clinically Inflamed) 10X . . . . .	86
5. ATPase (Robins and Brandon, 1981) (Clinically Inflamed) 25X. . . . .	87
6. ATPase (Robins and Brandon, 1981) (Clinically Inflamed) 250X . . . . .	88
7. ATPase (Wachstein and Meisel, 1960) (Clinically Normal) 2.5X . . . . .	89
8. ATPase (Wachstein and Meisel, 1960) (Clinically Inflamed) 2.5X . . . . .	90
9. S-100 Protein (Clinically Normal) 2.5X . . . . .	91
10. S-100 Protein (Clinically Inflamed) 2.5X . . . . .	92
11. S-100 Protein (Clinically Inflamed) 250X . . . . .	93
12. HLA-DR (Clinically Normal) 10X . . . . .	94
13. HLA-DR (Clinically Inflamed) 10X . . . . .	95
14. HLA-DR (Clinically Inflamed) 25X . . . . .	96
15. HLA-DR (Clinically Inflamed) 25X . . . . .	97
16. OKT-6 (Clinically Normal) 2.5X . . . . .	98
17. OKT-6 (Clinically Inflamed) 2.5X . . . . .	99
18. OKT-6 (Clinically Inflamed) 25X. . . . .	100

Figure	Page
19. OKT-6 (Clinically Inflamed) 400X. . . . .	101
20. OKT-6 (Clinically Inflamed) 400X. . . . .	102
21. Major Developments in the History of the Langerhans Cell. . . . .	103
22. Protocol for ATPase Preparation (Wachstein et al., 1960) . . . . .	104
23. Protocol for ATPase Preparation (Robins and Brandon, 1981) . . . . .	105
24. Protocol for S-100 Self Sandwich Preparation (Hsu, 1980). . . . .	106
25. Protocols for OKT-6 and HLA-DR Preparation (Murphy, 1981) . . . . .	107
26. Criteria for the Gingival Index System. . . . .	108
27. Statistical Analysis. . . . .	109
28. Procedure . . . . .	110
29. Letter to Institutional Review Board Chairman . . . . .	111
30. Reply from Institutional Review Board Chairman. . . . .	112
31. Consent and Permit for Periodontal Surgery. . . . .	113

## CHAPTER I

### INTRODUCTION

Langerhans cells are dendritic nonkeratinocytes apparently unrelated to melanocytes, which were first described in skin over one hundred years ago. They were then thought to represent a fixed population of peripheral nervous elements in the suprabasal layers of the epidermis (Langerhans, 1868). Recent studies have demonstrated lymphocyte-Langerhans cell interactions at sites of contact allergic reactions (Silberberg-Sinakin, 1978), and migration of Langerhans cells via dermal lymphatics to lymph nodes (Silberberg, 1975). Langerhans cells have been shown to possess on their cell surfaces receptors for  $C_3$  and  $F_c$  - IgG (Stingl, 1977), Ia-like antigens (Rowden, 1980), and have been demonstrated capable of presenting antigens to T lymphocytes (Braathen, 1980). The vast majority of scientific research concerning Langerhans cells has appeared in the dermatology literature. The purpose of this study is 1) to qualitatively compare four recent techniques of Langerhans cell detection in oral epithelium, 2) to quantitatively compare Langerhans cells in clinically normal and clinically inflamed human gingival biopsies.

Subjects will be selected who present with chronic periodontitis and display moderate to severe gingival inflammation as assessed by the G.I. of Loe (1967). A sextant associated with clinically inflamed tissues will not be treated while the remaining teeth will be scaled and

root planed. Two gingival biopsies will be taken; clinically normal treated, and clinically inflamed untreated tissue. Langerhans cells cannot be identified by H&E stained sections. Histochemical and immunocytochemical methods must be utilized under light microscopy. In the present study Langerhans cells will be specifically stained for ATPase (Wachstein and Meisel, 1957), HLA-DR (Rowden, 1977), S-100 (Cocchia et al; 1981), and OKT6 (Murphy, 1982).

## CHAPTER II

### LITERATURE REVIEW

#### A. Studies in Dermatology

In the mid 19th century, Paul Langerhans, while studying the nervous system, discovered a population of dendritic cells in the epidermis. He described them as "dark bodies which are very distinct from epithelial cells" (Langerhans, 1868). He visualized these cells by impregnating human skin with gold salts, observed a suprabasal location, and noted that some dendrites reached upwards toward the stratum corneum, while others extended downward through the lower layers of the epidermis. Langerhans, however, felt that these cells were part of the nervous system and that their dendrites reached into the dermis and connected with the nerve system there. His theory was maintained until the 1960's (Ferreira-Marques, 1951; Niebauer & Sekido, 1965). During the 1950's and 1960's a concept which postulated a relationship between Langerhans cells and melanocytes predominated. Langerhans cells were then regarded as either previously active melanocytes (Masson, 1951), daughter cells of dividing melanocytes (Zelickson, 1966), or as melanocytes in an arrested stage of development (Breathnach, 1963).

Although Langerhans cells were first described more than one hundred years ago, they had failed to attract much attention until the 1960's. This may have been due, in part, to the technical difficulty of the

available staining techniques and to limitations of experimental methods to study their biologic activities. The concepts which prevailed to this time seemed justified and discouraged experiments to search for alternatives. As investigative procedures improved and the older concepts concerning this cell were challenged, general interest was revived.

The research of the late 1960's and 1970's pointed to a mesenchymal origin for the Langerhans cell. Langerhans cell granules (Birbeck granules) were reported to be present in certain mesodermal tissues (Kondo, 1969) (Hoshimo, 1970) (Breathnach, 1977). Langerhans cell granules were also identified in certain histocytic cells of histiocytosis X, (Basset & Turiaf, 1965) (Cancilla et al., 1967) malignant cells of malignant histiocytosis, (Inamura, 1971) and leukemic reticuloendotheliosis (Shamoto, 1976).

Some investigators postulated that the Langerhans cell might play a role in immunologic reactions and suggested that the cells might capture antigenic material. Hashimoto (1968) considered it to be an epidermal macrophage. When tracers such as peroxidase are injected in vivo into the skin some of the material is engulfed by Langerhans cells which incorporate this into their phagolysosomal system (Wolff, 1970). However, this research also demonstrated that keratinocytes phagocytose with much more vigor than the "moderately phagocytic" Langerhans cell. Phagocytosis did not seem to be the major function of the Langerhans cell.

Silberberg (1973) investigated and compared the penetration of mercury in normal skin and in skin of individuals who were contact-allergic to mercury. She observed close apposition of lymphocytes to Langerhans cells at sites of contact allergic reactions while in normal skin and

irritant reactions there was no apposition. In a subsequent study involving guinea pigs actively sensitized with 2-4-dinitro-1-chlorobenzene (DNBC) as opposed to control animals showed lymphocyte-Langerhans cell apposition as early as 3-5 hours after antigenic challenge. Langerhans cells were reduced in number nineteen hours after this antigenic challenge and seemed to be damaged. In the passively sensitized guinea pigs at the site of antigenic challenge, lymphocyte-Langerhans apposition was seen not only in the epidermis, but was also pronounced in the dermis where the Langerhans cells had increased significantly as compared to controls. Langerhans cells were first seen in the passively sensitized animals two hours after antigenic challenge.

The findings suggested that the epidermal Langerhans cell system is the body's first line of defense. This cell system is well suited to protect against environmental agents since, under normal conditions, molecules of low molecular weight are the only ones able to penetrate the skin. They also suggested that Langerhans cells capture antigenic substances in skin, circulate to a draining lymph node, and cause specific sensitization of immunocompetent T cells in the node and thus they may play an important role in delayed-type hypersensitivity reactions. (Silberberg et al.;1976)

Simultaneous publications by Rowden (1977) and Klareskog (1976) demonstrated that Langerhans cells were the only cell type in human epidermis to express Ia-like antigens which were shown to represent HLA-DR. The investigators used immunofluorescence staining in their experiments. Ia antigen have been demonstrated to be integral for macrophage antigen-presenting functions (Rosenthal 1978). Langerhans cells from guinea pig



epidermis were subsequently shown to act in vitro to present exogenous antigens to sensitized lymphocytes and also act as stimulator cells for mixed lymphocyte reactions. (Stingl, 1978) Shelley and Juhlin (1976) demonstrated the ability of Langerhans cells to take up contact allergens and proposed an antigen-trapping cell system.

At approximately the same time, Stingl et al., (1977) concluded from his studies that Langerhans cells are the only epidermal cells which express receptors for  $C_3$  and the  $F_c$  portion of IgG. It is very unlikely that Langerhans cells belong to either T or B cell lineage because they lack the classical cell markers (E receptors and surface immunoglobulins) which are expressed on the majority of human (Moretta et al.; 1976) and guinea pig (Stingl et al.;) T and B lymphocytes (Pichler et al.; 1978). The surface markers present ( $F_c$ -IgG and  $C_3$ ) correspond to those of macrophages, monocytes, and histiocytic cell types i.e. mononuclear phagocytes.

Recent studies by Tamaki and Katz (1979,1980) have utilized the Langerhans cell property of bearing Ia antigens on their surfaces. These chimeric studies indicated that Langerhans cells were derived from a continuously replenished mobile pool of precursor cells which originate mostly from a bone-marrow derived cell line.

There are many important implications to the recognition of Langerhans cells as epidermal macrophages. The Langerhans cell may be the major cell responsible for rejection of allografts in the epidermis. Present research suggests that the Langerhans cells are immunocompetent cells and function as part of the body's peripheral immune system. They are especially important in presentation of surface applied antigens to

T lymphocytes and stimulation of a subsequent immune response. These cells seem to have a number of common features with cells in the monocyte-macrophage series.

#### B. Studies in Oral Mucosa

The oral epithelium as well as the epidermis is composed predominantly of keratinocytes. There is also, however, a minority population of non-keratinocytes known as "clear cells" because of their appearance in routine paraffin-embedded material. They may be distinguished by the absence of desmosomal attachments to adjacent cells (Breathnach, 1980). These dendritic cell types include melanocytes, Merkel cells, and Langerhans cells, all of which may also be distinguished by the presence or absence of ultrastructural organelles as well as by specific light microscopic techniques. All three cell types are dendritic, exhibiting branched cytoplasmic processes of varying dimensions.

Melanocytes are derived from an embryonal neural crest cell population which synthesizes melanin and transfers it to other cells of the epidermis or oral epithelium. The Merkel cell complex represents a slowly adapting mechanoreceptor, the exact mechanism of which has yet to be established. (Iggo, 1969) Langerhans cells have been identified in the oral mucosa of many species (Waterhouse and Squier, 1967; Barker, 1967; Schroeder and Theilade, 1966; Hashimoto et al.; 1968; Sagebiel and Clarke, 1970; Hutchens et al.; 1971; Listgarten, 1972; Hill, 1977; Burkhardt, 1979; Newcomb, 1982). Squier (1969) demonstrated the presence of both melanocytes and Langerhans cells in whole epithelial sheets of oral mucosa in the rat. Szabo (1967) reported similar numbers of melanocytes

per square millimeter in human oral mucosa as in epidermis. He did not quantitate the average number of melanocytes in the various oral regions.

Langerhans cells and melanocytes were quantitated in vestibular gingiva, hard palate, tongue, cheek mucosa, and the skin of the external lip of Rhesus monkeys (Hutchens et al., 1971). DOPA and osmium iodide reactions were used to identify basal and suprabasal dendritic cells by light microscope. Electron microscopy was used to confirm the presence of basal melanocytes and suprabasal Langerhans cells. Basal dendritic cells were more numerous in pigmented than unpigmented areas, but suprabased cells did not vary with degree of pigmentation. The number of Langerhans cells in heavily keratinized areas such as gingiva, palate, and the dorsal aspect of the tongue, was significantly greater than in areas which appeared unkeratinized. The largest number of suprabasal cells was observed in the epithelium of the dorsum of the tongue. Few Langerhans cells were identified within the crevicular epithelium. Hutchens et al., suggested a direct relationship between Langerhans cells and the degree of keratinization.

Hill in 1977 studied neonatal rat palatal mucosa using the ATPase staining reaction described by Wolf and Winklemann. He found an increase in epidermal Langerhans cells during the first 12 days after birth which appeared to remain constant from 12-33 days. Langerhans cells were identified as rounded masses of ATP positive cells with short dendritic processes during the first two days. By four days there was a change in number and distribution of Langerhans cells observed to the typical dendritic pattern. This difference may be a response to antigenic stimulation

or merely a functional maturation process.

Bos and Burkhardt (1979, 1980) examined interepithelial cell populations in germ free, specific pathogen-free, and conventionalized mice (in which an oral flora was allowed to develop) by light and electron microscopy. They found in the epithelium of the tongue a mean of 7.4 cells per 1000 basal cells. After conventionalization a significant increase to 14.4 interepithelial cells per 1000 basal cells was observed. A basal value for Langerhans cells was determined in germ free mice. Lymphocytes and Langerhans cells were classified and quantified solely on the basis of morphologic characteristics. The light microscopic techniques used by this group have not been shown to be cell specific for Langerhans cells. Bos and Burkhardt (1980) felt that an increase in lymphocytes and Langerhans cells was in response to external antigenic challenge.

The degree of keratinization of the oral epithelium has been observed to decrease when gingival inflammation is present (Weinmann and Meyer, 1959). If there was a positive direct relationship between the number of Langerhans cells and the degree of keratinization the Langerhans cells numbers would be expected to decrease as clinical inflammation increases. Newcomb et al., (1982) examined attached gingiva as plaque was allowed to accumulate. This group used a modification of the ATPase method as proposed by Juhlin and Shelley (1977). Langerhans cells appeared to become more dendritic in shape after 8 days of plaque accumulation than at day 0. At 21 days the same number and morphologic appearance was noted as at 8 days. As dental plaque accumulated adjacent to and on

attached gingiva there was a statistically significant increase in Langerhans cells in the stratum spinosum. This observation would seem to negate the possibility of a relationship between Langerhans cells and keratinization.

Bos and Burkhardt (1981) studying the murine oral mucosa reported a low mitotic rate for Langerhans cells as opposed to typical keratinocytes. These results were in agreement with previous studies of epidermis by Mackenzie (1970) and Potten (1974). These studies indicated that the Langerhans cells may migrate into stratified squamous epithelium of the skin and oral mucosa as immature progenitor cells. It also seems reasonable that this might be a recirculating cell population in exchange with cells of the T-cell areas of the local lymph nodes. Necrosis of the cells is not logical since cells are not seen in a stage of disintegration or in the stratum corneum where remnance might be shed.

The recent research discussed has up to this point had a significant effect on our understanding of contact allergy of the skin. Langerhans cells may as well play a major role in delayed hypersensitivity reactions of the skin and oral mucosa and changes in Langerhans cell function could be the basis of certain oral pathologic manifestations.

### C. Ultrastructural Characteristics

Birbeck et al.; (1961) established the basic criteria which permit visualization with the aid of an electron microscope and distinguishes them from melanocytes and Keratinocytes.

- 1) A clear cytoplasm
- 2) A lobulated nucleus

- 3) The absence of desmosomes or tonofilaments
- 4) The absence of premelanosomes or melanosomes
- 5) The presence of a distinct organelle now referred to as "Langerhans cell granule" or Birbeck granule"

The cytoplasm of the Langerhans cell possesses all the characteristics of a cell engaged in active metabolic activity and in protein synthesis. Both smooth and rough endoplasmic reticulum are present along with centrioles. Free ribosomes are of relatively inconsistent numbers but they are very numerous in some cells. The Langerhans cell has a well developed Golgi apparatus and often times two or more Golgi regions can be observed in one plane of section of a single cell. Typically stacked cisternae are found to make up this Golgi, which may be dilated and consist of multiple small vesicles at its concave face and lateral margins. Also a variety of vesicles of different sizes are present in the cytoplasm and may show a fuzzy coat on the internal face of their membrane. The vesicles with the fuzzy coat represent cross sections of the vesicular portions of the Langerhans cell granules. Oblong granules have also been described to occur rarely with a dense matrix and a trilaminar limiting membrane. (Wong 1971, Zelickson 1966).

Under electron microscopic observation the outlines of the cells are irregular but do not appear to be dendritic since the sectioning is rarely done through several dendrites. However, images of dendrites sectioned cross-sectionally or longitudinally are easily observed interspersed between the keratinocytes and throughout the epidermis. (Wolf,

1972). In these sections of the epidermis the cytoplasm of the Langerhans cells appears relatively clear as compared to the surrounding keratinocytes. The cytoplasmic membrane is devoid of desmosomes although it is in close proximity of the membranes of adjacent keratinocytes and usually allows no dilations of the intercellular space. The nucleus is lobated or folded, however, round nuclei may be occasionally found.

The most surprising feature of the cytoplasm is the absence of tonofilaments. There are filaments of a different nature present but they are not always present in all parts of the cytoplasm consistently. At times they are regimented, ordered parallel strands and are similar to those found in melanocytes or macrophages. As with many of the other features, it has not yet been elucidated whether their occurrence is variable or the different tissue processing methods and stains may affect their visualization.

#### The Langerhans Cell Granule

The chemistry of the Langerhans cell granules has yet to be clearly defined. No enzymatic activity has been observed in these granules up to this point in time. They are stained intensely with the reaction product of the osmium-zinc-oxide procedure (Niebauer, 1969). Intracytoplasmic granules are osmium-zinc-iodide positive, however, the granules which have come in contact with the cytomembranes are not (Niebauer, 1969). Niebauer assumed that it was a lipid substance responsible for the chemical nature of the material responsible for the metallic deposits.

Birbeck (1961) described the granule as a rod-shaped organelle with

a central linear, striated density. One of the ends of the cell may exhibit a partly expanded limiting membrane which has been described as resembling a tennis racket (Zelickson, 1965). These forms have been proposed as sectional areas of disc-shaped organelles and their vesicular portion as a formative stage (Birbeck, 1961).

The most common electron microscopic picture is that of a rod-like profile with rounded ends and a limiting membrane approximately 60 A thick. The inner face of this membrane is lined by a leaflet composed of small particles spaced at 50-60 A intervals (Wolff, 1967). In between the limiting membranes of the granule there is a linear density with a periodical striation which has been described as 50-50 A (Wolff, 1967; Zelickson 1965) or as 90 A (Birbeck, 1961). It represents a lamella made up of electron opaque particles separated by 50-60 A wide spaces and aligned as two parallel lines (Wolff, 1967). These are often continuous with vesicles which are located either at one end of the granule, or its center with rod-like profiles projecting from its circumference. The vesicular fragment has a clear center and the inner side of its membrane displays a fuzzy coat which, in good sections seems to be organized into regularly spaced granular particles which appear to be similar to the particles lining the membrane of the rod-like portion (Wolff, 1967).

The Langerhans cell granules appear to be distributed randomly within the cytoplasm but they are frequently seen in a close relationship with the Golgi region. The vesicles with a fuzzy internal coat are found interspersed between Golgi vesicles or adjacent to the lateral portions



of Golgi cisternal (Wolff, 1972). The granules also have been reported in the cell periphery, although less frequently. They may be attached to the plasma membrane with their interior opening into the intercellular space (Wolff, 1967); (Zelickson 1965); (Breathnach 1964); (Hashimoto 1968). They are never, however, totally discharged into the extracellular compartment.

The granules appear as oval bodies exhibiting a two-dimensional square lattice of particles if cut tangentially (Birbeck & Breathnach 1961) (Zelickson 1965). These appear to merge into a cross-striated pattern in different planes of the same section. Three dimensional models of the Langerhans cell granules have been proposed by Wolff (1967) and Sagebiel (1968) and were later confirmed by Breathnach (1973) utilizing a freeze fracture technique and more recently by Caputo (1976) with a similar technique. As a result of cytolysis Langerhans cell granules have rarely been identified in the intercellular spaces of the epidermis (Wolff, 1969). Granules are not found in keratinocytes except in a situation where the entire Langerhans cell is phagocytosed by the epidermal cell.

### Lysosomes

Langerhans cells have been reported to contain a variety of lysosomes which have been described as single membrane limited dense bodies (Breathnach, 1964) containing acid phosphatase (Wolff, 1970). They are lined by a single triple-layered membrane and contain a granular matrix, lamellae, whorled membranes (Breathnach, 1964) (Zelickson, 1965) or myelin-like

structures (Bell, 1967). Acid phosphatase is packaged in the Golgi system then is transferred to either autophagosomes or heterophagosomes which are thus transformed into secondary lysosomes. This is consistent with what is known concerning the lysosomal system in general ((DeDuve, 1966). Multivesicular bodies, sacks or vacuoles which have been described intracytoplasmically probably belong to the lysosomal system. Often times debris or remnants of organelles i.e. Langerhans cell granules may be found (Breathnach, 1964) which would categorize these vacuoles as autolysosomes.

#### D. Demonstration and Identification of Langerhans Cells

##### 1. Hematoxylin and Eosin

This type of staining is of little or no value for certain identification of Langerhans cells. The cells appear in the suprabasal layers as high-level "clear cells" exhibiting deeply staining nuclei which is surrounded by apparently "clear" cytoplasm. Keratinocytes are similarly stained therefore cannot be distinguished from Langerhans cells (Clark, 1961).

##### 2. Gold Impregnation

This is the classical technique most commonly employed for examination of the gross morphology and the distribution of cells. There are a variety of methods available, (Carey (1942); Ferreira-Marques (1951) and Paul Langerhans himself impregnated epidermal specimens with gold chloride.

The characteristic dendritic shape is well visualized in a well-impregnated specimen. Little detail of the internal structures of the cell, however, with the exception of a nucleus can be discerned. As

previously mentioned there are several variations in the gold chloride impregnation. These techniques, however, all have the disadvantage requiring diligent preparation and inconsistent results have been reported (Becker, 1952). In adequately impregnated specimens this stain appears to be specific for Langerhans cells as verified by electron microscopy (Breathnach 1965; Zelickson 1968).

### 3. Osmium Iodide

The Champy-Coujard technique was utilized by Niebauer (1956), Mishima and Miller Milinska (1961) and was actually considered to be more consistently reliable than gold impregnation (Miller Milinska, 1961). The procedure, however, is not specific for Langerhans cells since melanocytes or keratinocytes are also stained. Hutchins (1971) also used this method in examining the oral mucosa of Rhesus monkeys. The osmium iodide reaction stained the entire dendritic cell black, obliterating cytoplasmic detail.

### 4. ATPase

For the demonstration of Langerhans cells within human, mouse, guinea pig and rhesus monkey epidermis the demonstration of a formalin resistant and sulphhydryl dependent adenosine triphosphatase (ATPase) is a reliable and Langerhans cell-specific procedure (Jarret and Riley, 1963, Mustakallio (1963) Bradshaw (1963) Wolff (1962) Mackenzie and Squier (1975). Langerhans cells were also identified by this method in rat palatal mucosa and human gingival epithelium (Hill, 1977); (Barker, 1967); (Waterhouse and Squier, 1967); (Newcomb, 1982). With proper techniques

the morphologic results are good, reliable, and the stain is specific for Langerhans cells. This enzymatic technique does, however, have a disadvantage. It is not known whether all Langerhans cells react positively at all times and since the method depends upon enzyme activity, it may be influenced or inhibited in pathologic conditions. There has of yet been no explanation of the function of ATPase on the cell surface. An association was made between plaque accumulation and an increase in Langerhans cells in human attached gingiva using the ATPase methods (Newcomb, 1982). A modification of the adenosine triphosphatase method has recently been described which involves prolonged fixation in cacodylate formalin and reportedly permits a more reliable visualization of cells (Robins and Brandon 1981).

#### 5. L-Dopa and Amines

Human epidermal Langerhans cells have been reported to be capable of taking up L-dihydroxyphenylalanine (L-dopa) and the catecholamines dipamine and noradrenaline when exposed to these in vivo (Falck, 1976; Axelsson, 1978). A chemical reaction with formaldehyde transforms L-dopa and the catecholamines into strongly fluorescent molecules within the tissue. The dopa fluorophore of the Langerhans cell has an excitation/emission which is easily distinguished from the formaldehyde-induced fluorophore of cysteinyl-dopa, a normal constituent of human melanocytes. This seems to be a reliable method for the visualization of Langerhans cells within normal epidermis. When skin biopsy specimens from antigenically challenged sites of hapten-sensitized animals are treated though,

fluorescent clusters of both dendritic and nondendritic cells are observed. This suggests that different mononuclear cells uptake L-dopa and catecholamines (Sjoberg, 1978).

#### 6. $\alpha$ -D Mannose

Using the  $\alpha$ -D mannose technique to stain Langerhans cells the cell body but not the dendrites are visualized (Elleder, 1975).

#### 7. HLA-DR and Ia antigens

A region of chromosome-17 of the mouse called the Ia region or immune response region contains a series of genes which appear to be integral to a number of cell surface interactions related to the immune response. (McDevitt et al., 1976; David, 1976). Many of these Ir genes are capable of producing proteins on a cell surface that will be perceived as antigens if introduced into the body of an individual of different genetic background (Albert, 1977). A number of articles have recently dealt with the possible significance of the Ia antigens presence on Langerhans cells (Streilein & Bergstresser, 1980; Stingl et al., 1980a; Stringl et al., 1980a; Stringl et al., 1980b; Rowden, 1980; Rowden, 1981).

HLA antigens are glycoproteins on the surface of most eucaryotic cells. The glycoproteins are unique to the cell surface of an individual and enable the immune system to "fingerprint" a given cell as its own. The HLA antigens are coded for by several genes on the short arm of chromosome-6 in humans is referred to as the major histocompatibility complex (MHC) or HLA (Albert, 1977). Humans do not produce antibodies against their own HLA antigens, however, they will evoke an immune response if

transplanted into a person of dissimilar genetic makeup. The genetic loci which produce HLA antigens are termed A, B, C, D and DR and their products HLA-A, HLA-B, HLA-C, HLA-D, and HLA-Dr. The major histocompatibility complex controls the reaction of animals to various immunologic challenges. (Sasazuki et al., 1977) Most of this immunologic activity may be restricted to the area of the D locus.

HLA-DR antigens of humans and murine Ia antigens are thought to be analagous.. (Balner, 1979) The murine MHC has been much more extensively investigated because of the availability of inbred populations for study.

Rowden et al, (1977) and Klareskog (1976) reported that Langerhans cells express cell surface Ia-like antigens. At the present time it seems that only Langerhans cells or their precursors express Ia antigens on their cell surface. Frozen sections may be stained utilizing the appropriate anti-Ia antisera commercially available and a peroxidase-labeled secondary anti-immunoglobulin. (Rowden, 1980)

## 8. T-6 Antigen

It has recently been reported that monoclonal antibody anti T-6 reacts with most immature human thymocytes, but not with circulating peripheral T cells. (Reinherz et al., 1980; Bahn et al., 1980) This antigen is present when the cells are in the thymic cortex but may be lost and apparently replaced by other antigens when the cells mature into circulating peripheral T cells. T-6 has been identified as a glycoprotein with a molecular weight of 49,000 daltons. (Terhorst et al., 1981; Van Agthoven and Terhorst, 1982; Cotner et al., 1981) The T-6 antigen has recently been detected on the surface of Langerhans cells (Murphy et al., 1981;

Fithian et al., 1981) Immuno-electron microscopy has been utilized to confirm the specificity of T-6 for Langerhans cells in the epidermis. (Murphy, 1981; Murphy, 1982; Dubertret, et al.; Chu, 1982)

Staining is of a similar protocol as that used for HLA-DR antigens. Basically, frozen sections are stained with monoclonal mouse anti T-6 reagents, followed by goat antimouse IgG usually with a peroxidase label. There are now many commercially available anti-T-6 reagents.

#### 9. S-100

Moore (1965) originally extracted the S-100 protein from bovine brain at which time it was thought to be unique to the nervous system. It is an acidic calcium-binding protein (Klee et al., 1980) composed of three subunits, (Dannies and Levine 1971) and has a molecular weight of 21,000 - 24,000 daltons. (Moore, 1965; Dannies and Levine 1971). There are several reviews concerning the biochemical aspects of S-100 protein (Moore, 1972; Bock, 1978; Isobe and Okuyame, 1978; Varon and Somjen, 1979), although the biologic function of the protein remains unknown.

S-100 protein has been demonstrated primarily in the neurons of the CNS (Hyden et al., 1966; Sriridov et al., 1972; Hansson H-A et al., 1976), however, outside the CNS S-100 has only been identified in Schwann cells and satellite cells of the dorsal root and autonomic ganglia. (Stefansson, 1982)

S-100 protein has recently been reported to be present in Langerhans cells of normal human epidermis (Cocchia et al., 1981). The protein has also been identified with interdigitating reticulum cells (IDC) in the paracortical zones of lymph nodes. (Takahashi et al., 1981), which along

with veiled cells of lymph may be related to Langerhans cells (Drexhage et al., 1979; Thorbecke et al., 1980; Veldman & Kaiserling, 1980; Hoefsmit et al., 1980; Hoefsmit et al., 1982).

Staining of epidermal Langerhans cells can be accomplished using either a peroxidase antiperoxidase (PAP) method (Sternberger et al., 1970; Sternberger, 1979) or an avidin-biotin method (Hsu et al., 1981a; Hsu et al., 1981b).



## CHAPTER III

### MATERIALS AND METHODS

#### A. SELECTION OF PATIENTS

Thirteen adult human subjects, four females and nine males, ranging in age from 29 to 52 were selected for this research. They were diagnosed as having Type III moderate periodontitis or Type IV severe periodontitis according to the American Academy of periodontology's (1977) definition of case types. None of the patients had received a prophylaxis within the last six months.

To participate in the study, the patients were required to have at least one area of attached, marginal, and/or papillary gingiva which displayed moderate to severe inflammation as assessed by the criteria of the Gingival Index of Loe and Silness (1963) as modified by Loe (1966). Periodontal surgery was included as a possibility in the future treatment plan of each patient. None of the patients had a history of rheumatic fever, hepatitis, or other systemic complicating factors. An absence of other oral pathology was also established. The females included in the study were neither pregnant, lactating, nor taking oral contraceptives.

Each patient received an oral explanation of the study. It was explained that a portion of tissue normally discarded during routine periodontal surgery would be retained for microscopic examination as part of a research project. This study was reviewed by the chairman of the Loyola

University Medical Center Institutional Review Board for the Protection of Human Subjects (IRB) before commencement. In reply to submission of a thesis outline it was decided that there was no need for IRB submission as long as the specimens were obtained during a surgical procedure which the patient undergoes for reasons unrelated to the study. Other stipulations were that the specimens were not identified in terms of a patient's name, and the cost of the study was not billed to the patient. Patients were required only to sign the routine consent and permit for periodontal surgery used by the Loyola University School of Dentistry.

Although thirteen subjects agreed to participate in the research, eleven completed therapy which included periodontal surgery. One of the female subjects had to be eliminated from the study because of an excellent response to initial therapy. This included scaling and curettage, after which periodontal surgery was not indicated as assessed at the time of reevaluation. After a reevaluation the patient was placed on three month recalls for prophylaxis as indicated, and no further periodontal treatment was performed. One of the male subjects withdrew from the dental clinic and, subsequently, the research participation.

#### B. EXPERIMENTAL DESIGN

An area in the oral cavity of each subject which showed clinical inflammation and was scored as GI=2 or GI=3 was left untreated until periodontal surgery was performed. This usually consisted of an area of two to three teeth and the adjacent attached, marginal, or papillary gingiva associated with them. In a majority of cases these teeth were

separated by an edentulous area from the teeth which would be treated. The remaining teeth were scaled and root planed. Oral hygiene instructions were initially given and were reinforced at each appointment. These appointments were from thirty to forty-five minutes in length and ranged from six to twelve weeks. Upon completion of this initial phase of therapy each subject's response to initial treatment was evaluated and a rationale for periodontal surgery was established. The female subject previously discussed was withdrawn from the study at this time. The area which at the initial examination displayed clinical inflammation (GI=2) received a lower score (GI=0) at the surgical evaluation. This improvement was apparently the result of improved home care. The oral tissues were scored at the time of the surgical evaluation and again at the surgical appointment as assessed by the Gingival Index as modified by Loe (1966).

#### PERIODONTAL SURGERY

Blood pressure, respirations, and pulse were assessed at the beginning of each surgical appointment. Anesthesia was administered using 2% lidocaine with 1/100,000 epinephrine. This was administered by nerve block whenever possible, and care was taken not to directly infiltrate anesthetic solution into the tissue scheduled for microscopic examination.

The initial incision during periodontal surgery was made with a #15 scalpel blade approximately two millimeters from the coronal edge of the face marginal gingiva. The tissue coronal to this incision was carefully freed from the tooth surfaces and immediately placed in prepared

vials of (RPMI). Each tissue specimen had been scored by the Gingival Index modified by Loe (1966) immediately prior to periodontal surgery and placed into vials marked as "clinically inflamed" or "clinically normal". Clinically normal tissue received a Gingival Index score of zero. Full mucoperiosteal flaps were then reflected and routine periodontal surgery was performed including osseous recontouring as indicated. The collar of tissue retained for microscopic examination is normally discarded after reflection of mucoperiosteal flaps during surgery. The surgical areas were sutured and protected with Coe Pak for one to two weeks post-operatively. There were no complications regarding surgical procedures or post-operation healing associated with any patients.

The qualitative state of the gingival soft tissues were assessed by the Gingival Index (GI) of Loe and Silness (1963) as modified by Loe (1966). In the Gingival Index system of scoring oral tissues, each of the four gingival areas of the tooth is given a score from zero to three. The scores from the four areas of the tooth are added and divided by four to give the GI for the tooth.

### C. STAINING

Specimens from each patient will be placed into individual vials marked as "clinically normal" or "clinically inflamed". These were stored in RPMI for up to three hours under refrigeration at Loyola University Dental School. The specimens were then transported to the Pathology Laboratory of the Loyola University Medical Center. Each section was immediately divided into three sections of approximately equal length under a dissecting microscope. Each section was then prepared

specifically for the staining protocol to be utilized at a future date.

The three different procedures were as follows:

1. Fixed in buffered formalin for eight hours at room temperature  
Rinsed with Buffer  
Paraffin embedded for Mayers Hematoxylin and Eosin and S-100 staining
2. Fixed in formaldehyde-cacodylate solution for one hour at 0-4°C  
Washed in phosphate buffered saline (PBS)
3. Frozen and stored at -80°C for future ATPase staining

The initial ATPase staining procedure utilized was essentially a modification of earlier adenosine triphosphatase methods (Wachstein and Meisel, 1957; Juhlin and Shelley, 1977; and Mackenzie and Squier, 1975) which employed prolonged fixation in cacodylate formalin as described by Robins and Brandon (1981). The last four specimens were stained utilizing a procedure described by Wachstein et al. (1960). The staining protocol used for S-100 was a technique which entailed incubating with S-100 antibody, antigen, and antibody (thus the name self sandwich) as described by Hsu and Ree (1980).

In staining for OKT6 and HLA-DR the technique utilized was essentially the same as that described by Rowden (1981). Frozen sections for HLA-DR were stained with the appropriate anti-IA antisera commercially available and a peroxidase labeled secondary immunoglobulin (Rowden (1981)). For OKT6 the frozen sections were stained with monoclonal mouse anti T-6 reagents, followed by goat antimouse IgG with a peroxidase label.

#### D. MICROSCOPIC EXAMINATION

A total of twenty-four tissue specimens were obtained from eleven

patients during periodontal surgery. After sectioning under a dissecting microscope and preparation as described in the previous section the slides were grouped for microscopic examination. Most slides included three serial sections from the same section and were approximately 5 microns in thickness. A total of fourteen slides were prepared for each of the eleven patients with a total of 154 slides being examined. The following slides were prepared and examined.

Hematoxylin and Eosin - clinically normal

Hematoxylin and Eosin - clinically inflamed

ATPase - clinically normal

ATPase - clinically inflamed

ATPase - control

OKT-6 - clinically normal

OKT-6 - clinically inflamed

OKT-6 - control

HLA-DR - clinically normal

HLA-DR - clinically inflamed

HLA-DR - control

S-100 - clinically normal

S-100 - clinically inflamed

S-100 - control

The slides were examined for each of the eleven subjects with the aid of a Spencer light microscope. All slides were qualitatively examined for the presence of Langerhans cells. The following parameters were also noted:

## Morphology of Langerhans Cells

Patterns of arrangement of cells

Presence or absence in lamina propria

Position in epithelium

Orientation

Staining reactions with other cells

Approximate numbers of cells

A quantitative procedure was also undertaken using the sections prepared with the OKT-6 staining protocol. Langerhans cells were quantitated using a 0.13 mm square standardized grid at a 400X magnification. A random number of fields for each section were examined. OKT-6-positive staining cells (nuclei) were counted and a mean was established for each specimen.

## E. STATISTICAL ANALYSIS

Eleven gingival specimens were obtained and stained with the OKT-6 method described by Murphy (1981). Of the eleven specimens stained for Langerhans cells, seven of these were qualitatively judged acceptable for quantitation. The four slides that were omitted from the quantitation of Langerhans cells were done so because of inconsistent sectioning. Staining by this method was consistent for all sections. All Langerhans cells were also identified in tangential sections (Fig 19), although quantitation was not performed because depth of the section was impossible to determine. Langerhans cells have been described traditionally in the suprabasal layers of the epithelium. Langerhans cell numbers were compared in the clinically normal gingival specimens vs. clinically

inflamed specimens. Statistical analysis was performed utilizing a students two sample T test (Fig. 27).



## CHAPTER IV

### RESULTS

There were no complications to the surgical procedures performed on the eleven patients involved with this research. Healing was uneventful in all cases.

#### A. Hematoxylin and Eosin

Inflammation was identified histologically in the hematoxylin and eosin stained sections. The clinically inflamed slide preparations were all easily distinguished from the clinically normal specimens. There were, however, different degrees of inflammation present in all the specimens. The sections of clinically normal human gingiva were identified by the presence of intact epithelium and connective tissue in the absence of pathologic changes of inflammatory cell infiltrates (Fig 1 and 2). The sections observed in the clinically inflamed group were characterized by edema, and engorged capillaries in the connective tissue (Fig 3 and 4). An infiltrate consisting of large numbers of lymphocytes, plasma cells, and polymorphonuclear leukocytes was consistently observed in the clinically inflamed group (Fig 3 and 4).

#### B. ATPase

A technique described by Robins and Brandon (1981) which involved prolonged fixation in cacodylate formalin was initially utilized (Fig 22). The first seven specimens were prepared in this manner in hopes of the

technique being an improved method as described by Robins and Brandon (1981). Due to technical problems of an unknown etiology, Langerhans cells were not identified in these sections (Fig 5 and 6). A classical ATPase staining method described by Wachstein and Meisel (1960) was utilized for the final four specimens in anticipation of improved visualization of Langerhans cells (Fig 21). Langerhans cells were identified in sections stained by this technique in the stratum spinosum above the basal lamina (Fig 7 and 8). Although Langerhans cell nuclei were identified in these sections the cells were not well visualized in terms of orientation or morphology. Qualitatively, there seemed to be an increased number of Langerhans cells in the clinically inflamed group (Fig 8) in comparison to the clinically normal (Fig 7) Langerhans cells could only be identified in the epithelium in these sections. Blood vessels in the lamina propria were deeply stained obscuring any Langerhans cells which might have been identified (Fig 7 and 8).

### C. S-100 Protein

A technique for staining Langerhans cells based on the presence of a cytoplasmic marker, S-100 protein was utilized as described by Hsu 1980 (Fig 23). Qualitatively this proved to be a reliable cell marker and Langerhans cells were easily visualized. Dendrites of the cells were not well depicted although cell nuclei stained deeply (Fig 10 and 11). Qualitatively, Langerhans cell numbers seemed to be increased in the clinically inflamed specimens (Fig 10) in comparison to the clinically normal (Fig 9). Langerhans cells were observed in the lamina propria, although rarely.

#### D. Ia (HLA-DR)

The staining technique for Ia (HLA-DR) utilized was described by Murphy (1981) (Fig 24). Langerhans cells were well stained and very easily distinguished from epidermal keratinocytes (Fig 13). Langerhans cells were most often identified in the stratum spinosum, but were occasionally seen in the lamina propria. Dendrites were prominently stained by this method (Fig 14 and 15). The cells themselves were more easily identified in clinically inflamed specimens (Fig 13). When qualitatively comparing clinically normal (Fig 12) to clinically inflamed (Fig 13) gingival biopsy sections, there seemed to be an increased number of cells in the clinically inflamed sections. The cells also seemed more dendritic and better developed morphologically (Fig 13 and 15).

#### E. OKT-6

Langerhans cells were well visualized in specimens prepared by a technique for OKT-6 described by Murphy (1981). The cells themselves were well differentiated with prominent dendrites and nuclei (Fig 17, 19 and 20). Langerhans cells were most often identified within the stratum spinosum, although they were sometimes seen in the lamina propria. Dendrites of the cells were observed stretching upwards towards the surface of the epithelium in clinically inflamed specimens (Fig 17, 20). Langerhans cells seemed to form a net or continuum just below the stratum corneum. Three such cells are seen in Fig 18. The dendrites of these cells appear to overlap although it is difficult to interpret in a two dimensional representation. Langerhans cell numbers were qualitatively and quantitatively shown to be increased in clinically inflamed (Fig 17 and

27) when compared to clinically normal (Fig 16) specimens. This was confirmed statistically ( $P = .01$ ), and an approximate five fold increase was noted. This result is even more significant when one considers that only nuclei of epithelial Langerhans cells were counted. Although dendrites of Langerhans cells were observed they were not considered in the data. A Langerhans cell stained with OKT-6 with a prominent nucleus and dendrites is noted in Fig 19, which is a tangential section.

For specimen #1 clinically normal human gingiva, the mean number of Langerhans cells identified in a  $0.13 \text{ mm}^2$  microscopic field at 400X was 0.19048 with a standard deviation of 0.397. The mean number of Langerhans cells observed in specimen #1 clinically inflamed in a  $0.13 \text{ mm}^2$  microscopic field was 1.200 and the standard deviation was 1.00. The increased numbers of Langerhans cells in the clinically inflamed group was shown by a student's two sample T test to be a significant increase at 0.01. For specimen #2 clinically normal the mean number of Langerhans cells identified in each field was 0.33333 and the standard deviation was 0.488. The mean for the clinically inflamed of specimen #2 was 1.3864 and the standard deviation was 1.06. This increase was shown by a T-test significant at the 0.01 level. The mean number of Langerhans cells identified in a  $0.13 \text{ mm}^2$  microscopic field at 400X for specimen #3 clinically normal was 0.500 with a standard deviation of 0.798. The mean for specimen #3 clinically inflamed was 0.84615 with a standard deviation of 0.881. This was not shown to be a significant increase at the 0.05 level. The mean for specimen #4 clinically normal was 0.26786 with a standard deviation of 0.522. The mean for specimen #4 clinically inflamed was 0.89286 with

a standard deviation of 0.824. This increase was shown by a T-test to be statistically significant at the 0.01 level. The mean number of Langerhans cells identified in a  $0.13 \text{ mm}^2$  microscopic section for specimen #5 clinically normal was 0.171429 with a standard deviation of 0.26. The mean number identified in specimen #5 clinically inflamed was 0.64286 with a standard deviation of 0.745. This increase in the clinically inflamed specimen was shown to be statistically significant at the 0.01 level. The mean number of cells identified in specimen #6 clinically normal was 0.12500 and the standard deviation was 0.334. For specimen #6 clinically inflamed the mean was 0.71429 and the standard deviation was 0.810. This was shown to be a statistically significant increase at the 0.01 level. The mean number of Langerhans cells identified in a  $0.13 \text{ mm}^2$  microscopic section of specimen #7 clinically normal at 400X was 0.42857 with a standard deviation of 0.690. The mean number identified in specimen #7 clinically inflamed was 1.4390 with a standard deviation of 0.976. This was shown to be a statistically significant increase for the clinically inflamed specimen at the 0.01 level.

#### F. Statistical Analysis

An increase in Langerhans cell numbers was observed for all clinically inflamed gingival tissue specimens when compared with clinically normal gingival biopsies. This was shown by a student's T test to be a significant increase ( $P = .01$ ) in six of the seven specimens stained with OKT-6 (Murphy, 1981) (Fig 27). Langerhans cell numbers in approximately one square millimeter of cross sectional epithelium were established (Table 15). Increases in Langerhans cell numbers seen in the

clinically inflamed gingival tissue specimens when compared to clinically inflamed specimens ranged from two to ten fold (Table 15).

## CHAPTER V

### DISCUSSION

#### Clinical Assessment of Gingiva

In the present study gingival tissues were assessed for degree of inflammation by the criteria of the Gingival Index System (Loe and Silness, 1963, Loe 1966). Inflammation was later established histologically in routine hematoxylin and eosin staining of specimens. Oral epithelium pale pink in color, stippled in texture, firm in consistency, and in the absence of bleeding upon probing was considered clinically normal. These gingival tissues received a Gingival Index score of zero. Specimens displaying moderate inflammation, redness, edema and glazing, in the presence of bleeding upon probing received a Gingival Index score of two. All specimens in the present study which were considered to be clinically inflamed had received a score of two as assessed by the criteria of the Gingival Index System. (Loe and Silness, 1963, Loe 1966). Gingival tissues which displayed severe inflammation, ulceration, and tendency to spontaneous bleeding were not included as specimens for the present study because of problems with preparation, and difficulty of interpretation of results.

Three patients were dropped from the study prior to periodontal surgical procedures. Significant improvements were noted as color changes and probing indices. This was apparently the result of the initial phases

of therapy including scaling, root planing, curettage, and oral hygiene instruction. Clinical improvement was, however, also observed in areas which had received no therapy. It was assumed that this was a result of the oral hygiene instructions and the meticulous home care by the patients. These areas had received lower Gingival Index scores after the first phase of therapy and were then excluded from the study.

Inflammatory infiltrates consisting of a few isolated polymorphonuclear leukocytes were sometimes observed in clinically normal specimens. It should be kept in mind that although gingival tissues were scored as clinically normal due to the appearance of the oral epithelial surface, these tissues may have been associated with a submarginal inflammation. The absence of overt inflammation was confirmed for each specimen histologically by examining the oral epithelial surfaces of the gingival specimens. It was not established what degree of inflammation was associated with the depths of the periodontal pockets involved. Bleeding upon probing was not elicited in the clinically normal gingival tissue specimens. Crevicular fluid indices were not utilized in the present study.

#### Comparison of Staining Techniques

Specific cell surface as well as cytoplasmic markers are useful in identification of Langerhans cells. The cytochemical composition of Langerhans cells results in a variability of their reaction to the reagents used in staining. OKT-6 is apparently a more reliable method of staining Langerhans cells than ATPase, since it relies on a specific antibody-antigen reaction. In addition, the use of monospecific or monoclonal antibodies further adds to specificity. It is not known whether



all Langerhans cells react positively at a given time when utilizing ATPase staining. The ATPase technique relies upon an enzymatic reaction which may be influenced by the active state of a particular cell or the cell of the associated pathologic conditions. Qualitatively OKT-6 was more efficient for staining and identification of Langerhans cells than ATPase in the present study, suggesting that cell surface antigenic determinants identified by the antisera may be subject to variation.

The use of S-100 protein as a cytoplasmic marker for the identification of Langerhans cells is a newer technique and is as of yet unperfected. It has yet to be established which reagents are the best fixatives. Therefore, the type of fixative, concentrations of fixatives, duration, and temperature of optimal fixation remains to be determined. Since OKT-6 and HLA-DR staining were achieved on essentially unperturbed specimens (frozen sections) such preparation artifacts were evaded. The S-100 protein technique is not however, without its advantages. It can be performed retrospectively on tissues obtained from the files of the pathology laboratory. As utilized in the present study S-100 protein seemed to be a reliable method for the identification of Langerhans cells in oral epithelium. The cytoplasm and nuclei was stained to a much better degree than the dendrites of Langerhans cells. Clearly further studies are required on the parameters mentioned above before S-100 staining may be fully assessed with respect to efficiency versus staining for surface antigens such as OKT-6 and HLA-DR.

The present study suggests that OKT-6 and Ia (HLA-DR) were

qualitatively the best stains for the identification of Langerhans cells of the reagents tested. These two techniques were very comparable in Langerhans cell identification properties but OKT-6 was qualitatively judged to be the best technique utilized. In light of other recent studies concerning Ia (HLA-DR), OKT-6 seems to be a more reliable marker for Langerhans cells. Larger numbers of OKT-6-positive cells have been identified in epidemics compared to HLA-DR. HLA-DR may not be cell specific for Langerhans cells but may be synthesized by other cells. (Daynes et al., 1983). Furthermore HLA-DR has also been reported to be present on the cell surfaces of T lymphocytes (Evans et al., 1978) and on damaged keratinocytes (Lampert et al., 1981).

The only situations in which keratinocytes have been shown to express cell surface Ia (HLA-DR) antigens are those in which some pathological process has induced some degree of perturbation or damage. In graft-versus-host disease (Lampert et al., 1981), mycosis fungoides and lichen planus, (Tjernlund 1979, 1980), disturbances in the activities of the Langerhans cell population may be associated with an onset of Ia antigen synthesis by keratinocytes. Such Ia bearing keratinocytes have, however, not been shown to be immunologically active as judged by their capacity to present antigens or stimulate in a mixed lymphocyte reaction (MLR) (Breathnach, 1983). Whether keratinocyte presentation of Ia antigen in such situations is of immunological significance or is an epiphenomenon remains to be seen.

An interpretation of staining reaction variability was performed

by (Harrist et al., 1983), using monoclonal antibodies in an immunoperoxidase procedure this group compared the numbers of T6-positive Langerhans cells with HLA-DR-positive cells in normal skin. These investigators concluded that intraepidermal Langerhans cells and indeterminate cells may be Ia-positive or Ia-negative. Thus, there may be a Langerhans cell subset which is Ia-negative and T6-positive. This hypothetical subset would not be identified as a result of Ia (HLA-DR) staining but would react to OKT-6 preparation. Langerhans cell numbers were shown to be significantly underestimated when quantitated with Ia (HLA-DR). Harrist states that "Perhaps the Ia-positive/T6-positive subset represents an activated state of Langerhans cells or a functionally distinct subtype" (Harrist et al., 1983). It is interesting to note that in the present study, sections stained with Ia (HLA-DR) and OKT-6 methods, the Langerhans cells seemed to be more dendritic in the clinically inflamed sections. The clinically inflamed specimens were most probably associated with a response to antigenic challenge. This finding is in agreement with the conclusions of Hill (1977) who examined neo-natal rat palatal mucosa and identified Langerhans cells as becoming more dendritic upon antigenic challenge.

#### Langerhans Cells and Keratinization

The dendritic morphology of Langerhans cells seems to characterize them as optimal immune surveillance cells due to the increased surface area. As an alternative, however, it has been suggested that this large surface area may allow distribution of controlling substances involved

in keratinization (Shah et al., 1981). A role has been considered for Langerhans cells in the production of chalines influencing epidermal turnover rates (Bullough and Lawrence 1968, Sagebiel et al., 1971, Potten and Allen 1976).

The T6 glycoprotein seems to be somehow related to the keratinizing environment. As Langerhans cells migrate from the bone marrow through the peripheral blood they are T6 negative. It is not until the cells arrive at the dermis where they are T6 negative or positive and eventually the keratinizing environment of the epidermis/oral epithelium when they are T6 positive. The identification of Langerhans cells with fewer numbers of Birbeck granules by electron microscopy may be interpreted as new arrivals in the process of developing into active cells. It should be mentioned at this point that Langerhans cells have been reported to be absent in certain situations of keratinization (Wolff 1972, Lessard et al. 1968). These isolated findings however, relate to the abnormal states of the epidermis responding to tape stripping; therefore such findings are questionable. In all statements concerning the identification of cells of Langerhans cell morphology but lacking Birbeck granules, the problem of serial thin sectioning must be borne in mind. This arduous task has seldom been achieved so it is not certain if cells identified as so-called indeterminate cells (i.e. lacking Birbeck granules) really exist in significant numbers.

The degree of keratinization of oral epithelium diminishes in the

presence of gingival inflammation (Weinman and Meyer, 1959). Newcomb et al., (1982) demonstrated in oral epithelium an increase in Langerhans cell numbers as plaque accumulated. The present study demonstrated an increase in Langerhans cells in inflamed gingival tissues apparently subjected to antigenic challenge when compared to tissues in the absence of clinically and histologically determined inflammation. There is always, however, a certain degree of inflammation associated with this tissue. If in fact, the degree of keratinization decreases in oral epithelium with inflammation, one might expect Langerhans cell numbers to decrease. This further confuses the role of Langerhans cells and the keratinization process the facts concerning the question of Langerhans cells and keratinization remain unanswered at this time.

#### Langerhans Cells vs. The Monocyte-Macrophage

There have recently been the description of a number of similarities reported between Langerhans cells and cells of the macrophage-monocyte series. Among these similarities are the facts that Langerhans cells have adenosine triphosphatase (ATPase) activity (Wolff, 1967) and have the ability to migrate (Silberg, 1973). Rowden et al., (1977, 1978) and Klareskog et al., (1977) have conclusively demonstrated that Langerhans cells were the only cell in the normal human epidermis to express Ia-like antigens which have been shown to possess HLA-DR. Ia-like antigens have been demonstrated to be integral for macrophage-antigen presenting functions (Rosenthal, 1978). Stingl (1977) furthermore, concluded from his studies that Langerhans cells are also the only epidermal cells which express receptors for  $C_3$  and the  $F_C$  portion of IgG. The same surface

markers are present on cells of the macrophage-monocyte series. Non-specific esterase activity has also been linked to the Langerhans cell (Berman, 1979). As previously discussed, Langerhans cells have the ability in vivo to actively present antigens in lymphocyte stimulation (Stingl, 1978). (Katz, et al., 1980,) indicated that epidermal Langerhans cells were derived from a pool of precursor cells in the bone marrow. When considering the similarities between Langerhans cells and cells of the macrophage-monocyte series the finding of a mesenchymal origin for Langerhans is of paramount importance.

Recently, through immunohistochemical analysis utilizing S-100 protein Langerhans cells, indeterminate (Nakajima, 1982) cells of the epidermis (lacking Birbeck granules) and interdigitating cells (IDCS) in the paracortical area of lymph nodes were studied in dermatopathic lymphadenitis situations. All three of these cells were included in a S-100 positive, lysosyme-negative group. Histiocytes in lymphatic sinuses were usually lysosyme-positive macrophages and were S-100 negative (Nakajima, 1982). This presents a question concerning the possibility of a separate lineage independent of the macrophage-monocyte system. Further confirmation of the heterogenicity of the macrophage series has been derived not only from situations where IDC's show a hyperplastic response as discussed above, but also in Histiocytosis X. Histiocytosis X is now considered as a Langerhans cell granulomatosis (Wolff, 1972), since the prominent atypical cell is a type of Langerhans cell as gauged by identification of ultrastructural Birbeck granules and the presence of T6 antigen (Murphy, 1981, Harrist, 1983). Such cells are also S-100-positive in contrast to

other histiocytic disorders of the skin such as juvenile xanthogranulomas and reticulohistiocytomas where histiocytes and giant cells predominate (Rowden et al., 1983).

### Langerhans Cell Roles

It seems unlikely that Langerhans cells function as active phagocytes in the epidermis or oral epithelium. It has been demonstrated that the surrounding keratinocytes in epithelium have the ability to phagocytose many times more vigorously than Langerhans cells (Wolff, 1970). As such the ability of the keratinocyte to phagocytose is not surprising since this process is an essential step in pigment processing. What is surprising is that Langerhans cells if they are to be considered members of the MPS (macrophage phagocyte system) should perform this function so poorly. There seems to be little similarity between the miniscule phagocytic activity of the Langerhans cell and the tremendous phagocytic capacity of the traditional macrophage.

Langerhans cells have been shown to express T6 antigen, a glycoprotein not normally associated with conventional macrophages (Murphy et al., 1981). This most recent finding is a further method of discriminating between dendritic cells and macrophages. What is not known is whether they represent distinct lineages or are related by functional activation of a stage in the cell cycle.

Langerhans cells have many attributes which suit them for participation in a number of immunologic reactions. They assume a strategic position in the epidermis and the epithelium of the oral mucosa. This was confirmed for oral mucosa. They have been referred to as the "the

body's first line of immunologic defense" (Silberberg et al., 1975). Langerhans cells have also been shown to possess up to twelve dendrites, each of these with an immunologically reactive terminal portion (Cruickshank, 1975). This physical attribute gives the Langerhans cell a tremendously increased surface area which would enhance its capacity for immune surveillance. There are other factors which when considered tend to point more toward Langerhans cell participation in immunologic reactions. In a very short period of time Langerhans cell will present at the site of antigenic challenge (Silberberg et al., 1975). The same group demonstrated that Langerhans cells are a dynamic migrating cell population rather than fixed cells in the epidermis (Silberberg et al., 1975).

The role of Langerhans cells in the pathogenesis of periodontitis is not known. However, other studies suggest such a pathway. Shelley and Juhlin (1976) demonstrated in guinea pigs and humans the selective uptake by Langerhans cells of small molecules (metals, aldehydes, amines) which have been known to act as contact allergens. They postulated that Langerhans cells formed a reticuloepithelial trap indicating a close relationship to the reticuloendothelial system which clears the tissue of antigens in the general circulation. This may in fact be analogous to that of the lymph node and spleen. It appears that haptens or antigens which are able to penetrate the stratum corneum into the avascular epidermis are then trapped by the "protective reticulum" of Langerhans cells (Shelley and Juhlin, 1976). Furthermore, the presence of Ia-antigens on the surface of such dendritic cells may be explained because of the



importance of genetic restriction in such antigens between antigen-presenting cells and responding lymphocytes. Conventional macrophages generally phagocytose larger molecules. These observations would be compatible with the suggested function of Langerhans cells in periodontitis. Langerhans cells are particularly well suited to be the first line of immunologic defense in the skin and chronic antigenic stimulation of the oral mucosa. Antigenic presentation rather than phagocytosis seems to be the major functional role the Langerhans cell plays in these reactions.

#### Langerhans Cells in Contact Dermatitis and Periodontitis

There is good evidence that Langerhans cells play an important role in allergic contact dermatitis of skin. Langerhans cells have been identified in close apposition (peripolexis) to mononuclear cells in the epidermis at sites of contact allergic hypersensitivity reactions (Silberberg 1976A). Apposition of Langerhans cells to mononuclear lymphocyte-like cells was not observed at sites of contact primary irritant reactions. Two to three hours after antigenic challenge with known contact allergens an increase in Langerhans cells in the dermis was noted (Silberberg 1973, 1975). Langerhans cells have been identified in the dermal lymphatics and in the draining lymph nodes subsequently after trapping antigens in the skin (Silberberg, 1976).

Although there appears to be a constant migration of Langerhans cells to lymph nodes in presumably nonreactive skin, the migration of both Langerhans cells and indeterminate dendritic cells (IDC's) from skin via dermal lymphatics to draining lymph nodes is much more readily seen at the site of challenge after topical or intradermal challenge of

antigen in sensitized guinea pigs than in normal control animals. This migration is multiplied by a factor of 3 to 7 in immunologically reactive skin (Silberberg-Sinakin and Thorbecke 1980).

Langerhans cells may have secretory functions involved in the contact hypersensitivity reactions (in which they have been described) Silberberg, 1973, Silberberg-Sinakin, 1976, Silberberg, 1975). A possible secretory function in regards to Langerhans cells function is related to the prostaglandin activity at sites of contact dermatitis and has been postulated. This activity is due to prostaglandins E and F (Goldyne et al., 1973, Greaves et al., 1971). The major portion of prostaglandin activity appears to be in the epidermis rather than in the dermis (Jouvenaz et al., 1970, Dorp et al., 1971). The mononuclear phagocyte has been suggested as the principal hemopoietic cell source of prostaglandin E (Kurland et al., 1977, Brune et al., 1978). The formation of vacuoles in macrophages, resembling those seen in Langerhans cells is reported to coincide with prostaglandin formation and has been postulated to be the end result of the fusion of different cell organelles and the ensuing increased contact of the enzymes with their respective substrates (Bruen et al, 1978). Therefore if Langerhans cells represent the mononuclear phagocyte system in the epidermis, they are likely to be an important source of prostaglandins in the skin. (Silberberg-Sirakin and Thorbecke, 1980).

There is evidence that activated macrophages are the major source of prostaglandins in diseased gingiva (Loning 1980). Little support has, however, been given to the prostaglandin activity of the Langerhans cell

and this area is clearly in need of further investigation.

In the present study increased number of Langerhans cells were shown to be present in the inflamed oral epithelium associated with periodontitis. This was compared to clinically normal epithelium which was treated by removal of bacteria laden calculus. The increased number of Langerhans cells in periodontitis suggests that there may be an immunologic response to plaque antigens.

Bos and Burkhardt (1980) demonstrated that when germ free mice developed an oral flora there was a concomitant increase in epithelial Langerhans cells. Newcomb et al., 1982 reported in four patients that as plaque accumulated there was a statistically significant increase in Langerhans cells in the oral epithelium. The results of these studies demonstrated a response of oral epithelial Langerhans cells elicited upon antigenic stimulation and agree with the results of the present study.

Keratinized oral epithelium such as that found in gingiva has been considered relatively impermeable to ingress of foreign antigens. However, certain dyes (Adams 1975) and radio-labelled substances (Haugen and Johansen 1975) have been shown to rapidly penetrate well into keratinized epithelium. It has been generally accepted that bacterial plaque antigens which accumulate on the tooth surface or directly on oral epithelium can also penetrate this tissue and elicit a host response. As the Langerhans cell has been shown to increase in numbers with an increased bacterial antigenic challenge and may play an integral role in the host response, suggests that they function in the pathogenesis of periodontitis.

In the present study, Langerhans cells were identified in the

lamina propria with all techniques utilized with the exception of ATPase due to staining of blood vessels and background staining. It was not determined if these cells were migrating towards the epithelium or back to regional lymph nodes carrying antigenic information. Although there appears to be a constant migration of Langerhans cells to lymph nodes in presumably nonreactive skin, the migration of both Langerhans cells and indeterminate dendritic cells (IDC's) from skin via dermal lymphatics to draining lymph nodes is much more readily seen at the site of challenge after topical or intradermal challenge of antigen in sensitized guinea pigs than in normal control animals. This migration is multiplied by a factor of 3 to 7 in immunologically reactive skin. Langerhans cells carrying antigen have been seen in dermal lymphatics as early as 2 hours after challenge. (Silberberg-Sinakin and Thorbecke, 1980).

The increase in Langerhans cell numbers in this study seems to be a result of migration from the connective tissue into the epithelium. Kinetic investigations of Langerhans cells have shown that a very small number of cells are capable of proliferation within the epidermis. This number may be as low as 2% (Gschnait and Brenner 1979). In the absence of overt pathology it is generally agreed that only molecules of low molecular weight may pass through skin. It is also generally agreed upon among periodontists that plaque bacteria do not penetrate the tissues during chronic periodontal disease processes. While bacteria have been reported in the gingiva, this occurrence is considered to be rare. Bacteria have been observed in gingival tissues associated with chronic periodontitis (Michel, 1969, Frank, 1972, Frank and Vogel, 1978) and in

juvenile periodontitis (Gillette and Johnson, 1982). However, the subsequent host immunologic activity most likely is in response to antigens or haptens of bacterial plaque origin including enzymes and components of the bacterial cell structure. Currently, reports suggest that the Langerhans cell may play a role in processing foreign molecules as previously discussed.

In the present study Langerhans cells were significantly shown to be present in increased numbers in clinically inflamed gingival epithelium when compared to clinically normal oral epithelium. In oral mucosa, it is not probable normally to develop sensitivity to a particular antigenic challenge; in fact one will develop tolerance. This is in contrast to the results of studies in allergic contact hypersensitivity of the skin. It is not sensible to explain these differences in host response in terms of different populations of cells. Rather, in the oral environment these antigenic processing cells of the epithelium are largely evaded because of the binding, cleansing and actual physical "sweeping away" by salivary glycoproteins as well as the various enzymatic reactions in these secretions to which antigens are subjected. These antigens are, however, carried into the gastrointestinal system where a suppressor mechanism is triggered.

In the case of chronic stimulation as produced when densely bacterial laden calculus attaches to a tooth surface, a strong host immunologic reaction may develop. In this situation the antigenic stimulation on contact with mucosa is present long enough due to the plaque and calculus density representing a depot effect as opposed to being washed

away by the physical actions of saliva. The chronic inflammation which ensues and the development of sensitivity to specific bacteria may be amplified when host defense mechanisms are altered. Studies have shown both T and B cells react to antigenic challenge by blast transformation, lymphokine production, and antibody production. Also, circulating antibodies specific for plaque organisms have been reported. Such observations support the concept of an immune response mechanism in periodontitis.

If bacterial products (i.e., endotoxin) gains access to oral tissues and presentation of the antigens by Langerhans cells takes place, there would be sensitization as opposed to suppression. In chronic periodontal disease states there is a depot effect of potential bacterial antigens. This has been documented as a transitional constantly changing bacterial flora (Listgarten and Hellen, 1978). The flora of chronic periodontal disease states has been documented as changing from a relatively innocuous Gram<sup>+</sup> nonmotile predominated to a destructive Gram<sup>-</sup> motile dominated situation. As the relative numbers of Gram<sup>-</sup> motile organisms increases along with increasing numbers of other potentially antigenic substances of the Gram<sup>-</sup> bacterial cell wall (i.e., endotoxin), the immunologic challenge is multiplied accordingly.

The increase in the numbers of Langerhans cells identified in clinically inflamed gingival tissues associated with periodontal disease in the present study may be in response to this increased immunologic challenge. This suggests that Langerhans cells are functional in the presentation of bacterial plaque antigens to T lymphocytes. The T lymphocytes then proliferate in a response to the specific bacterial plaque antigens

producing lymphokines and to help B cells to produce specific circulating antibodies directed against the antigens. This more significant role postulated for the Langerhans cell is compatible with what we now know about the host response in chronic periodontal disease.

The objectives of the present study were to determine which of the staining techniques if any were superior for the identification of Langerhans cells in human oral mucosa. It was determined that OKT-6 was qualitatively the best technique studied for this purpose. Another objective was to determine if there was a difference in the numbers of Langerhans cells present in chronically inflamed human gingiva associated with periodontitis and clinically normal tissue. Langerhans cells were shown to be significantly increased in the chronically inflamed tissues associated with periodontal disease and were found in numbers averaging as many as five times that found in clinically normal tissue.

## CHAPTER VI

### SUMMARY AND CONCLUSIONS

In the present study, eleven patients were selected who presented with chronic periodontitis and displayed moderate to severe gingival inflammation as assessed by the G.I. of Loe (1967). A sextant associated with clinically inflamed tissues was not treated, while the remaining teeth were scaled and root planed. Two gingival biopsies were taken; clinically normal treated, and clinically inflamed untreated tissue. Langerhans cells cannot be identified by H&E stained sections. Histochemical and immunocytochemical methods were used for staining and slides were examined under light microscopy.

In the present study Langerhans cells were specifically stained for ATPase (Wachstein and Meisel, 1957), HLA-DR (Rowden, 1977), S-100 Cocchia et al; 1981), and OKT6 (Murphy, 1982). Langerhans cells were quantitated using standardized grids in OKT6 stained sections. Approximately five times as many Langerhans cells were identified in the standardized sections of clinically inflamed human gingiva as in clinically normal gingiva of the same patient. This was shown to be a statistically significant increase ( $P = .01$ ).

All special stains tested were effective to some degree in demonstrating Langerhans cells in human gingival epithelium. Of the methods studied, OKT6 (Murphy, 1982) was qualitatively determined to be the



best technique for visualization of Langerhans cells under light microscopy. This technique would be recommended for future investigations concerning Langerhans cells in oral mucosa. The results also suggest that Langerhans cells may respond in chronic periodontitis by increasing in numbers possibly in response to dental plaque antigens. An immunologic role in the host response to chronic periodontal disease is postulated for Langerhans cells.

## REFERENCES

- Adams, D. The mucus barrier and absorption through the oral mucosa. J. Dent. Res. 1975; 54: Special Issue B, 19.
- American Academy of Periodontology: Current Procedural Terminology for Periodontics, 1977. ed. 4, p 11. Chicago, Am. Acad. Perio.
- Axelsson, S., Elofsson, R., Falck, B., Sjoborg; In vitro uptake of L. dopa and catecholamines into the epidermal Langerhans cell. Acta. Derm. Venereol 1978; 79:31.
- Bahn, A.K., Reinherz, E.L., Poppema, S., McCluskey, R.T., and Schlossman, S.F. Location of T cell and major histocompatibility complex antigens in the human thymus. J Exp Med 1980; 152:771-82.
- Balner, H.: Are D and DR antigens identical? A review of available data for man and the rhesus monkey. Transplant Proc. 1979; 11:657.
- Basset, F. and Turiaf, J. Identification par la microscopie electronique due particules de nature probablement virale dans les liasons graunulomatoeuses d'une histiocytose "X" pulmonaire. CR Acad. Sci. Paris 1965; 261:3701.
- Becker, S.W., Jr., Fitzpatrick, T.B., and Montgomery, H. Human melanogenesis; cytology and histology of pigment cells (melanodendrocytes). Arch. Dermatol. Syph. 1952; 65:511.
- Bell, M.: The Langerhans cells in the skin of subhuman primates: in Montagna W. and Hu, F. Advances in biology of skin. The pigmentary system, 1967; vol. 8 115. Pergamon Press, Oxford/New York..
- Berman, B., and France, D.S. Histochemical analysis of Langerhans cells. Am. J. Dermatopathol. 1979; 1:215.
- Birbeck, M.S., Breathnach, A.S., and Everall, J.D. An electron microscopic study of basal melanocytes and high level clear cells (Langerhans cells) in vitiligo, J. Invest Dermatol 1961; 37:51.
- Böck, E. Nervous system specific proteins. J. Neurochem. 1978; 30:7.
- Bos, I.R., and Burkardt, A.: Interepithelial cells of the oral mucosa. J. Oral Path. 1980; 9:65.

- Bos, I.R., and Burkhardt, A.: Epithelial and interepithelial mitoses of oral mucosa: light and electron microscopic study in mice after exposure to different antigens. J. Invest. Dermatol 1981; 76:63.
- Braathen, L.R., Berle, E., Mobeck-Hanssen, V., and Thorsby, E. Studies on human epidermal Langerhans cells. II. Activation of human T lymphocytes to herpes simplex virus. Acta. Derm. Venereol. 1980; 60:381.
- Bradshaw, M., Wachstein, M., Spence, J., and Elias, J.M. Adenosine triphosphatase activity in melanocytes and epidermal cells of human skin. J. Histochem. Cytochem. 1963; 11:465.
- Breathnach, A.S. A new concept of the relationship between Langerhans cells and the melanocyte. J. Invest. Derm. 1963; 40:279.
- Breathnach, A.S. Observations on cytoplasmic organelles in Langerhans cells of human epidermis. J. Anat. 1964; 98:265.
- Breathnach, A.S. The Cell of Langerhans. Int. Rev. Cytol. 1965; 18:1.
- Breathnach, A.S. Electron micrographs from a collection. Clin. Exp. Dermatol 1977; 2:1.
- Breathnach, A.S., Gross, M., Basset, F., and Nezelof, D.: Freeze fracture replication of X-granules in cells of cutaneous lesions of histiocytosis X (Letterer-Siwe disease). Br. J. Dermatol 1973; 89:571.
- Breathnach, S.M., and Katz, S. Ia antigen synthesis by keratinocytes and impaired Langerhans cells function in acute cutaneous GVH. J. Invest. Dermatol 1983; 80:314.
- Brune, K., Glatt, M., Kalin, H., and Peskar, B.A.: Pharmacological control of prostaglandin and thromboxane release from macrophages. Nature. 1978; 274:261.
- Bullough, W.S. and Lawrence, E. Epidermal chalone and mitotic control in VXQ epidermal tumor. Nature 1978; 220:134.
- Burkhardt, A. Interepithelial cell of the Oral Mucosa in Mice. Virchows Arch. A. Path. Anat. and Histol. 1979; 384:223.
- Cancilla, P.A., Lahye, M.E. and Carnes, W.H. Cutaneous lesions of Letterer-Siwe disease. Electron microscopic study. Cancer 1967; 20:1976.

- Caputo, R., Peluchetti, D., and Monti, M. Freeze-fracture of Langerhans granules. A comparative study. J. Invest. Dermatol 1976; 66:297.
- Carey, E.S. Am. J. Pathol. 1942; 18:237.
- Chu, A.C., Morgan, E.W. and MacDonald, D.M. An ultrastructural study of the mononuclear cell infiltrate of mycosis fungoides and poikilodema atrophicans vasculare. Clin. Exp. Dermatol 1982; 7:11.
- Chu, A., Berger, C.L., Kung, P. and Edelson, R.L. In situ identification of Langerhans cells in the dermal infiltrate of cutaneous T cell lymphoma. J. Amer. Acad. Dermatol 1982; 6:350.
- Chu, A., Eisinger, M., Lee, J.J., Takexaki, S., Kung, P.C. and Edelson, R.L. Immunoelectron microscopic identification of Langerhans cells using a new antigenic marker. J. Invest. Dermatol 1982; 78:177.
- Clark, W.H., Jr., Watson, M.C. and Watson, B.E.M. Two kinds of "clear" cells in the human epidermis; with a report of a modified DOPA reaction for electron microscopy. Am. J. Pathol. 1961; 39:333.
- Cocchia, D., Michetti, F. and Donato, R. Immunochemical and immunocytochemical localization of S-100 antigen in normal skin. Nature 1981; 294:85.
- Cotner, T., Mashimo, H., Kung, P.C., Goldstein, G., and Strominger, J.L. Human T cell surface antigens leaving a structural relationship to HLA antigens. Proc. Natl. Acad. Sci. 1981; 78:3858.
- Dannies, P.S. and Levine, L.: Structural Properties of Bovine Brain S-100 Protein. Journal of Biological Chemistry 1971;6276.
- David, C.S.: Serologic and genetic aspects of murine Ia antigens. Transplant Revs. 1976; 30:299.
- Daynes, R.A., Emans, M., Krueger, G.G. and Robats, L.K. Expression of Ia antigen on epidermal keratinocytes after grafting normal human skin to nude mice. J. Immunol 1983; 120:1531.
- DeDuve, C., and Wattiaux, R.: Functions of lysosomes. Ann. Rev. Physiol. 1966; 28:435.
- Dorp, D.A. van: Recent developments in the biosynthesis and the analyses of prostaglandins. Ann. N.Y. Acad. Sci. 1971; 180:181.

- Drexhage, H.A., Mallink, H., Degroot, J., Clarke, J., and Balfour, B.M. A study of cells present in peripheral lymph of pigs with special reference to a type of cell resembling the Langerhans cell. Cell Tissue Res. 1979; 202:407.
- Dubertret, L., Picard, O., Bagot, M., Tulliez, M., Fosse, M., Aubert, C., and Touraine, R. Specificity of monoclonal antibody anti-T 6 for Langerhans cells in normal human skin. Brit. J. Dermatol 1982; 106:287.
- Elleder, M.: Activity of a D-mannose in human Langerhans epidermal cells. Virchows Arch. (Zellpathol) 1975; 19:93.
- Evans, R.L., Faldetta, T.J., Humphreys, R.E., Pratt, D.M., Yunis, E.J., and Schlossman, S.F. Peripheral human T cells in mixed lymphocyte culture synthesize and express Ia-like antigens. J. Exp. Med. 1978; 148:1440.
- Falck, B., Agrup, G., Jacobsson, S., et al. Uptake of L dopa and functionally related aromatic amino acids into the Langerhans cells. J. Invest. Dermatol 1976; 66:265.
- Ferreira-Marques, J. Systems sensitium intra-epidermicum. Die Langerhanshen Zellen als Rexeptorem des hellen Schmerzes: Doloriceptors. Arch. Dermatol. Syph. 1951; 193:191.
- Fithian, E., Kung, P., Goldstein, G., Rubenfeld, G., Fenoglio, D., and Edelson, R. Reactivity of Langerhans cells with hybridoma antibody. Proc. Natl. Acad. Sci. 1981; 78:2541.
- Frank, R.M. Apposition et resorption de l'os alvcolaire. Revue d'Orthopedie Dento-Faciale. 1971; 6:201.
- Frank, R.M. and Voegel, J.C. Bacterial bone resorption in advanced cases of human periodontitis. J. Perio. Res. 1978; 13:251.
- Gillett, R., and Johnson, N.W. Bacterial invasion of the periodontium in a case of juvenile periodontitis. J. Clin. Perio. 1982; 9:93.
- Goldyne, M.E., Winkelmann, R.K. and Ryan, R.J. Prostaglandin activity in human cutaneous inflammation detection by radioimmunoassay. Prostaglandins. 1973; 4:737.
- Greaves, M.W., Sandergaard, J., and McDonald-Gibson, W. Recovery of prostaglandins in human cutaneous inflammation. Br. Med. J. 1971; 2:258.

- Gschnait, F., and Brenner, W. Kinetics of epidermal Langerhans cells. J. Invest. Dermatol. 1979; 73:566.
- Hansson, H-A., Persson, L., Ronnback, L. and Haglid, K.G.: Immuno-electron microscopic study of the distribution of the S-100 protein in brain glial cells. Cytobios 1976; 15:45.
- Harrist, T.J., Muhlbauer, J.E., Murphy, G.F., Hihm, M.C. and Bhan, A.K. T6 is Superior to Ia (HLA-DR) as a Marker for Langerhans Cells and Indeterminate Cells in Normal Epidermis: A Monoclonal Antibody Study. J. Lab. Invest. 1983; 80:100.
- Hashimoto, K. and Tarnowski, W.M. Some new aspects of the Langerhans cell. Arch. Dermatol 1968; 97:450.
- Hauger, E. and Johansen, J.R. Penetration of the oral mucosa by radiolabelled chlorhexidine in guinea pigs. Acta Odontologica Scandinavica 1975; 33:365.
- Hill, M.W. Histology of Langerhans cell in neonatal rat palatal mucosa. Archives of Oral Biology. 1977; 22:641.
- Hoefsmid, E.C.M., Duijvestijn, A.M., and Kamperdisk, E.W.A. Relation between Langerhans cells, veiled cells and interdigitating cells. Immunobiol 1982; 161:255.
- Hoefsmid, E.C.M., Kampedijk, E.W.A., Hendriks, H.R., Beelen, R.H. and Balfour, B.M. "Lymph node macrophages" in The reticuloendothelial system. (Eds. I. Carr and W.T. Daems) Plenum Press, N.Y. 1980; 1:417.
- Hoshino, T., Kukita, A., and Sato, S. Cells containing Birbeck granules (Langerhans granules) in human thymus. J. Electron Micr. 1970; 19:271.
- Hsu, S.M., Raine, L., and Ganger, H. The use of avidin-biotinperoxidase complex (ABC) in immunoperoxidase techniques. A comparison between ABC and unlabelled antibody (APA) procedures. J. Histochem. Cytochem. 1981; 29:577.
- Hutchens, L.M., Sagebiel, R.W., and Clarke, M.A. Oral epithelial dendritic cells of the Rhesus monkey - histologic demonstration, fine structure and quantitative distribution. J. Invest. Dermatol 1971; 56:325.
- Hyden, H., and McEwen, B.S. A glial protein specific for the nervous system. Proc Nat Acad Sci. 1966; 55:354.

- Iggo, A., and Muir, A.R. The structure and function of slowly adapting touch corpuscles in hairy skin. J. Physiol. (Paris) 1969; 200:763.
- Imamura, M., Sakamoto, S., and Hazazono, H. Malignant histiocytosis: A case of generalized histiocytosis with infiltration of Langerhans granule containing histiocytes. Cancer 1978; 28:267.
- Jarrett, A., and Riley, P.A. Esterase activity in dendritic cells. Br. J. Dermatol 1963; 75:79.
- Jouvenaz, G.H., Nugteren, D.H., Beerthuis, R.K., and Dorp, D.A. van. A sensitive method for the determination of prostaglandins by gaschromatography with electron-capture detection. Biochem Biophys Acta. 1970; 202:231.
- Katz, S.I. The role of Langerhan's cells in immunity. Arch Dermatol 1980; 116:1361.
- Klareskog, L., Tjernlund, U.M., Forsum, U., and Peterson, P.A. Epidermal Langerhans cells express Ia antigens. Nature 1977; 26:248.
- Klee, C.B., Crouch, T.H. and Richman, P.G.A. Calmodulin. Rev. Biochem 1980; 49:489.
- Kondo, Y. Macrophages containing Langerhans cells granules in normal lymph nodes of the rabbit. Z. Zellforsch. 1969, 98:506.
- Kurland, J., and Moore, M.A.S. Regulatory role of the macrophage in normal and neoplastic hemapoiesis, "Experimental Hematology Today." Edited by S. Baum, G. Ledney. New York Springer Verlag. 1977; 51.
- Lampert, I.A., Sutters, A.J., and Chisholm, P.M. Expression of Ia antigen on epidermal keratinocytes in GVH disease. Nature 1981; 293:149.
- Langerhans, P. Über die Nerven der menschlichen Haut. Virchows Arch. Path. Anat. Physiol. 1868; 44:325.
- Lessard, R., Wolff, K., and Winklemann, R.K. The disappearance and regeneration of Langerhans cells following epidermal injury. J. Invest. Dermatol 1968; 50:171.
- Listgarten, M.A. Normal development, structure, physiology and repair of gingival epithelium. Oral Sci. Rev. 1972; 1:3.

- Listgarten, M.A., and Heller, R. Relative distribution of bacteria at clinically healthy and periodontally diseased sites in humans. J. Clin. Perio. 1978; 5:115.
- Loe, H. The Gingival Index, the Plaque Index, and the Retention Index Systems. J. of Perio. 1967; 38:610.
- Loe, H., and Silness, J. Periodontal disease in pregnancy. I. Prevalence and severity. Acta. Odontol. Scand. 1963; 21:533.
- Loning, T.H., Albert, H.S., Lisbon, B.P., Burkhardt, A., and Caselitz, J. Prostaglandin E and local immune response in chronic periodontal disease. J. Perio. Res. 1980; 15:525.
- Mackenzie, I.C.. Relationship between mitosis and the ordered structure of the stratum corneum in mouse epidermis. Nature (London) 1970; 226:653.
- Mackenzie, I.C. and Squier, C.A. Cytochemical identification of ATPase positive Langerhans cells in EDTA separated sheets of mouse epidermis. Br. J. Dermatol 1975; 92:523.
- Masson, P. My conception of cellular naevi. Cancer 1951; 4:9.
- McDevitt, H.O., Delovitch, T.L., Press, J.L., and Murphy, D.G. Genetic and functional analysis of the Ia antigens. Their possible role in regularizing the immune response. Transplant. Rev. 1976; 30:197.
- Michel, C. Etudes ultrastructurale de l'os alveolaire av cors des parodontdyses. Parodontologie 1969; 23:191.
- Mishima, Y., and Miller-Millinska, A. Junctional and high-level dendritic cells revealed with osmium iodide reaction in human and animal epidermis under conditions of hyper pigmentation and depigmentation. J. Invest Dermatol 1961; 37:107.
- Moore, B.W. A soluble protein characteristic of the nervous system. Biochem. Biophys. Res. Comm. 1965; 19:739.
- Moretta, L., Ferrarini, M., Mingari, M.C., et al. Subpopulations of human T cells identified by receptors for immunoglobulins and mitogen responsiveness. J. Immunol 1976; 117:2171.
- Murphy, G.F., Bhan, A.K., Sato, S., Mihm, M.C. Jr., and Harrist, T.J. A new immunologic marker for human Langerhans cells. N. Engl. J. Med. 1981; 304:791.



- Murphy, G.F., Bhan, A.K., Harrist, T.J., and Mihm, M.C., Jr. Identification of indeterminate cells in normal human dermis by means of the use of monoclonal anti-T6 antibody. Lab Invest. 1982; 46:60A.
- Mustakallio, K. Adenosine triphosphatase activity in elements of human epidermis. Exp. Cell Res. 1963; 28:449.
- Nakajima, T., Watanabe, S., Sato, Y., Shimosato, Y., Motoi, M., and Lennert, K. S-100 protein in Langerhans cells, interdigitating reticulum cells and histiocytosis X cells. Gann. 1982; 73:431.
- Newcomb, G.M., Seymour, G.J., and Powell, R.N. Association between plaque accumulation and Langerhans cell numbers in the oral epithelium of attached gingiva. J. Clin Perio. 1982; 9:197.
- Niebauer, G., Krawczyk, W.S., Kiff, R.L., and Wilgram, G.F.: Osmium zinc oxide reactive sites in epidermal Langerhans cell. J. Cell Biol. 1969; 43:80.
- Niebauer, G., and Sekido, N. Über die Dendritenzellen der Epidermis. Eine Studie über die Langerhans - Zellen in der normalen and ekzematosen Haut des Meech - Weinchens. Arch. Klin. Exp. Dermatol 1965; 22:23.
- Pickler, W.J., and Knapp, W.: Receptors for IgM on human B lymphocytes. Scand J. Immunol 1978; 7:105.
- Potten, C.S.: The epidermal proliferative unit: The possible role of the central basal cell. Cell. Tiss. Kinet. 1974; 7:77.
- Potten, C.S., and Allen, T.K. A model implicating the Langerhans cell in keratinocyte proliferation control. Differentiation 1976; 5:43.
- Reinherz, E.L., and Schlossman, S.F. Regulation of the immune response-inducer and supressor T-lymphocyte subsets in human beings. N. Engl. J. Med. 1980; 303:370.
- Robins, P.G., and Brandon, D.R. A modification of the adenosine triphosphatase method to demonstrate epidermal Langerhans cells. Stain Technol 1981; 56:87.
- Rosenthal, A.S. Determinant selection and macrophage function in genetic control of the immune response. Transplant Rev. 1978; 40:136.
- Rosenthal, A.S. Determinant selection and macrophage function in genetic control of the immune response. Immunol. Rev. 1978; 40:135.

- Rosenthal, A.S. Determinant selection and macrophage function in genetic control of the immune response. Transplant Rev. 1978; 40:136.
- Rowden, G. Immuno-electron microscopic studies of surface receptors and antigens of human Langerhans cells. Br. J. Dermatol 1977; 97:593.
- Rowden, G. Expression of Ia antigens on Langerhans cells in mice, guinea pigs and man. J. Invest. Dermatol 1980; 75:22.
- Rowden, G., Misra, B., Higley, H., and Howard, R. Antigens specified by the TIIa locus are expressed on the surface of murine Langerhans cells. J. Invest Dermatol 1983a; June.
- Rowden, G., Connelly, H.T., and Winkelmann, R.K. Cutaneous histiocytosis X. The presence of S-100 protein and its use in diagnosis. Arch. Dermatol 1983b; July.
- Sagebiel, R.W., and Reed, T.H. Serial reconstruction of the characteristic granule of the Langerhans cell. J. Cell Biol. 1968; 36:595.
- Sasazuki, T., McDevitt, H.O., and Groumet, F.C. The association between genes in the major histocompatibility complex and disease susceptibility. Ann. Rev. Med. 1977; 28:425.
- Schroeder, H.E. and Theilade, J. Electron microscopy of normal human gingival epithelium. J. Perio. Res. 1966; 1:95.
- Shah, K.H., More, N.S., Queen, W., Runshock, E., and Rowden, G. Langerhans cells in dermoid cysts: transmission electron microscopic, cytochemical and immunofluorescent observations. J. Cutan. Pathol. 1981; 8:52.
- Shamoto, M., Hoshino, M., and Suchi, T. Cells containing Langerhans cell granules in human lymph nodes of "atypical hyperplasia" with fatal outcome and leukemic reticuloendotheliosis. Acta. Pathol. Jap. 1976; 26:311.
- Shelley, W.B., and Juhlin, L. Langerhans cells form a reticulo-epithelial trap for external contact antigens. Nature 1976; 261:46.
- Silberberg, I., Baer, R.L., Rosenthal, S.A., Thorbecke, G., and Berezowsky, V. Langerhans cells in skin, lymphatic - like vessels and draining lymph nodes in allergic contact sensitivity. Clin. Res. 1975; 23:231.

- Silberberg, I., Baer, R.L., Rosenthal, S.A., Thorbecke, G.J., and Berezowsky, V. Dermal and intravascular Langerhans cells at sites of passively induced allergic contact hypersensitivity. Cell Immunol 1975; 18:435.
- Silberberg-Sinakin, I., Thorbecke, G.J., Baer, R.L., Rosenthal, S.A., and Berezowsky, V. Antigen-bearing Langerhans cells in skin, dermalymphatics and in lymph nodes. Cell Immunol 1976; 25:137.
- Silberberg, I. Apposition of mononuclear cells to Langerhans cells in contact allergic reactions. An ultrastructural study. Acta Dermatol Venerol 1973; 53:1.
- Silberberg, I., Baer, R.L., and Rosenthal, S.A. The role of Langerhans cells in allergic contact hypersensitivity: A review of findings in man and guinea pigs. J. Invest Dermatol 1976; 66:210.
- Sjoberg, S., Axelsson, S., Falek, B., et al. A new method for the visualization of epidermal Langerhans cell and its application on normal and allergic skin. Acta Dermatol Venerol 1978; 79:23.
- Squier, C.A. and Waterhouse, J.P. The ultrastructure of the melanocyte in human gingival epithelium. Arch Oral Biol. 1967; 12:119.
- Stefansson, K., Wollmann, R.L., and Moore, B.W. Distribution of S-100 protein outside the central nervous system. Brain Res. 1982; 234:309.
- Sternberger, L.A. Immunocytochemistry, 2nd edit. Wiley, New York. 1979.
- Sternberger, L.A., Hardy, P.H., Jr., Cuculis, J.S., and Meyer, H.G. The unlabeled antibody enzyme method of immunohistochemistry. J. Histochem. Cytochem. 1970; 18:315.
- Stingl, G., Katz, S.I., Green, I., and Shevach, E.M. The functional role of Langerhans cells. J. Invest Dermatol 1980; 75:315.
- Stingl, G., Katz, S.K., Clement, L., et al. Immunologic functions of Ia-bearing epidermal Langerhans cells. J. Immunol 1978; 121:2005.
- Stingl, G.L., Wolf-Schreiner, T.C., Pichler, W.J., Gschnaist, F., Knapp, W., and Wolff, K. Epidermal Langerhans cells bear Fc and C<sub>3</sub> receptors. Nature 1977; 268:245.
- Stingl, G., Tamaki, K., and Katz, S.I. Origin and function of epidermal Langerhans cells. Immunol Rev. 1980; 53:149.

- Streilein, J.W. and Bergstresser, P.R. Ia antigens and epidermal Langerhans cells. Transplantation. 1980; 30:319.
- Sviridor, S.M., Korochkin, L.I., Ivanov, V.N., Maletskaya, E.I., and Bakhtina, T.K. Immunohistochemical studies of S-100 protein during post-natal ontogenesis of brain of two strains of rats. J. Neurochem. 1972; 19:713.
- Szabo, G. The regional anatomy of the human integument with special reference to the distribution of hair follicles, sweat glands, and melanocytes. Roy. Soc. London Phil. Trans. B. 1967; 252:447.
- Takahashi, K., Jamaguchi, H., Ishizeki, T., Nakajima, T., and Nakazato, Y. Immunohistochemical and immuno-electron microscopic localization of S-100 protein in the interdigitating reticulum cells of human lymph nodes. Virchows Arch. Pathol 1981; 37:125.
- Tamaki, K., Stingl, G., and Katz, S.I. The origin of Langerhans cells. J. Invest Dermatol 1980; 74:309,
- Terhorst, C., Van Agthoven, A., LeClaire, K., Snow, P., Reinherz, E., and Scjlossman, S.F. Biochemical studies of the human thymocyte cell-surface antigens T6, T9 and T10. Cell Biol 1981; 23:771.
- Thorbecke, G.J., Silberg-Sinakin, I., and Flotte, T.J. Langerhans cells as macrophages in skin and lymphoid origins. J. Invest Dermatol 1980; 75:32.
- Tjernlund, U.M. Epidermal expression of HLA-DR antigen in mycosis fungoides. Arch Dermatol Res 1978; 261:81.
- Tjernlund, U.M. Ia-like antigens in lichen planus. Acta Dermatol Venerol 1980; 60:309.
- Van Agthoven, A., and Terhorst, C. Further biomechanical characterization of the human thymocyte differentiation antigen T6. J. Immunol 1982; 128:426.
- Varon, S.S., and Somjen, G.G. Neuron-glial interactions. Neurosci. Res. Prog. Bull. 1979; 17:1.
- Veldman, J.E., and Kaiserling, E. "Interdigitating cells: in The reticuloendothelial system, Vol. 1 (Eds. I. Carr and W.T. Daems) 11:381-416. Plenum Publishers, New York. 1980.
- Wachstein, M., Meisal, E., and Niedwiedz, A. Histochemical demonstration of mitochondrial adenosine triphosphatase with the lead adenosine triphosphates technique. J. Histochem. Cytochem. 1960; 8:387.

- Weinmann, J.P. and Meyer, J. Types of keratinization in human gingiva.  
J. Invest Dermatol 1959; 32:87.
- Wolff, K. The Langerhans cell. Current Problems in Dermatology.  
1972; 4:79.
- Wolff, K. The fine structure of the Langerhans cell granule.  
J. Cell Biol 1967; 35:468.
- Wolff, K., and Schreiner, E. Uptake, intracellular transport and degradation of exogenous protein by Langerhans cells. An electron microscopic cytochemical study using peroxidase as tracer substance. J. Invest Dermatol 1970; 54:37.
- Wolff, K., and Sollereeder, B. Intranuclear and extracellular Langerhans cell granules. J. Invest Dermatol 1969; 52:424.
- Wong, Y.C., and Buck, R.D. Langerhans cells in epidermoid metaplasia.  
J. Invest Dermatol 1971; 56:10.
- Zelickson, A.S. The Langerhans Cells. J. Invest Dermatol  
1165; 44:201.
- Zelickson, A.S. Granule formation in the Langerhans cells.  
J. Invest Dermatol 1966; 47:498.
- Zelickson, A.S., and Mottaz, J.H. Localization of gold chloride and adenosine triphosphatase in human Langerhans cells.  
J. Invest Dermatol 1968; 51:365.

APPENDIX

TABLES - FIGURES



## APPENDIX

TABLE 2 - Specimen #1 Clinically Inflamed  
Nuclei of Epithelial Langerhans Cells Identified in Each  
0.13 mm<sup>2</sup> Microscopic Field - 50 Fields Examined  
(Section Prepared by OKT-6 Technique and Observed at 400X)

0	0	1	2	2
0	0	1	2	2
0	0	1	2	2
0	0	1	2	2
0	0	1	2	2
0	0	1	2	2
0	1	1	2	3
0	1	1	2	3
0	1	2	2	3
0	1	2	2	3





## APPENDIX

TABLE 4 - Specimen #2 Clinically Inflamed  
Nuclei of Epithelial Langerhans Cells Identified in  
Each 0.13 mm<sup>2</sup> Microscopic Field - 60 Fields Examined  
(Section Prepared by OKT-6 Technique and Observed at 400X)

0	0	1	2	3
0	1	1	2	3
0	1	1	2	3
0	1	2	2	3
0	1	2	2	4
0	1	2	2	
0	1	2	2	
0	1	2	2	
0	1	2	3	
0	1	2	3	

## APPENDIX

TABLE 5 - Specimen #3 Clinically Normal  
Nuclei of Epithelial Langerhans Cells Identified in  
Each 0.13 mm<sup>2</sup> Microscopic Field - 36 Fields Examined  
(Section Prepared by OKT-6 Technique and Observed at 400X)

0	0	0	2
0	0	0	2
0	0	0	2
0	0	0	2
0	0	1	2
0	0	1	2
0	0	1	
0	0	1	
0	0	1	
0	0	1	

## APPENDIX

TABLE 6 - Specimen #3 Clinically Inflamed  
Nuclei of Epithelial Langerhans Cells Identified in  
Each 0.13 mm<sup>2</sup> Microscopic Field - 52 Fields Examined  
(Section Prepared by OKT-6 Technique and Observed at 400X)

0	0	0	1	2	2
0	0	0	1	2	2
0	0	0	1	2	
0	0	0	1	2	
0	0	1	1	2	
0	0	1	1	2	
0	0	1	2	2	
0	0	1	2	2	
0	0	1	2	2	
0	0	1	2	2	

## APPENDIX

TABLE 7 - Specimen #4 Clinically Normal  
 Nuclei of Epithelial Langerhans Cells Identified in  
 Each 0.13 mm<sup>2</sup> Microscopic Field - 56 Fields Examined  
 (Section Prepared by OKT-6 Technique and Observed at 400X)

0	0	0	0	0	0	1
0	0	0	0	0	0	1
0	0	0	0	0	0	1
0	0	0	0	0	1	1
0	0	0	0	0	1	2
0	0	0	0	0	1	2
0	0	0	0	0	1	
0	0	0	0	0	1	
0	0	0	0	0	1	
0	0	0	0	0	1	



## APPENDIX

TABLE 9 - Specimen #5 Clinically Normal  
Nuclei of Epithelial Langerhans Cells Identified in  
Each 0.13 mm<sup>2</sup> Microscopic Field - 28 Fields Examined  
(Section Prepared by OKT-6 Technique and Observed at 400X)

0	0	0
0	0	0
0	0	0
0	0	0
0	0	0
0	0	1
0	0	1
0	0	
0	0	
0	0	

## APPENDIX

TABLE 10 - Specimen #5 Clinically Inflamed  
Nuclei of Epithelial Langerhans Cells Identified in  
Each 0.13 mm<sup>2</sup> Microscopic Field - 28 Fields Examined  
(Section Prepared by OKT-6 Technique and Observed at 400X)

0	0	1
0	0	1
0	0	1
0	0	1
0	1	2
0	1	2
0	1	2
0	1	2
0	1	
0	1	



## APPENDIX

## TABLE 11 - Specimen #6 Clinically Normal

Nuclei of Epithelial Langerhans Cells Identified in  
Each 0.13 mm<sup>2</sup> Microscopic Field - 46 Fields Examined  
(Section Prepared by OKT-6 Technique and Observed at 400X)

0	0	0	0	1
0	0	0	0	1
0	0	0	0	1
0	0	0	0	1
0	0	0	0	1
0	0	0	0	1
0	0	0	0	
0	0	0	0	
0	0	0	0	
0	0	0	1	

## APPENDIX

TABLE 12 - Specimen #6 Clinically Inflamed  
Nuclei of Epithelial Langerhans Cells Identified in  
Each 0.13 mm<sup>2</sup> Microscopic Field - 28 Fields Examined  
(Section Prepared by OKT-6 Technique and Observed at 400)

0	0	1
0	0	1
0	0	2
0	0	2
0	1	2
0	1	2
0	1	2
0	1	2
0	1	
0	1	

## APPENDIX

TABLE 13 - Specimen #7 Clinically Normal  
Nuclei of Epithelial Langerhans Cells Identified in  
Each 0.13 mm<sup>2</sup> Microscopic Field - 28 Fields Examined  
(Section Prepared by OKT-6 Technique and Observed at 400X)

0	0	1
0	0	1
0	0	1
0	0	1
0	0	1
0	0	2
0	0	2
0	0	2
0	0	
0	1	

## APPENDIX

TABLE 14 - Specimen #7 Clinically Inflamed  
Nuclei of Epithelial Langerhans Cells Identified in  
Each 0.13 mm<sup>2</sup> Microscopic Field - 42 Fields Examined  
(Section Prepared by OKT-6 Technique and Observed at 400X)

0	1	2	2	3
0	1	2	2	
0	1	2	2	
0	1	2	2	
0	1	2	2	
0	1	2	2	
0	1	2	3	
0	1	2	3	
0	1	2	3	
1	2	2	3	

## APPENDIX

TABLE 15 - Nuclei of Epithelial Langerhans Cells Anticipated in 1.0 mm<sup>2</sup> Microscopic Fields Prepared by the OKT-6 Technique and Observed at 400X

Number of Langerhans Cell/ 1 mm<sup>2</sup>

<u>Specimen</u>	<u>Clinically Normal</u>	<u>Clinically Inflamed</u>
1	1.3	7.5
2	2.5	8.7
3	3.0	5.5
4	3.0	9.8
5	1.8	6.25
6	0.5	4.5
7	1.0	5.0

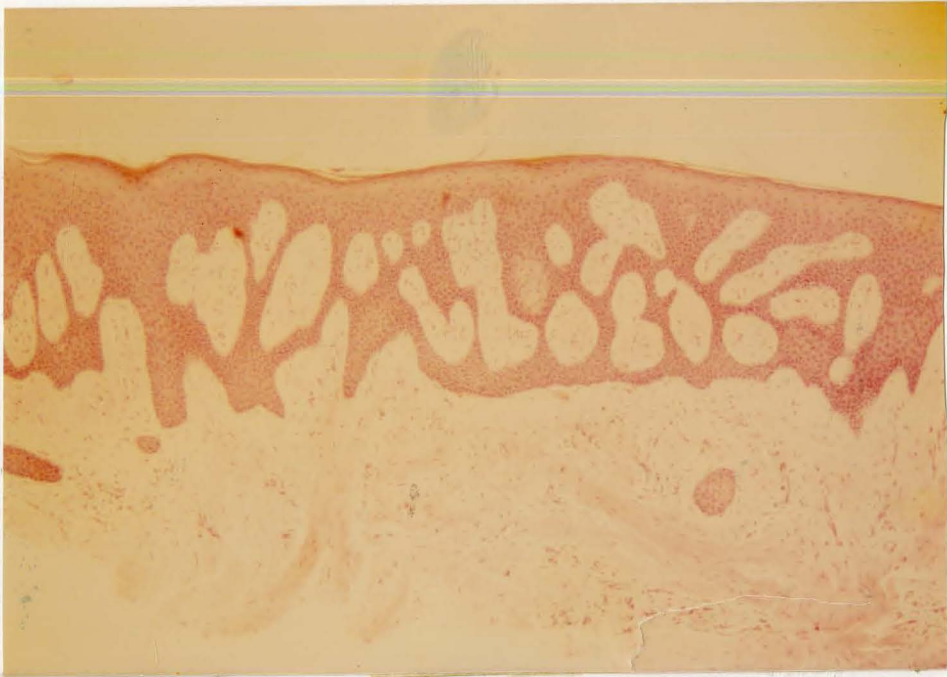

Figure 1. Hematoxylin and Eosin (Clinically Normal) 2.5X

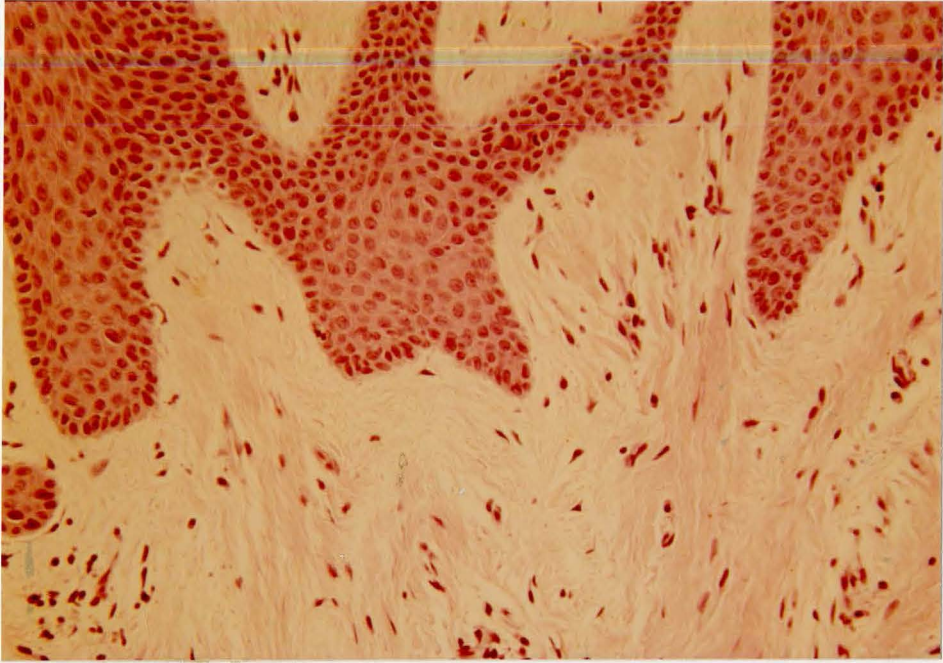


Figure 2. Hematoxylin and Eosin (Clinically Normal) 10X

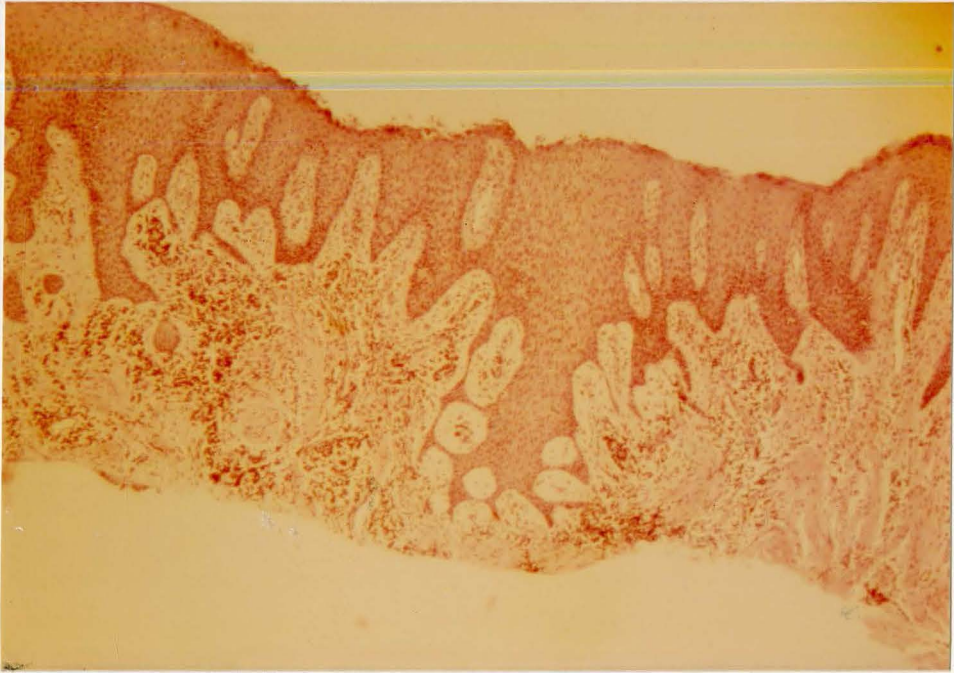


Figure 3. Hematoxylin and Eosin (Clinically Inflamed) 2.5X



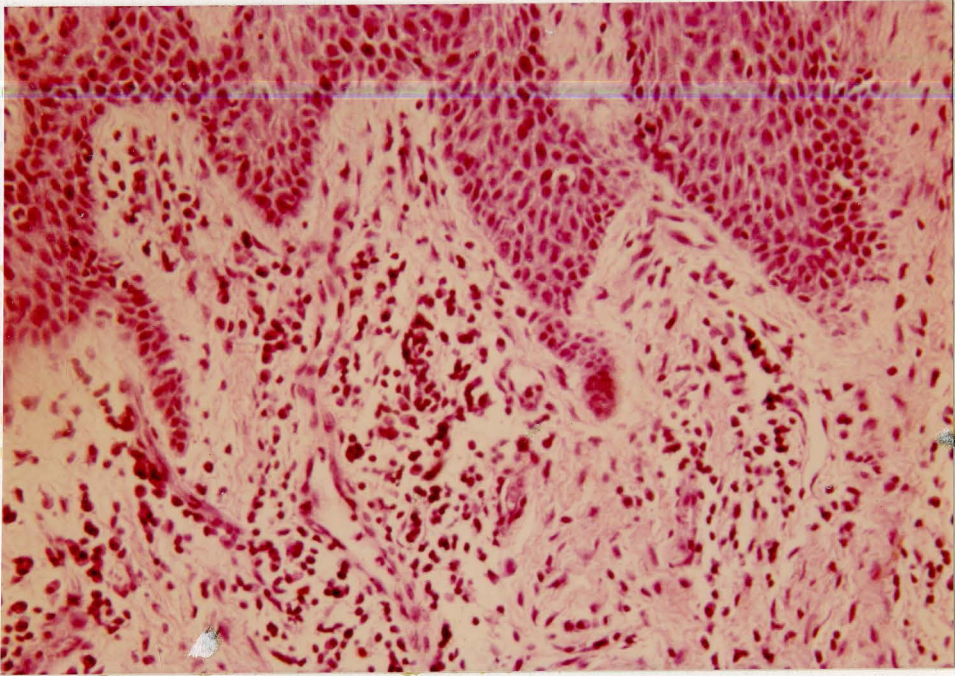


Figure 4. Hematoxylin and Eosin (Clinically Inflamed) 10X

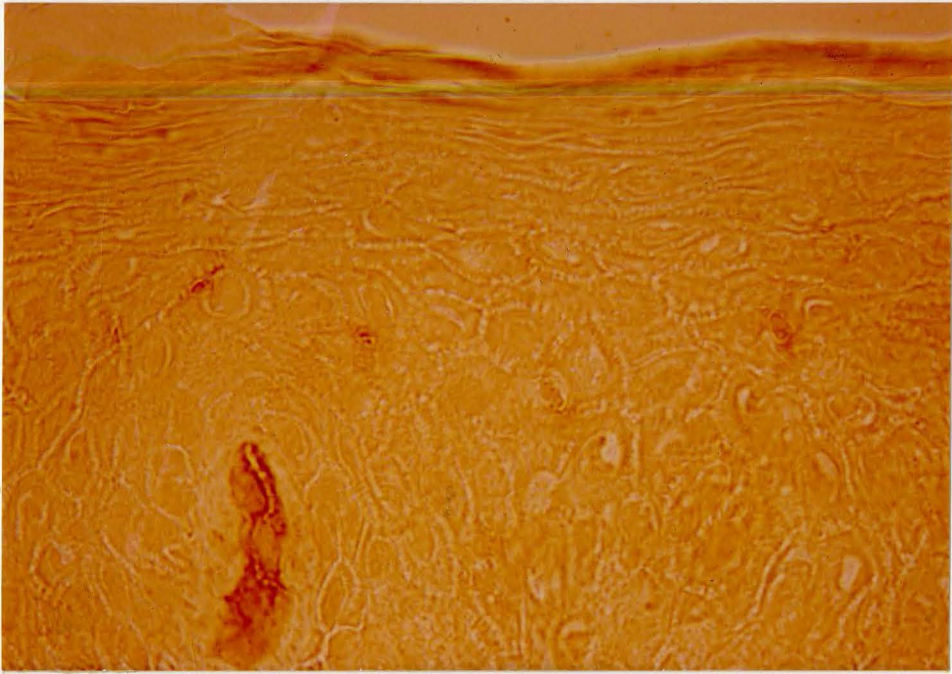


Figure 5. ATPase (Robins and Brandon, 1981)  
(Clinically Inflamed) 25X

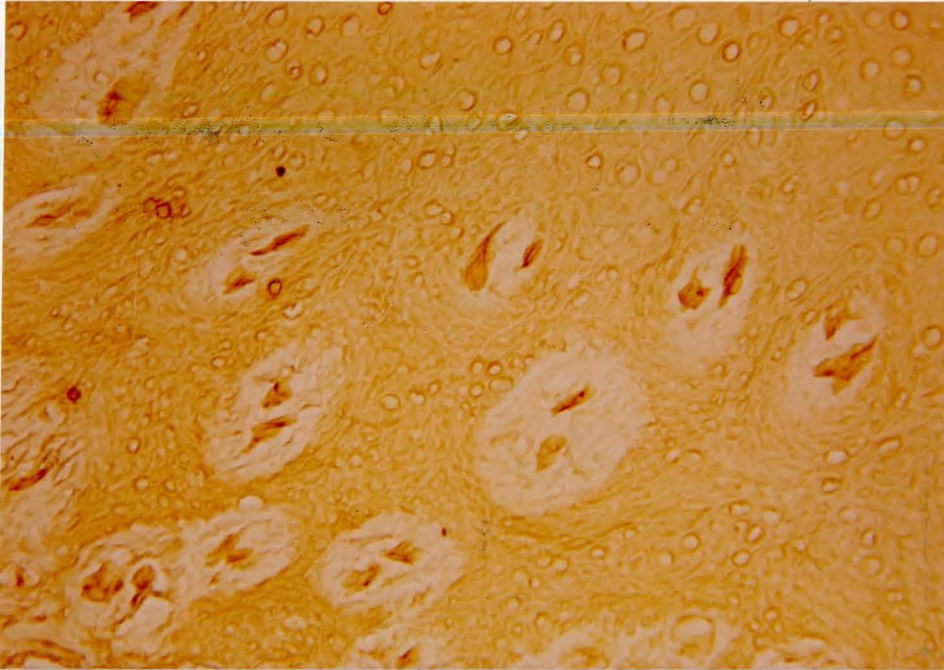


Figure 6. ATPase (Robins and Brandon, 1981)  
(Clinically Inflamed) 250X

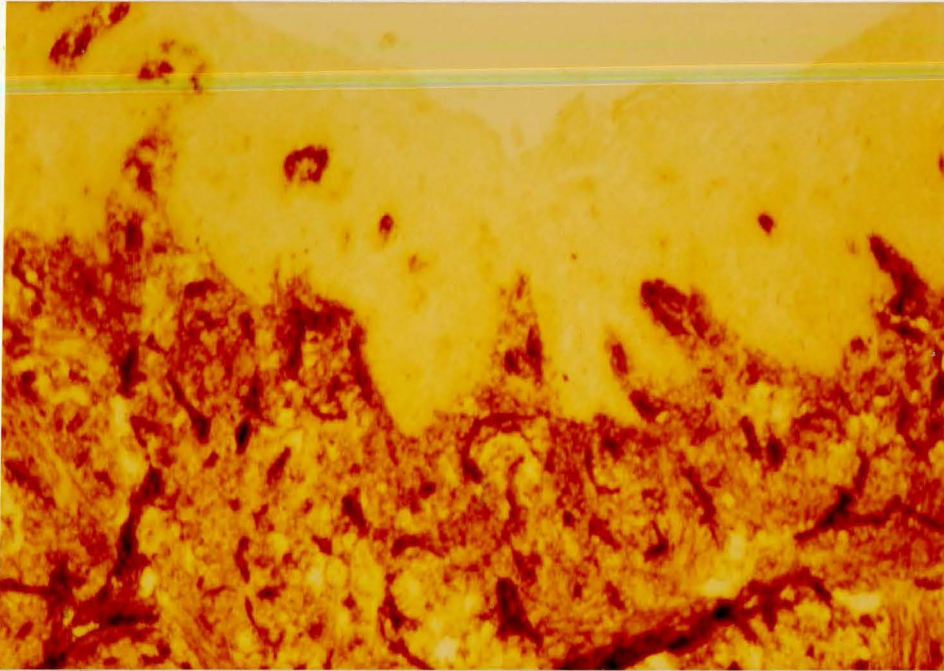


Figure 7. ATPase (Wachstein and Meisel, 1960)  
(Clinically Normal) 2.5X

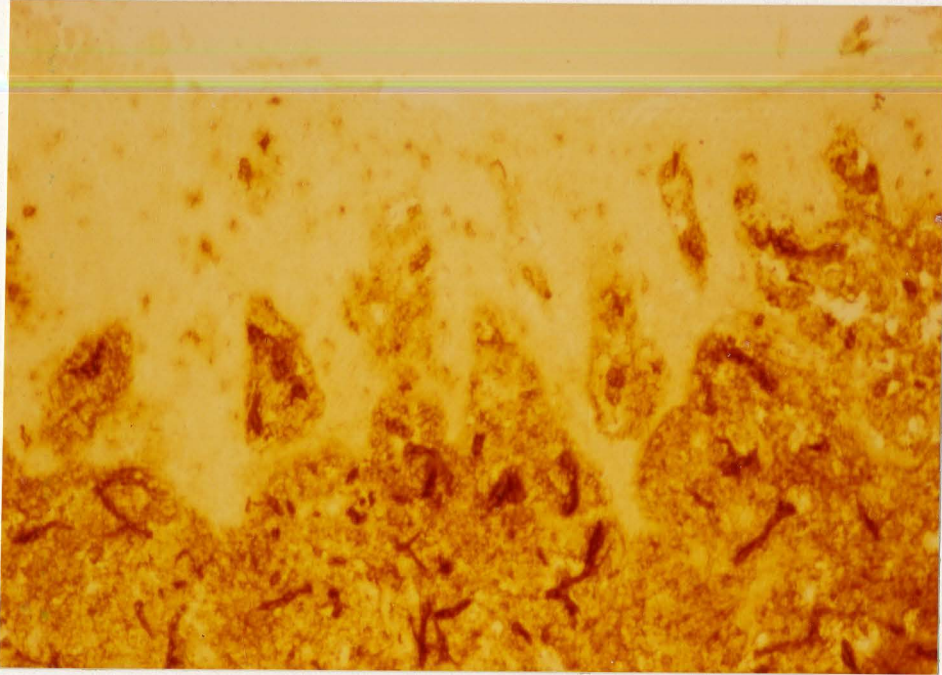


Figure 8. ATPase (Wachstein and Meisel, 1960)  
(Clinically Inflamed) 2.5X

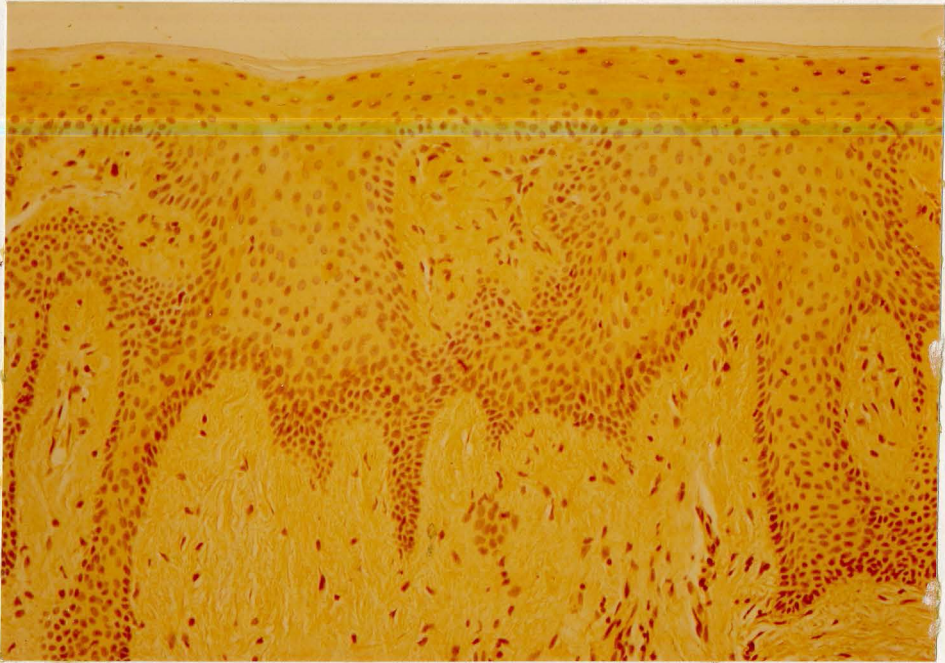


Figure 9. S-100 Protein (Clinically Normal) 2.5X

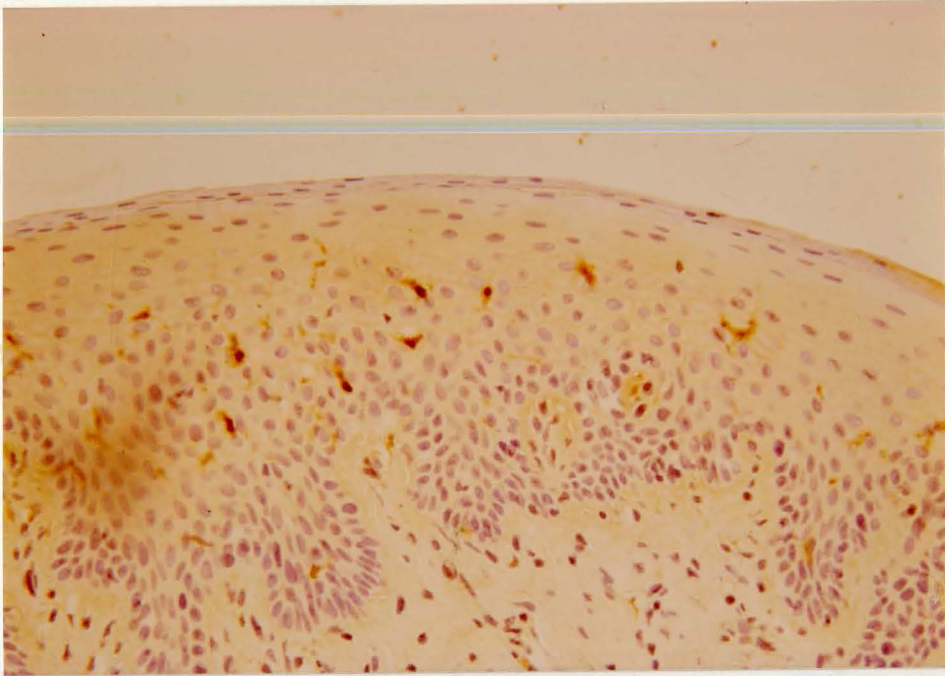


Figure 10. S-100 Protein (Clinically Inflamed) 2.5X

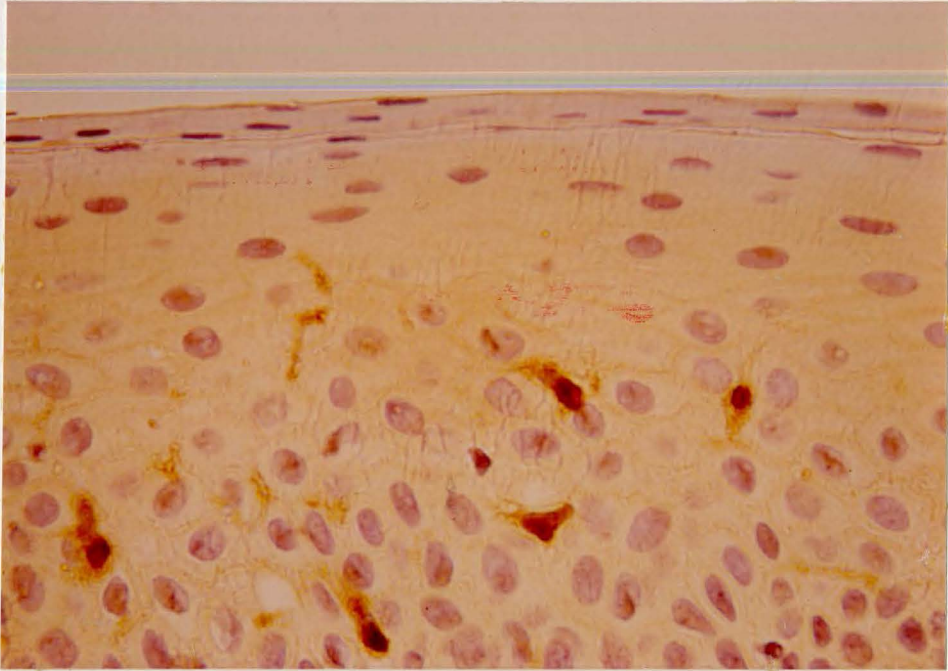


Figure 11. S-100 Protein (Clinically Inflamed) 250X



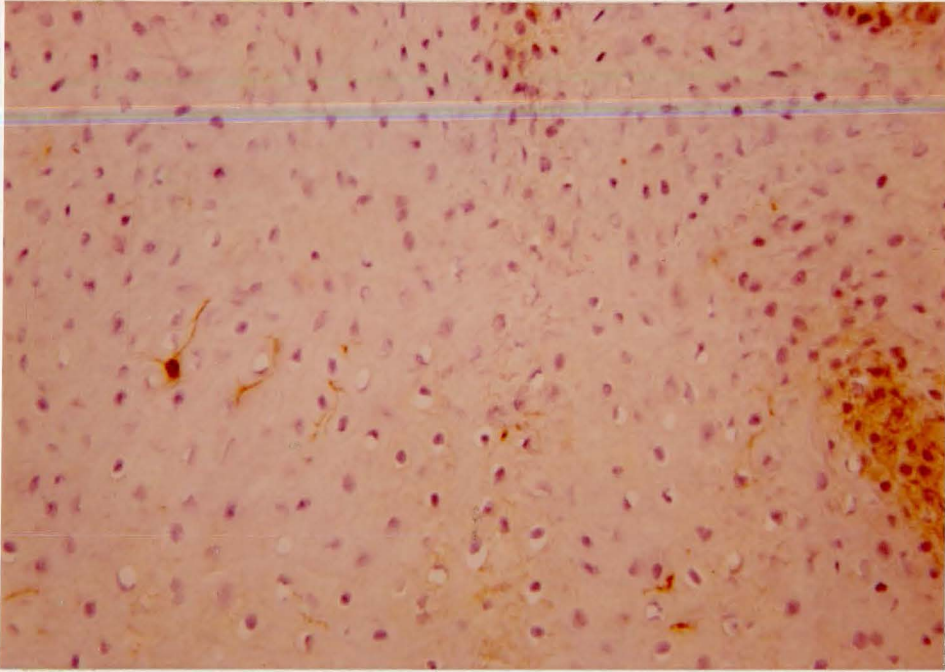


Figure 12. HLA-DR (Clinically Normal) 10X

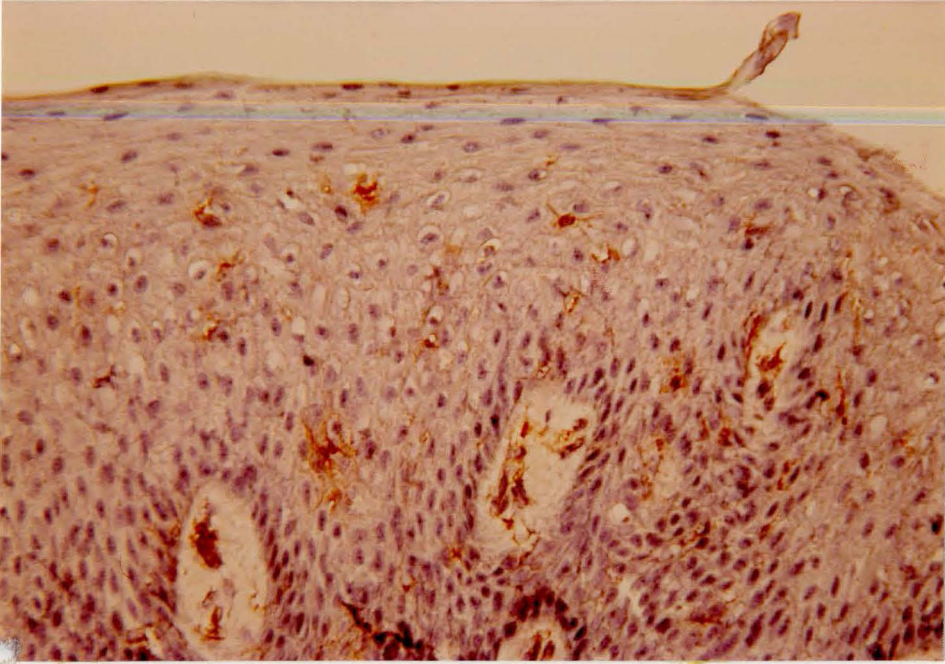


Figure 13. HLA-DR (Clinically Inflamed) 10X

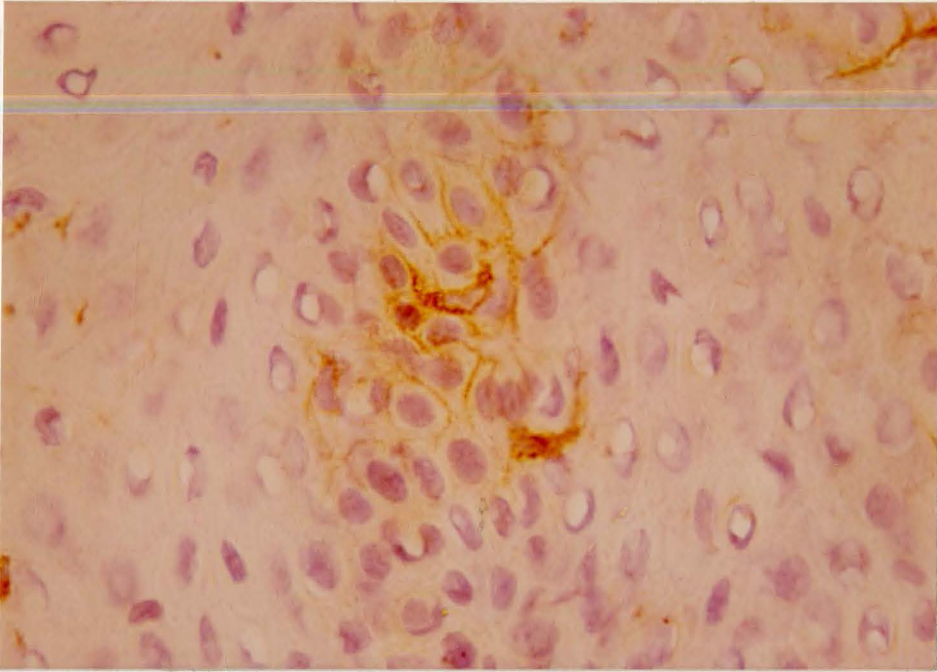


Figure 14. HLA-DR (Clinically Inflamed) 25X

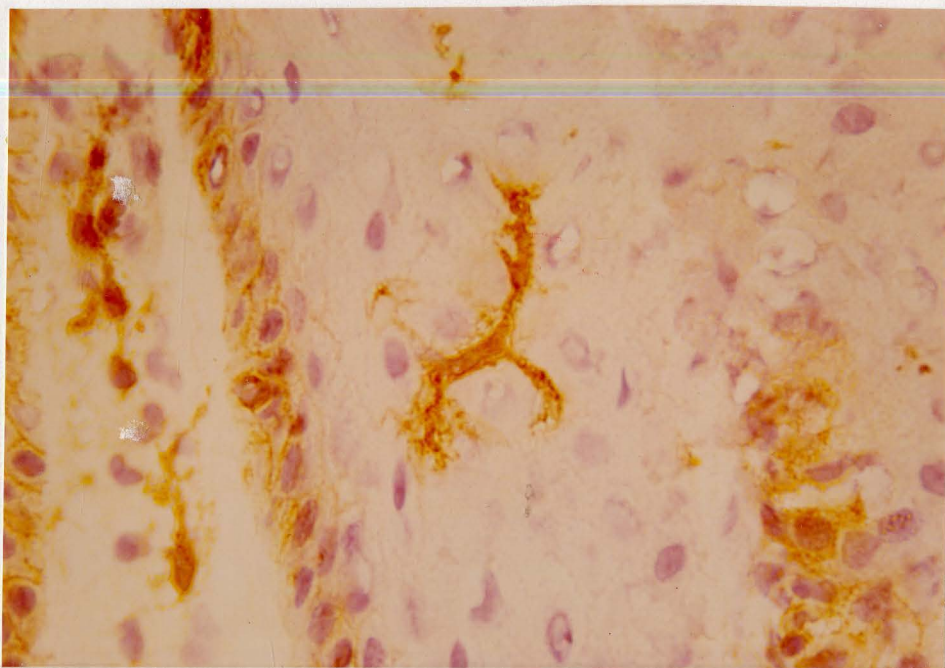


Figure 15. HLA-DR (Clinically Inflamed) 25X

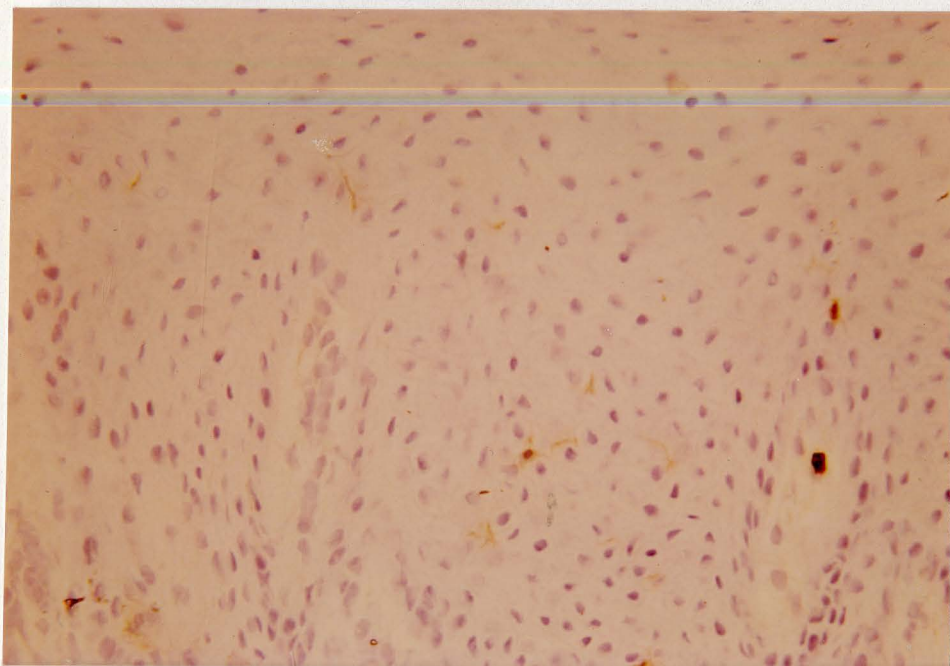


Figure 17. OMT-6 (Clinically Inflamed) 2.5X

Figure 16. OMT-6 (Clinically Normal) 2.5X

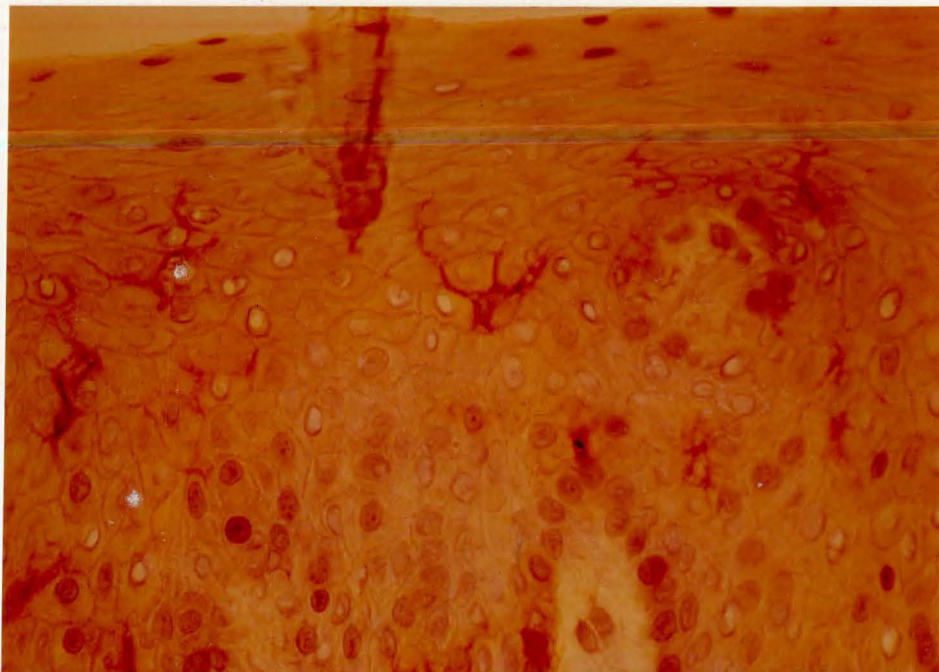


Figure 17. OBT-6 (Clinically Inflamed) 2.5X

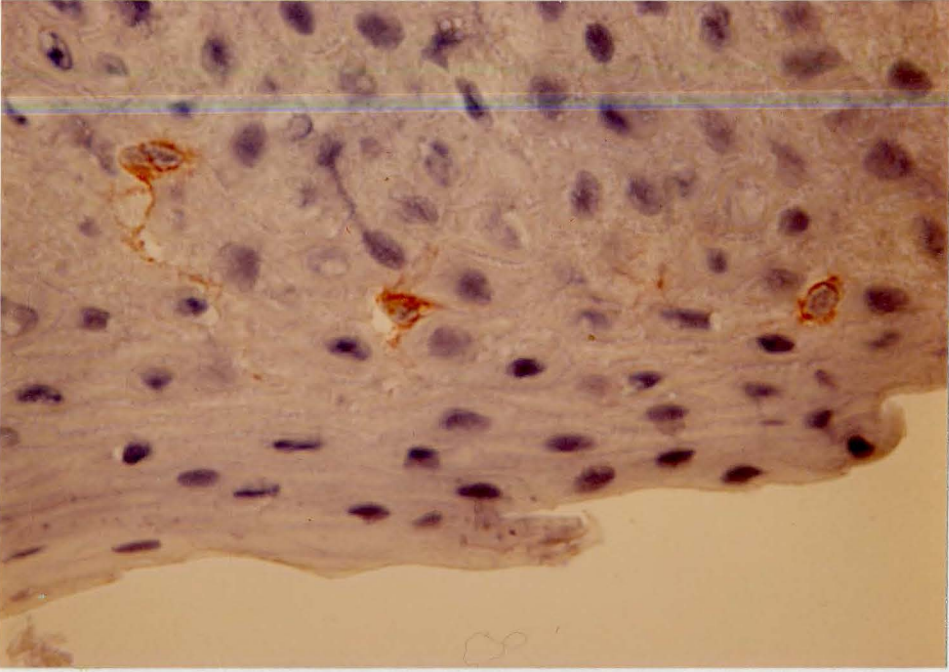


Figure 18. OMT-6 (Clinically Inflamed) 25X

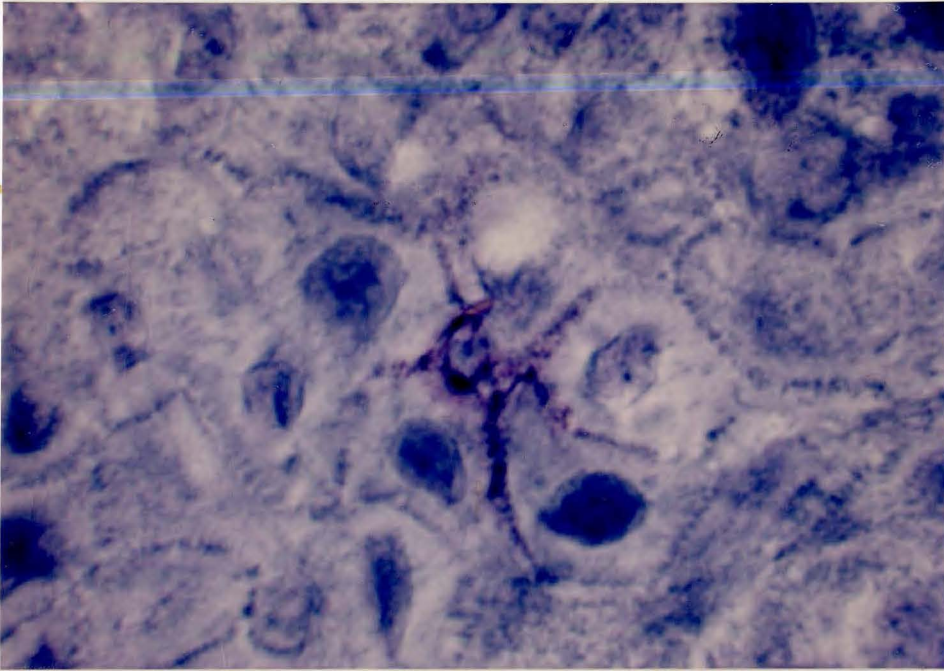


Figure 19. OKT-6 (Clinically Inflamed) 400X



Fig. 21 Major Developments in the History of the Langerhans Cell?

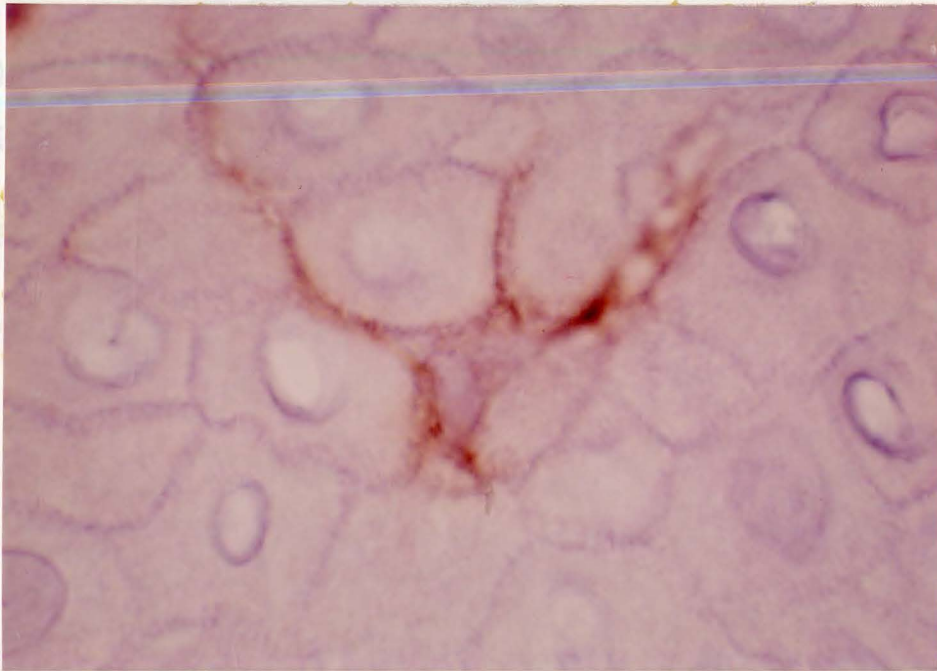


Figure 20. OKT-6 (Clinically Inflamed) 400X

association between plaque accumulation and Langerhans cell numbers in the oral epithelium of attached gingiva demonstrated (Jansson et al.)

## Fig. 21 Major Developments in the History of the Langerhans Cell

- 1868 Langerhans cell discovered by Paul Langerhans - thought of as part of the nervous system
- 1961 electron microscopic features described (Birbeck et al.)
- 1966-7 Langerhans cells demonstrated in the oral epithelium (Schroeder and Theilade, Waterhouse and Squier)
- 1967 Langerhans cell membrane shown to contain adenosine triphosphatase (ATPase) (Wolf and Winkelmann)
- 1973 apposition (peripolesis) of lymphocytes to Langerhans cells demonstrated and antigen presentation by Langerhans cells suggested (Silberg)
- 1974 migration of Langerhans cells via dermal lymphatics to lymph nodes described (Silberberg et al.)
- 1976 "reticulo-epithelial trap" for contact allergens suggested (Shelley and Juhlin)
- 1977 cell membrane receptors for  $F_C$  fragment of IgG and complement (Stingl et al) and Ia histocompatibility surface antigens (Rowden et al., Klareskog et al., Stingl et al.)
- 1978 demonstration of initiation of immune response by Langerhans cells (Stingl et al.)
- 1982 association between plaque accumulation and Langerhans cell numbers in the oral epithelium of attached gingiva demonstrated (Newcomb et al.)

Fig. 22 Protocol for ATPase Preparation  
(Wachstein and Meisel, 1960)

1. Frozen sections cut at 10 microns
2. Air dry 15 minutes -  $\text{DH}_2\text{O}$  rinses 3 times
3. ATPase solution (low heat and stir while making solution)
  - 0.125% ATPase 20 ml
  - 0.2 M pH 7.2 Tris 22 ml
  - 1M Magnesium Sulfate 5 ml
  - 2% Lead Nitrate 2.4 ml drop by drop, precipitate will occur
4. Filter
5. Preheat to  $37^\circ\text{C}$   
(if necessary filter again)
6. Incubate in  $37^\circ\text{C}$  oven 60 minutes
7.  $\text{DH}_2\text{O}$  rinse 5 times
8. 2% ammonium sulfide - (rinse under hood until developed)
9.  $\text{DH}_2\text{O}$  rinse 5 times
10. Aquamount

Fig. 23 Protocol for ATPase Preparation  
(Robins and Brandon, 1981)

1. Fix at 0-4°C in cacodylate formalin for 1 hour  
 i.e. distilled water 50 ml      40% formaldehyde 10 ml  
 0.2 M cacodylic acid 40 ml      sucrose                      6.85 g
2. Rinse in Phosphate Buffered Saline (equal parts of 0.15 M phosphate buffer and 0.85% saline)
3. Freeze and store at -80°C
4. Frozen sections cut with cryostat to 5 µm - 10 µm sections
5. Air dry several hours
6. Incubate in sections in freshly prepared, prefiltered and prewarmed ATP substrate at 37°C for 120 minutes (Modified Juhlin and Shelley (1977) substrate).  
 distilled water 50 ml  
 0.25 M trismaleate buffer 40 ml  
 pH 7.2  
 0.1 M Magnesium Sulfate 1- ml  
 glucose 5 g  
 adenosine-5-triphosphate 80 mg  
 2% Lead Nitrate 10 ml  
 pH of final solution to be 7.0
7. Rinse in distilled water
8. Develop in 1% ammonium sulfide until Langerhans Cells developed
9. Rinse in tap water
10. Aquamount

Fig. 24 Protocol for S-100 Self Sandwich Preparation  
(Hsu, 1981)

1. Mount 4  $\mu\text{m}$  paraffin sections on prepared glued slides and dry at  $56^{\circ}\text{C}$
2. Deparaffinize in 3 changes of xylene
3. Hydrate through graded alcohols to distilled water
4. Trypsinize 0.001 gm trypsin, 1 ml. 0.1%  $\text{CaCl}_2$  15 minutes  
Phosphate Buffered Saline Rinse  
(equal parts of 0.15 M phosphate buffer and 0.85% saline)
5. Block endogenous with 3%  $\text{H}_2\text{O}_2$  10 minutes    PBS    Rinse
6. Block endogenous with 1-5 normal swine serum
7. Incubate S-100 AB (1-20) 30 minutes    PBS wash
8. Incubate S-100 Ag 30 minutes  
(10  $\lambda$  S-100 Antigen - 1 ml PBS)    PBS Wash
9. Incubate S-100 AB (1-20) 30 minutes    PBS Wash
10. Incubate swine anti-rabbit (1-20) 30 minutes    PBS Wash
11. Incubate rabbit peroxidase antiperoxidase (1-100) 30 minutes PBS Wash
12. Develop sites with 3,9 amino ethyl carbazole     $\text{H}_2\text{O}$  wash
13. Counterstain with Mayers hematoxylin     $\text{H}_2\text{O}$  Wash
14. Blue with saturated lithium carbonate     $\text{H}_2\text{O}$  Wash
15. Aquamount

Fig. 25 Protocols for OKT-6 and HLA-DR Preparation  
(Murphy, 1981)

1. Frozen section cut at 10 microns - air dry
2. Fix in cold acetone - 30 minutes  
PBS Wash
3. Incubate with monoclonal HLA-DR (Becton Dickinson)/ODT-6 (Ortho Diagnostic 60 minutes PBS Wash
4. Incubate with rabbit antimouse peroxidase conjugated (1-10)  
60 minutes PBS Wash
5. Develop sites with 3,9 - amino ethyl carbazole  
H<sub>2</sub>O Wash  
This step is performed qualitatively and the slide is examined under a microscope for the presence of Langerhans cells
6. Counterstain with Mayers hematoxylin  
H<sub>2</sub>O Wash
7. Blue with saturated lithium carbonate  
H<sub>2</sub>O Wash
8. Aquamount

Fig. 26 Criteria for the Gingival Index System

0 = Normal Gingiva

1 = Mild inflammation - slight change in color, slight edema.

No bleeding on probing.

2 = Moderate inflammation - redness, edema and glazing.

Bleeding on probing.

3 = Severe inflammation - marked redness and edema, ulceration.

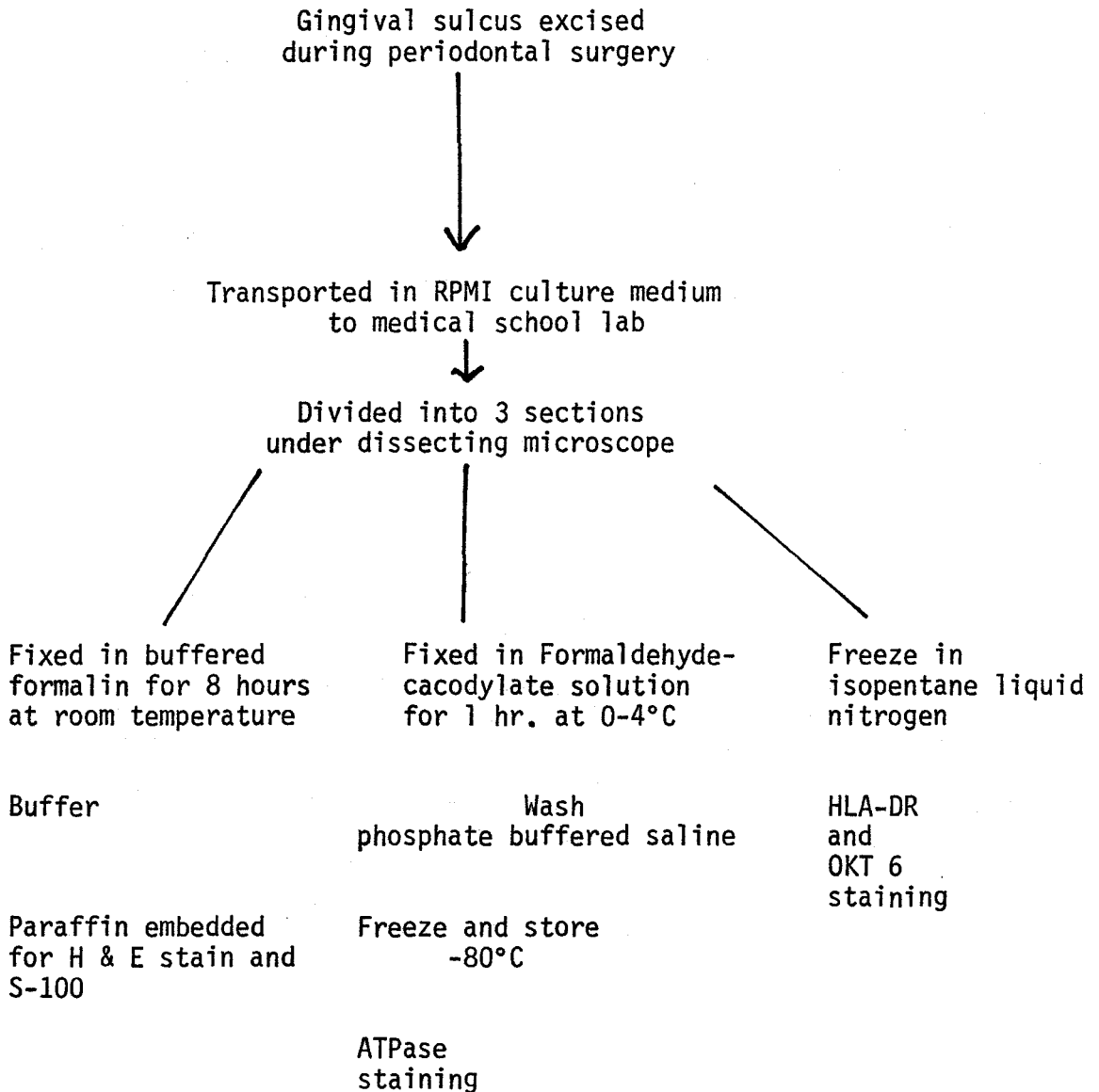
Tendency to spontaneous bleeding.

Fig. 27 Statistical Analysis

	MEAN	ST. DEV.	T test
1N	0.19048	0.397	T = -4.826
1I	1.200	1.00	T test significant at 0.01
2N	0.33333	0.488	T = -5.171
2I	1.3864	1.06	T test significant at 0.01
3N	0.500	0.798	T = -1.203
3I	0.84615	0.881	Cannot reject T at 0.05
4N	0.26786	0.522	T = -4.794
4I	0.89286	0.824	T test significant at 0.01
5N	0.071429	0.267	T = -2.702
5I	0.64286	0.745	T test significant at 0.01
6N	0.12500	0.334	T = -3.696
6I	0.71429	0.810	T test significant at 0.01
7N	0.42857	0.690	T = 5.037
7I	1.4390	0.976	T test significant at 0.01



Fig. 28 PROCEDURE



## Fig. 29 Letter to Institutional Review Board Chairman

A  
Century  
of Service



LOYOLA UNIVERSITY  
OF CHICAGO  
SCHOOL OF DENTISTRY

2160 S. FIRST AVENUE  
MAYWOOD, IL 60153

312/344-8533

July 13, 1982

Dr. Silvio Aladjem  
Obstetrics and Gynecology  
Loyola University  
2160 S. First Avenue

Dear Dr. Aladjem:

I would like to begin a research project in the department of Periodontics here at Loyola University School of Dentistry. I will be examining sections of human gingiva obtained during surgery for the presence of Langerhans cells. I will be using for my study, specimens of human gingiva which have been removed as part of the periodontal surgical procedures used in the routine treatment of periodontal disease.

The patients will be required to sign the attached consent form as do all patients who have periodontal surgery performed here. I have added one sentence to be more specific towards my research.

These tissues are commonly stained by many techniques as will be done in my study. I therefore would like to request an expedited review since there is minimal risk to the patient, the surgical procedures will not be altered in any way from that normally used, and the procedure has been used previously in other research projects.

Respectfully,

*Charles DiFranco DDS*

Charles DiFranco, D.D.S.  
Dept. of Periodontics

Fig. 30 Reply from Institutional Review  
Board Chairman



LOYOLA UNIVERSITY MEDICAL CENTER

2160 South First Avenue, Maywood, Illinois 60153

312 531-3000

July 14, 1982

Charles DiFranco, D.D.S.  
Department of Periodontics  
Dental School  
Loyola University School of Dentistry


Dear Dr. DiFranco:

In reply to your letter of July 13, 1982, as long as the specimen is obtained during a surgical procedure which the patient undergoes for reasons unrelated to your study, and as long as the specimen is not identified in terms of a patient's name, there is no need for IRB submission. This falls under the category of studies of pathologic tissue.

There is no need to include the added underlined sentence in the consent form. It should also be clear that the cost of your study should not be billed to the patient.

Thank you for consulting the Board in this matter.

Sincerely,



Silvio Aladjem, M.D., Chairman  
Institutional Review Board for the  
Protection of Human Subjects - Medical Center

SA/s

### Fig. 31 CONSENT AND PERMIT FOR PERIODONTAL SURGERY

Patient \_\_\_\_\_ Age \_\_\_\_\_  
 Place: Loyola University \_\_\_\_\_  
 School of Dentistry \_\_\_\_\_  
 Maywood, Illinois \_\_\_\_\_  
 Date \_\_\_\_\_  
 Time \_\_\_\_\_

1. Thereby consent, authorize and request the Department of Periodontics, Loyola University, Maywood, Illinois to perform periodontal surgery and all other necessary therapeutic surgical procedures, which have been prescribed to me.
2. I also consent, authorize and request the administration of such anesthetic or medication as may be deemed advisable for the procedure. The nature, purpose and risk of the anesthetic or medications and possible alternative methods of anesthesia and medication have been explained to me. I acknowledge that no guarantee or assurance has been made as to the results of said anesthetics or medications.
3. If any unforeseen condition arises in the course of this procedure calling in the judgement of the therapist for surgical or nonsurgical procedures in addition to those now contemplated, I further request and authorize him to do whatever he deems advisable and necessary in the circumstances.
4. I have been informed that periodontal surgery is intended to extend the length of tooth retention and that no prognosis can be designated to each tooth and that teeth having a questionable prognosis may require extraction after a surgical evaluation.
5. I am aware of the aesthetic appearance (gingival recession with root exposure) which may be necessary in order to obtain a good periodontal result.
6. I have been informed of possible post periodontal root sensitivity.
7. It has been explained that I must maintain diligent and consistent home care, obtain frequent cleanings and proper oral rehabilitation in order to increase tooth longevity.
8. The nature and purpose of the procedure and possible alternative methods of treatment, have been explained to me. Further, I consent to the disposal of any tissue which may be removed unless otherwise requested by me to be examined by a pathologist. I consent to having any tissues which may be removed to be examined for the presence of Langerhans cells.
9. If the patient is under 18 years of age, his or her parent or guardian must sign below and thereby accept and agree to the foregoing on behalf of himself or herself and his child or ward.

The above has been read and understood by me. I accept responsibility for said content.

\_\_\_\_\_  
 (Resident or Attending Dentist)

\_\_\_\_\_  
 (Patient or Guardian)

APPROVAL SHEET

The thesis submitted by Charles F. DiFranco has been read and approved by the following committee:

Dr. Patrick Toto, Director  
Professor, Oral Pathology, Loyola

Dr. Anthony Gargiulo  
Professor, Periodontics, Loyola

Dr. Joseph Keene  
Associate Professor, Periodontics,  
Loyola

Dr. Geoffrey Rowden  
Professor, Pathology,  
Loyola Medical School

The final copies have been examined by the director of the thesis and the signature which appears below verifies the fact that any necessary changes have been incorporated and that the thesis is now given final approval by the Committee with reference to content and form.

The thesis is therefore accepted in partial fulfillment of the requirements for the degree of Master of Science in Oral Biology.

September 6 1983  
Date

  
Director's Signature