



eCOMMONS

Loyola University Chicago  
Loyola eCommons

---

Dissertations

Theses and Dissertations

---

1963

## Changes in the Cerebral Cortex of the Rat Following a Localized High Dose of X-Irradiation, as Seen with Electron Microscope

Thomas F. McDonald  
*Loyola University Chicago*

Follow this and additional works at: [https://ecommons.luc.edu/luc\\_diss](https://ecommons.luc.edu/luc_diss)

 Part of the [Medicine and Health Sciences Commons](#)

---

### Recommended Citation

McDonald, Thomas F., "Changes in the Cerebral Cortex of the Rat Following a Localized High Dose of X-Irradiation, as Seen with Electron Microscope" (1963). *Dissertations*. 697.  
[https://ecommons.luc.edu/luc\\_diss/697](https://ecommons.luc.edu/luc_diss/697)

This Dissertation is brought to you for free and open access by the Theses and Dissertations at Loyola eCommons. It has been accepted for inclusion in Dissertations by an authorized administrator of Loyola eCommons. For more information, please contact [ecommons@luc.edu](mailto:ecommons@luc.edu).




This work is licensed under a [Creative Commons Attribution-Noncommercial-No Derivative Works 3.0 License](#).  
Copyright © 1963 Thomas F. McDonald

**CHANGES IN THE CEREBRAL CORTEX OF THE RAT FOLLOWING A LOCALIZED  
HIGH DOSE OF X-IRRADIATION, AS SEEN WITH ELECTRON  
MICROSCOPE**

**by**

**Thomas Francis McDonald**



**A Dissertation Submitted to the Faculty of the Graduate School  
of Loyola University in Partial Fulfillment of  
the Requirements for the Degree of  
Doctor of Philosophy**

**January**

**1963**

LIBRARY  
LOYOLA UNIVERSITY  
CHICAGO, ILL.

## LIFE

Thomas F. McDonald was born in Chicago, Illinois, on June 7, 1927.

He was graduated from St. Augustine High School, Chicago, Illinois, in June, 1945. He attended Spring Hill College, Mobile, Alabama, and received the degree of Bachelor of Science in June, 1953. In September, 1953, he began graduate studies in the Department of Anatomy of Loyola University and received the Master of Science degree in June, 1956.

During the school year 1956-57 he was a Standard Oil Fellow. He was instructor of Biology at Lewis College, Lockport, Illinois, from September, 1957 to June, 1960; Resident Student Associate at Argonne National Laboratory, Argonne, Illinois, from October, 1960 to October, 1962; and is presently an Associate in the Departments of Anatomy and Neurology and Psychiatry at Northwestern University, Chicago, Illinois.

### ACKNOWLEDGEMENT

I am especially grateful for the opportunity to have had the generous guidance of Professors Friedrich Wassermann and David Smith Jones during this investigation. Their example as teachers and scientists has been one of the most meaningful experiences of my graduate work.

I am also indebted to my wife and family and to the many people whose aid and encouragement have been instrumental in the accomplishment of this work.



## TABLE OF CONTENTS

	Page
INTRODUCTION. . . . .	1
A. THE NORMAL CEREBRAL CORTEX. . . . .	1
B. PURPOSE OF THE INVESTIGATION. . . . .	4
C. SPECIFIC PROBLEMS.. . . .	4
1. THE PRIMARY EFFECTS OF RADIATION ON THE CENTRAL NERVOUS SYSTEM	4
2. THE "BREAK DOWN" OF THE BLOOD-BRAIN BARRIER TO VITAL DYES.. .	6
3. ULTRASTRUCTURAL CHANGES DURING CEREBRAL EDEMA.. . . .	8
4. CHANGES IN THE PERIVASCULAR CELLS FOLLOWING IRRADIATION.. . .	9
MATERIALS AND METHODS.. . . .	10
OBSERVATIONS. . . . .	13
A. EFFECTS OF IRRADIATION ON THE ANIMALS AND MACROSCOPIC OBSERVATION OF THE IRRADIATED AREA. . . . .	13
B. OBSERVATIONS OF THE CHANGES IN THE CEREBRAL CORTEX FROM THE FIRST TO THE EIGHTH DAY FOLLOWING IRRADIATION.. . . .	14
C. THE FIRST DAY FOLLOWING IRRADIATION.. . . .	14
D. SECOND DAY FOLLOWING IRRADIATION. . . . .	14
E. THIRD AND FOURTH DAYS FOLLOWING IRRADIATION.. . . .	16
F. FIFTH DAY FOLLOWING IRRADIATION.. . . .	17
G. SIXTH THROUGH THE EIGHTH DAYS FOLLOWING IRRADIATION.. . . .	19
H. THE PENETRATION OF FERRITIN IN THE AREA OF NORMAL CAPILLARIES.. .	20
I. THE PENETRATION OF FERRITIN FOLLOWING IRRADIATION.. . . .	21
DISCUSSION. . . . .	22
A. THE EFFECTS OF IRRADIATION. . . . .	22
B. THE ELECTRON AND LIGHT MICROSCOPY OF EDEMA IN THE CENTRAL NERVOUS SYSTEM. . . . .	25
C. THE PENETRATION OF FERRITIN.. . . .	26
D. CHANGES IN ASTROCYTES OTHER THAN SWELLING.. . . .	27
E. CHANGES IN PERIVASCULAR CELLS AND THE SOURCE OF PHAGOCYTES IN THE IRRADIATED TISSUE.. . . .	27
CONCLUSIONS.. . . .	30
LITERATURE CITED. . . . .	32
TABLES. . . . .	36
FIGURES AND PLATES. . . . .	39

## LIST OF TABLES

Table	Page
1. FIXATION AND EMBEDDING SOLUTIONS. . . . .	36
2. FIXATION, DEHYDRATION, AND EMBEDDING PROCEDURE. . . . .	37
3. EXPERIMENTAL ANIMALS AND SPECIAL PROCEDURES.. . . .	38

## LIST OF FIGURES

Figure	Page
1. NORMAL CEREBRAL CORTEX. . . . .	40
2. AN ESSENTIALLY NORMAL AREA IN THE CEREBRAL CORTEX, 1 DAY AFTER IRRADIATION. . . . .	42
3. AN ESSENTIALLY NORMAL AREA IN THE CEREBRAL CORTEX, 1 DAY AFTER IRRADIATION. . . . .	44
4. A PORTION OF A NORMAL NEURON. . . . .	46
5. AN ESSENTIALLY NORMAL AREA IN THE CEREBRAL CORTEX, 1 DAY AFTER IRRADIATION. . . . .	48
6. NORMAL CEREBRAL CORTEX. . . . .	50
7. TISSUE FROM THE CEREBRAL CORTEX, 5 DAYS AFTER IRRADIATION. . . .	52
8. AN ALTERED AREA IN THE CEREBRAL CORTEX, 1 DAY AFTER IRRADIATION..	54
9. A DAMAGED CAPILLARY IN THE CEREBRAL CORTEX, 2 DAYS AFTER IRRADIATION.. . . . .	56
10. AN ALTERED AREA OF THE BASEMENT MEMBRANE, 2 DAYS AFTER IRRADIATION	58
11. AN ALTERED AREA IN THE CEREBRAL CORTEX, 2 DAYS AFTER IRRADIATION.	60
12. A PERICAPILLARY SPACE IN THE CEREBRAL CORTEX, 2 DAYS AFTER IRRADIATION. . . . .	62
13. AN ALTERED PERIVASCULAR CELL IN THE CEREBRAL CORTEX, 2 DAYS AFTER IRRADIATION. . . . .	64
14. AN ALTERED PERIVASCULAR CELL IN THE CEREBRAL CORTEX, 2 DAYS AFTER IRRADIATION+ . . . . .	66
15. AN ALTERED AREA IN THE CEREBRAL CORTEX, 3 DAYS AFTER IRRADIATION.	68
16. AN ALTERED AREA IN THE CEREBRAL CORTEX, 3 DAYS AFTER IRRADIATION.	70

Figure		Page
17.	AN ALTERED AREA IN THE CEREBRAL CORTEX, 3 DAYS AFTER IRRADIATION.	72
18.	AN ALTERED AREA IN THE CEREBRAL CORTEX, 5 DAYS AFTER IRRADIATION.	74
19.	AN ALTERED AREA IN THE CEREBRAL CORTEX, 5 DAYS AFTER IRRADIATION.	76
20.	AN ALTERED AREA IN THE CEREBRAL CORTEX, 5 DAYS AFTER IRRADIATION.	78
21.	A PHAGOCYTE IN THE CEREBRAL CORTEX, 5 DAYS AFTER IRRADIATION. . .	80
22.	AN ALTERED CAPILLARY IN THE CEREBRAL CORTEX, 5 DAYS AFTER IRRADIATION.. . . .	82
23.	EXPANDED EXTRACELLULAR SPACE IN THE REGION OF A CAPILLARY IN THE CEREBRAL CORTEX, 5 DAYS AFTER IRRADIATION.. . . .	84
24.	THE PENETRATION OF FERRITIN INTO ASTROCYTES AND OTHER CELLS IN THE CEREBRAL CORTEX, 5 DAYS AFTER IRRADIATION.. . . .	86
25.	LOCALIZATION OF FERRITIN IN THE AREA OF A PHAGOCYTE IN THE CEREBRAL CORTEX, 5 DAYS AFTER IRRADIATION. . . . .	88
26.	A RELATIVELY INTACT AREA IN TISSUE OF THE CEREBRAL CORTEX, 5 DAYS AFTER IRRADIATION.. . . .	90
27.	A MEMBRANOUS WHORL IN THE CYTOPLASM OF AN ASTROCYTE IN THE CEREBRAL CORTEX, 5 DAYS AFTER IRRADIATION. . . . .	92
28.	ALTERED CELLS IN THE CEREBRAL CORTEX, 5 DAYS AFTER IRRADIATION.. .	94
29.	ALTERED CELLS IN THE CEREBRAL CORTEX, 5 DAYS AFTER IRRADIATION. .	96
30.	A RELATIVELY INTACT AREA IN THE CEREBRAL CORTEX, 7 DAYS AFTER IRRADIATION.. . . .	98
31.	ALTERED NEURONS IN A SEVERELY DAMAGED AREA IN THE CEREBRAL CORTEX, 7 DAYS AFTER IRRADIATION. . . . .	100
32.	A SEVERELY DAMAGED MICROGLIAL CELL IN THE CEREBRAL CORTEX, 7 DAYS AFTER IRRADIATION.. . . .	102
33.	A SEVERELY DAMAGED CAPILLARY IN THE CEREBRAL CORTEX, 8 DAYS AFTER IRRADIATION.. . . .	104
34.	ALTERED CELLS IN THE CEREBRAL CORTEX, 8 DAYS AFTER IRRADIATION. .	106

## Figure

## Page

35. A SEVERELY DAMAGED AREA IN THE CEREBRAL CORTEX, 8 DAYS AFTER  
IRRADIATION.. . . . . 108
36. THE PENETRATION OF FERRITIN IN A NORMAL CEREBRAL CAPILLARY OF AN  
ANIMAL SACRIFICED ONE HOUR AFTER INJECTION. . . . . 110

## INTRODUCTION

### The Normal Cerebral Cortex

In preface to this dissertation, the author feels it is proper to present the following brief description of the normal central nervous system as seen with electron microscopy. It is based on control tissues as observed during this investigation and on previous descriptions of a number of authors (Palay and Palade, '55; Wyckoff and Young, '56; Luse, '56; Farquhar and Hartmann, '57; Maynard, Schultz and Pease, '57; Schultz, Maynard and Pease, '57; Bennett, Luft and Hampton, '59; De Robertis, and Gerschenfeld, '61; and Gray, '61). Those structures most pertinent in this study are accentuated, and where necessary, terms are clarified.

When viewed with electron microscopy, the central nervous system appears extremely compact (figs. 1 and 3). The distance between cells consists of a narrow, but rather uniform, extracellular space of about 200 to 250 A (figs. 4 and 5). Processes of clear glial cells are abundant in the tissue and tend to accumulate at the periphery of capillaries (figs. 1, 2, and 3). These cells have occasionally been classified as oligodendroglial cells (Luse, '60), but it seems that the majority of the investigators consider them to be astrocytes. In the present study they are referred to as astrocytes.

The cytoplasm of astrocytes is recognized by its "watery" appearance and relative lack of organelles (figs. 1, 2, 3, 4, and 5). Astrocyte nuclei are also comparatively clear; the chromatin material tends to be clumped and

usually forms a dense rim at the inner surface of the nuclear membrane.

Nerve cell bodies are distinguished by their granular cytoplasm, and nuclei in which the chromatin appears sparse but rather evenly distributed (figs. 1, 2, and 3). At higher magnification (fig. 4) one sees that the granular portion of the cytoplasm, containing mitochondria, dense bodies, and clear vacuoles, is often interrupted by cisternae of endoplasmic reticulum. In general, the axons of these cells are recognized by their investing myelin sheaths. Dendrites are not surrounded by myelin and are seen to contain fine tubules in their cytoplasm (figs. 2 and 3).

Oligodendroglial cells contain cytoplasm which, although much less in quantity, resembles that of neurons. They are best identified by their relatively small and dense nuclei (fig. 1).

Microglial cells are easily distinguished by the extreme density of their cytoplasm and nuclei (fig. 3). The cytoplasm contains an abundance of granules, and appears to be separated into strands and clumps by clear areas which apparently represent endoplasmic reticulum. Nuclei of microglial cells are also packed with granular material, so much so, that it is often difficult to distinguish the periphery of the nucleus from the surrounding cytoplasm.

The capillaries of the central nervous system have been classified by Bennett, Luft, and Hampton ('59) as type A-1-beta, that is, they have a complete basement membrane, they do not have intercellular fenestrations or pores, and they are completely invested by pericapillary cells (fig. 5). These capillaries differ from other capillaries in the A-1 category (eg., muscle capillaries, A-1-alpha) only in that the tissue elements are in close contact with their periphery, viz., they lack pericapillary extracellular space.

The cytoplasm of capillary endothelial cells contains scattered clusters of granules, a few mitochondria and numerous vesicles. It is believed that a number of these vesicles are formed by invaginations of the plasma membrane (by pinocytosis), and that they are active in conveying some substances through the endothelium (Palade, '61). Endothelial cells are often seen to overlap, leaving a small space of about 150 to 250 A between the surface membranes at the area of the junction.

The basement membrane surrounding the endothelium is probably of a polysaccharide nature (Pease, '60). It is distinctly divided into three zones, an inner light zone which is continuous with the intercellular junction between overlapping endothelial cells, an intermediate dense zone, and an outer light zone which is continuous with the narrow extracellular space of the neural tissue (fig. 5). Together, the three zones measure approximately 500 A: the intermediate zone being slightly larger than either of the other two.

Perivascular cells, elongate flat cells arranged longitudinally in the capillary wall, are found within the basement membrane (figs. 5 and 6). All three zones of the basement membrane pass on either side of the cells (fig. 5). In structure, the perivascular cells are similar to endothelial cells; the nuclei are dense and clusters of granules are dispersed throughout the cytoplasm.

Crowded processes of neural cells are seen at the immediate periphery of the basement membrane (figs. 1, 2, 5, and 6). Maynard et al. have estimated that about 85% of this area is occupied by the processes of astrocytes; the remaining area being occupied by various portions of other cells.



In summary, one can see that the component cells, already described with light microscopy, can again be identified with electron microscopy. The tissue appears exceptionally compact, having only a small extracellular space even in the area of capillaries (areas such as the choroid plexus, area postrema, and apparently other regions that stain with acidic vital dyes do have considerable pericapillary space. Dempsey and Wislocki, '55; Van Breeman and Clemente, '55). The basement membrane is seen as three distinct zones surrounding capillaries and measuring about 500 A in thickness. Perivascular cells are surrounded by the basement membrane. The majority of the area immediately external to the basement membrane is occupied by processes of astrocytes and neurons.

#### Purpose of the Investigation

Electron microscopy has been of special value in studies of the central nervous system. In addition to the usual advantage of resolving structure with high magnification, it has presented a method whereby all of the components of this tissue can be viewed with equal clarity in a single preparation. In the present study, the advantages of electron microscopy are used to study a lesion which develops in the cerebral cortex of rats following a localized, high dose of X-irradiation. The purpose of the investigation is to gain further information on some of the current problems concerning the pathomorphological response of the central nervous system to radiation and other injurious media.

#### Specific Problems

1. The Primary Effects of Radiation on the Central Nervous System Since the turn of this century, a number of investigations using light microscopy

have dealt with the effects of radiation on the central nervous system. The results of these studies have often led to conflicting opinions as to the manner in which this tissue responds to the irradiation. A controversy still exists as to whether all of the damage following irradiation is secondary to vascular damage (Glemente and Richardson, '62; Scholz, Schlöte and Hirschberger '62), or whether the neuroectodermal elements are also directly effected by the irradiation (Arnold et al., '54; Bailey, '62).

Recently, Hager, Hirschberger and Breit ('62) and Pitcock ('62) have presented ultrastructural studies which have direct bearing on this subject. Hager et al. have examined the cerebral cortex and cerebellum of Syrian hamsters during various intervals following localized X-irradiation of dosages ranging from 7500 to 45,000 r. Their observations show early swelling and outpouching of capillary endothelium. This is accompanied by plasma exudation erythrodiapedesis, and swelling with possible rupture of astrocytes. The authors consider these early changes to be secondary to increased vascular permeability.

Pitcock has exposed rats to 15,000 r of whole-body gamma irradiation and examined tissues during two days following the treatment. His observations also show an early swelling of capillary endothelium and astroglia. He suggests that the swollen endothelial cells may be the route for the migration of fluids into astrocytes.

In both of the investigations, the cerebellar granular cells show early changes. However, Hager et al. believe that this is a general response of these cells which is related to edema, and can be seen during a number of injuries to the central nervous system. Changes in other neurons occur

relatively late and are not defined as either direct or secondary effects of the irradiation.

In the present study the radiation dosage is not varied and tissues are examined on consecutive days into the late stages of radiation injury. Under these conditions it is possible to gain a rather good perspective of the sequence of changes as the lesion develops, and to estimate the dependence of some changes on previous alterations in the tissue.

2. The "Break Down" of the Blood-Brain Barrier to Vital Dyes In addition to morphological studies, the use of vital dyes has also indicated changes in vascular permeability in the central nervous system following irradiation.

From the pioneering studies of Ehrlich (1885) and Goldmann ('13), and subsequent studies by numerous investigators, it is well known that acidic vital dyes introduced into the blood stream of normal animals, rapidly stain most organs of the body, but, with the exception of a few areas, they do not stain the central nervous system. This phenomenon has led to the concept that a special barrier exists between the blood and the central nervous system, viz., the blood-brain barrier. The idea of a blood-brain barrier has received further support from radioactive tracer studies. However, with these substances, eg.,  $P^{32}$ ,  $Br^{82}$ ,  $K^{42}$ , and  $Na^{24}$ , it is not a case of complete restriction, as indicated with vital dyes; it is rather a slower penetration rate into this organ as compared to other organs (Bakay, '56).

Although many investigations have been made to determine the nature of this barrier, as yet, there is little agreement as to exactly where it exists or as to what it may be. Among the loci suggested are: the luminal surface of the endothelium (Rodriquez, '55), the area of the capillary basement

membrane (Dempsey and Wislocki, '55), and the glial membranes facing the capillary wall (De Robertis and Gerschenfeld, '61). Maynard et al. ('57) see no reason for considering "a specialized barrier". They claim that the limited penetration of substances into this tissue is merely a reflection of the lack of extracellular space and the necessity for the substances to enter directly into cells. On the basis of metabolic studies, Dobbing ('61) also denies the existence of a special barrier. In his opinion the entrance of a given substance into the central nervous system is entirely dependent upon its metabolism within the tissue.

Whatever the barrier may be, it is well known that the central nervous system becomes stainable with acidic vital dyes after a number of injuries. This has been demonstrated following such insults as stab wounds (Macklin and Macklin, '20), intra-arterial injections of high concentrations of Diodrast (Broman and Olsson, '48 and '49), and exposure of the brain to air (Prados, Strowger and Feindel, '45). It is also seen after damaging amounts of radiation (Rachmanow, '26; Mogilnitzsky and Podljaschuk, '30; Clemente et al., '61; Scholz et al., '62; Van Dyke, Janssen and Tobias, '62). It is interesting that some of these authors consider this stainability an indication of increased vascular permeability caused by a "break down" of the blood-brain barrier.

In the present investigation, ferritin, a protein containing an electron-dense iron core, is used as a "vital stain". Having an isoelectric point of less than 5.4 (Granick '42), this substance is acidic to blood. It is known to pass through capillaries into muscle tissue within 15 to 30 minutes after injection (Wissig, '58). Observing the penetration of this substance into

the brain before and after irradiation may present some evidence as to the structural changes which accompany the staining of this tissue with vital dyes following injury.

3. Ultrastructural Changes During Cerebral Edema Probably directly related to the increased vascular permeability which follows irradiation, is the common occurrence of edema in these tissues. Ultrastructural studies of the changes representing edema in the central nervous system are as yet few. The necessity of further studies of this type is implicit in their brief and controversial history.

In an early investigation of this subject, Torack, Terry and Zimmerman ('59 and '60) have shown that cerebral injury caused by cold wounds, expanding tumors or tin poisoning is manifested by swelling in astrocytes, with no change in the narrow space between cells. This finding appears to be in contradiction to observations made with light microscopy, where it is generally agreed that edematous fluids cause enlargements of the extracellular space as well as swelling in cells.

In consideration of the submicroscopic findings, Feigen et al. ('62) have repeated the light microscopy of cerebral edema using recent staining technics to localize edematous fluid in the tissues. Since their observations reaffirm the findings of earlier light microscopy, the authors have concluded that the basic mechanism of edema remains undetermined. However, they present the possibility that under severe conditions, the swollen astrocytes seen with electron microscopy may rupture forming enlarged spaces in the tissue. This they agree would reconcile the observations as made with both methods.

That this may well be the case, is indicated by the work of Evans

et al. ('61), who have described disintegration and disruption of "perivascular glial cells" in brain tissues which have undergone severe edematous changes. They note that the disruption of these cells results in extensive extracellular space in the tissue.

The present investigation offers an additional study on this subject. The changes in astrocytes and in the extracellular space are followed through the various stages of the edema which follows radiation damage.

4. Changes in the Perivascular Cells Following Irradiation Although perivascular cells were described in early ultrastructural studies of the central nervous system, (Farquhar and Hartmann, '56 and '57), the function of these cells remains obscure. Farquhar and Hartmann ('56) believe that they may be related to microglial elements, and Maynard et al. ('57) suggest that they may represent vestigial smooth muscle cells. In a recent study of the capillary reaction to tumors and allergic encephalitis, Torack ('61) found that perivascular cells show a phagocytic response to injury. He has suggested that these cells may be adventitial histiocytes.

In the present study, the perivascular cells are found to undergo a series of changes leading to their formation of phagocytes following the irradiation.

## MATERIALS AND METHODS

Over 60 male Sprague-Dawley albino rats weighing 90 to 110 gm were used for this experiment. Thirty-one of these were irradiated according to the following procedure. Animals were anaesthetized with intraperitoneal injections of 0.75 cc of 0.54% Nembutal Sodium (Abbott Laboratories) and positioned at a General Electric Maxitron 250 X-ray unit. The middle third of the cerebral cortex was then subjected to 26,000 r of X-irradiation by means of a horizontally collimated beam measuring 1 cm in diameter.

The machine setting factors were 250 KVP, 30 ma, 3.12 mm aluminum filtration, HVL 0.62 mm of copper. Target distance was 28 cm, the penetration in depth dose through 1.5 cm of tissue was approximately 80%, and the average dose rate was 610 r/min.

The irradiated portion of the cerebral cortex was removed from animals during the eight consecutive days that followed treatment. The number of experimental animals sacrificed on each of the eight days is listed in Table III, page 38. Non-irradiated animals of the same original weight and received in the same shipment were sacrificed with each experimental animal; the tissues were prepared in the same manner.

A 10% solution of ferritin (Lachat Chemicals, Inc.) in doses ranging from 0.75 cc to 1 cc was injected into the tail vein of a number of the experimental animals one or two hours before they were sacrificed. In the majority of the animals the ferritin was allowed to circulate two hours before sacrificing

(see Table III, page 38). The corresponding control animals received the same treatment.

With electron microscopy, the iron core (Ferric hydroxide micelles) of ferritin molecules appears as an electron-dense particle of approximately 60 Å in diameter (Farrant, '54). The protein portion of the molecule forms an opaque shell about the iron core. In total, the molecule measures about 95 Å in diameter.

A variation of Palade's ('52) fluid, 2% buffered osmium tetroxide (see Table I, page 36) was used as a standard fixative. Removal and fixation of the tissues were carried out as follows. The vertebral column of an animal under light anaesthesia was severed in the cervical region with a scissors and the animal was quickly placed in a laboratory hood. After removing the epicranium, the exposed dorsal cranium was divided with a scissors along the superior sagittal sinus and the transverse sinuses; the resulting flaps were peeled away laterally. Five to ten drops of chilled 2% buffered osmium tetroxide were placed on the exposed cerebral cortex over a period of about 2 minutes. A wedge-shaped piece of tissue measuring about 2 mm at the base was excised from the cortex and placed in a drop of cold fixative on a wax slab, where thin pie slices were made. The slices were transferred to a larger volume of fixative for one hour at a temperature of 4° C. During the process of dehydration that followed fixation, all surfaces of the tissue slices were trimmed in order to remove tissue that may have been damaged in the process of dissecting the fresh material.

The tissues were dehydrated in graduated concentrations of ethanol, and embedded in Epon (see Table I, page 36.) according to a variation of Luft's



('61) method (see Table II, page 37.).

Tissues were sectioned with a Porter-Blum microtome, stained for three hours in uranyl acetate, and observed with RCA EMU 3E and EMU 3F microscopes. Micrographs were taken at magnifications ranging from 1800 to 30,000 diameters on Kodak medium and contrast lantern slide plates and enlarged 3 to 4.2 diameters when printed.

## OBSERVATIONS

### Effects of Irradiation on the Animals and Macroscopic Observation of the Irradiated Area

During the first three days following irradiation the animals became anorexic, irritable, and showed general weakness. About the fourth day the condition of approximately two-thirds of the animals was improved, while the other third exhibited tremors, emaciation, and were moribund. An external ulceration appeared in the irradiated region of the epicranium on about the fourth day.

In preliminary experiments several animals were allowed to live up to 9 months following the same irradiation procedure. With the exception of being slightly resistant to handling, these animals resumed the activities and general appearance of the control animals within three weeks following irradiation. By the fifth week the epicranial lesion healed, but the new skin remained furless. At autopsy, the irradiated region of the cerebrum was completely absent in animals sacrificed at 61 days or later. The remaining space measured approximately 3 mm in width, coursed across the right cerebrum into the left cerebrum, and extended to the floor of the lateral ventricles.

Macroscopic examination on the fifth day indicated discoloration due to petechial hemorrhages (fig. 7). By the eighth day the irradiated area seemed soft as compared to the surrounding tissue.

## Observations of the Changes in the Cerebral Cortex from the First to the Eighth Day Following Irradiation

When viewed on consecutive days, the manifestations of injury do not always follow in a uniform pattern. Certain cellular changes that are observed in tissue from an animal of one day, may be less severe or even absent from tissues of an animal observed on the following day. This is probably due to differences in the response of individual animals to the irradiation. Therefore, in the following descriptions, several days may be included as a single period. In this manner, the major points of the progressing lesion can be stressed.

### The First Day Following Irradiation

Within twenty-four hours after irradiation, extravasated erythrocytes are sparsely scattered throughout the tissues. Some are seen tightly packed within the extracellular space, while others appear to be located within the cytoplasm of astrocytes. The endothelium of a few capillaries may be enlarged and somewhat clear, and occasionally, a thrombosed capillary is encountered (fig. 8). An uneven thickening of the basement membrane also occurs in some capillaries. In some areas it may measure up to 1000 A in thickness, about twice the normal measurement.

In addition to extravasated erythrocytes, osmiophilic material of a seemingly foreign nature and an increased amount of vesicles appear in the cytoplasm of some astrocytes (fig. 8). Since the vesicles are often associated with granules, they may represent a proliferation of endoplasmic reticulum.

### Second Day Following Irradiation

By the second day following irradiation, altered capillaries are randomly

dispersed throughout the tissues. The alterations appear to be of two types depending on the components involved. Least seen, are those in which the endothelial cells are severely damaged (fig. 9). They are exceptionally narrow, reduced in some areas to a width of about 500 A. The cytoplasm is dark, due to an accumulation of granules, and the outlines of these cells are indistinct in some areas. Mitochondria may be swollen or lacking in internal structure. In the lumen of these capillaries, one occasionally finds vacuolated masses which may represent disintegrating erythrocytes.

More commonly, the capillary alterations involve the basement membrane, In some areas this structure is thickened to over 2000 A, and may be occupied by indistinct fibrils (fig. 10). In other areas the basement membrane has split, forming large spaces in the region of capillaries. (fig. 11). It is interesting that the separations consistently occur within the intermediate zone, thus, one portion of this zone remains at the periphery of the endothelium, and the other is found at the border of the surrounding tissue (figs. 11, 12, and 13). The intervening space appears clear, but occasionally contains fibrils. The nature of these fibrils cannot be determined in this study, but they usually show a regular sequence of bands across their axis, and the larger fibrils are about 400 A in diameter (fig. 12). They are apparently related to the less distinct fibrils that occupy thickened basement membranes. Since the fibrils are not seen in the basement membrane of normal cerebral capillaries, the structures seen at this time are evidently formed de novo.

Perivascular cells also undergo alterations at this time. They appear enlarged and spheroidal in cross section, and usually contain indented nuclei

(figs. 13 and 14). Pseudopodia-like extensions project from their periphery and occasionally appear to engulf osmiophilic material (fig. 13). Some pericapillary cells contain numerous dense bodies (fig. 14), which apparently represent lysosomes; organelles that are believed to be closely associated with phagocytic activity (de Duve, '56; Bennett, '56).

Processes of the astrocytes at the periphery of the altered capillaries (fig. 11) are often swollen and some of the mitochondria are disrupted. Peculiar formations have accumulated in the cytoplasm. Basically, these formations appear as vesicles, granules, and ill-defined strands which may be a type of precipitate. Combinations of these forms are seen in most of the swollen astrocytes, and, in some instances, in astrocytes which do not appear swollen.

#### Third and Fourth Days Following Irradiation

During the third and fourth days following irradiation, swollen astrocytes are prominent in many areas of the tissue. A number of these cells have ruptured (figs. 15 and 16). However, the cytoplasm of the ruptured cells is not seen to spread into the extracellular space of the adjacent tissue at this time. The nuclei appear enlarged, and the chromatin material may be detached from the nuclear rim, leaving thin, at places indistinct, membranes separating the cytoplasm from the nuclear sap (fig. 16).

Processes of other astrocytes seem to remain intact, and contain concentrated amounts of the cytoplasmic formations already noted in astrocytes of the second day (fig. 15).

Altered capillaries are not noticeably increased in number, and, in general, the alterations are of the same type as seen on the previous day.

Occasionally, one finds cells, which are characteristically similar to altered perivascular cells, extending beyond the basement membrane of capillaries into the surrounding tissues (fig. 17).

Early changes in neurons are first seen during this period. Swelling in the mitochondria, cytoplasmic vesicles and endoplasmic reticulum is apparent in many of these cells (figs. 15 and 16). Nuclear profiles are often distorted, but the internal structure of the nucleus is not significantly different from that of control tissue.

A number of microglial cells also exhibit swollen cytoplasmic components during this period (fig. 17).

#### Fifth Day Following Irradiation

By the fifth day it is more evident that the manifestations of injury occur in differing degrees within the same tissues. In some areas the tissue remains relatively intact, although cellular changes are obvious (fig. 26), in other areas the astrocytes are extraordinarily swollen (fig. 18), and in still other areas, large spaces separate cells (fig. 19). The large spaces contain small vesicles, broken membranes, and other fragments of disrupted cells. If one contrasts these areas with those having extremely swollen astrocytes, it seems obvious that the large spaces are formed as the result of the disruption of swollen astrocytes.

Concurrent with the formation of large spaces, there is a general "loosening" of the tissue in many areas. This is manifested by varying enlargements of the extracellular gap between cells (figs. 20, 21, and 23). It is conceivable that these expansions represent areas of disrupted astrocytes, as well as true expansions of the extracellular gap. The relative density of

the contents in many of these spaces, suggests that plasmatic fluid may leak into these areas.

Phagocytes laden with osmiophilic inclusions of various forms populate the tissues. Some of them are attached to capillaries (fig. 20); others appear to be removed from capillaries (fig. 21) and are usually congregated in areas showing severe cellular damage (fig. 19). Again, a number of these cells are basically similar to the altered perivascular cells seen during the earlier periods, presenting the possibility that perivascular cells give rise to some of the phagocytes now present in the tissues. Granular leucocytes and macrophages such as the type observed by Ross and Benditt ('61) in healing skin wounds are also seen.

Conspicuous alterations of capillary endothelial cells are not common. Basement membranes continue to show splitting and formations of fibrils, and occasionally are seen to hypertrophy, forming odd meshworks in the tissue adjacent to some capillaries (fig. 22).

Practically all of the astrocytes in these tissues exhibit obvious alterations of one kind or another. Those that have not undergone severe swelling or disruption, contain various formations in their cytoplasm. These usually include the vesicles, granules and obscure strands seen during earlier periods. In addition, they may contain extravasated erythrocytes (fig. 18), lipid inclusions and membranous whorls (figs. 26 and 27). The whorls seem to represent a compression of small vesicles within the cytoplasm (fig. 27).

Some neurons, particularly those in more severely damaged areas of the tissue, may show reduced amounts of cytoplasmic granules in addition to swell-

ing in cytoplasmic constituents (fig. 19). Dissolution of axons within myelin sheaths (fig. 19), and interruption of tubules in dendrites (fig. 20) also indicate damage to nerve cells.

A loss of cytoplasmic granules is apparent in some microglial cells during this period (fig. 28). Of the remaining microglia, many contain swollen cytoplasmic components; other microglia appear unchanged from their normal structure.

From this period through the eighth day following irradiation, those cells which can reasonably be identified as oligodendroglial cells usually contain a number of dense bodies and osmiophilic inclusions in their cytoplasm (figs. 28 and 29). The mitochondria are intact and occasionally one finds cytoplasmic extensions projecting from the periphery of these cells indicating that, under these conditions, they may function as phagocytes.

#### Sixth Through the Eighth Days Following Irradiation

In tissues examined from the sixth through the eighth days following irradiation, the gradient of damage already observed during the fifth day remains obvious. The primary differences in tissues appears to be the increase of severely damaged tissue as the days progress. Advanced damage is present in all of the cell-types throughout the three days and is most pronounced in areas showing enlarged spaces and congregated phagocytes.

Differing degrees of injury are demonstrated in figures 30 and 31, both of which are areas of the same tissue taken on the seventh day after irradiation. In figure 30 the cells remain relatively intact, although one does see some expansion of tissue spaces and an infiltration of erythrocytes. In figure 31, advanced damage to neurons is indicated by the cytoplasmic changes



and pyknotic nuclei. The tissue space is large, contains dense amorphous material, and is invaded by phagocytes.

In other severely damaged areas during this period one finds microglial cells showing almost complete loss of cytoplasmic granules (fig. 32), and capillaries in which the endothelium is practically absent (fig. 33).

Phagocytes continue to be prominent, and, particularly towards the eighth day, the osmiophilic inclusions tend to become homogeneous lipoid masses (figs. 34 and 35). Perivascular cells containing dense osmiophilic inclusions, can be found within the basement membrane, and similar cells are again noted in the tissues beyond the basement membrane (fig. 34).

Although advanced damage to some neurons can be seen as early as the fifth day after irradiation, comparatively intact neurons are present as late as the eighth day, even in areas where the adjacent cells have undergone complete disintegration.

Microglial cells are not observed to be phagocytic during any period of this investigation.

#### The Penetration of Ferritin in the Area of Normal Capillaries

Ferritin is easily recognized in the lumen of cerebral capillaries in an animal sacrificed one hour after injection (fig. 36). It is seen to have penetrated the endothelium and basement membrane. In the endothelium the particles appear as either solitary molecules randomly dispersed in the cytoplasm, or congregates of molecules which are often located within vesicles. Relatively few particles are present in the basement membrane, and on rare occasions one finds what appears to be a ferritin molecule in the cytoplasm of a cell beyond the basement membrane (fig. 36).

If ferritin is allowed to circulate two hours before sacrificing animals, there is no significant change in the localization or accumulation of the ferritin molecules in the area of these capillaries.

#### The Penetration of Ferritin Following Irradiation

From the second to the fourth days after irradiation changes in the penetration of ferritin are seen in the region of altered capillaries. In capillaries with damaged endothelium the ferritin appears to accumulate in the injured cells, and also the surrounding basement membrane (fig. 9). In capillaries having separations in the basement membrane, ferritin molecules are comparatively numerous within the endothelium and within the various regions of the separated basement membrane (fig. 12). Although a number of the astrocytes in contact with these capillaries are swollen or show other cytoplasmic changes, ferritin molecules continue to be only occasionally found beyond the basement membrane.

As the extracellular space enlarges during the fifth day, ferritin is seen throughout the areas separating cells (fig. 23). It is also present in many of the cells in the tissues, including the phagocytes which are now commonly encountered (figs. 21, 24, and 25). Most of the capillaries contain increased amounts of ferritin in the endothelium and particularly in the areas of the basement membrane (figs. 23 and 24).

During the following days the ferritin continues to pass readily into the tissues.

## DISCUSSION

In view of the relatively short duration between the administration of radiation and the appearance of necrosed areas in the tissues it is clear that this investigation deals primarily with the acute effects of radiation damage. Under different conditions of radiation, or when other species or strains of animals are used, the results may be quite different (Zeman, '61).

### The Effects of Irradiation

Among several initial effects that follow irradiation the most pronounced response is the swelling and disruption of astrocytes. The early swelling and rupture of these cells is of the same nature as that shown by Torack et al. ('59 and '60) in other types of injury, as representing edematous changes in the central nervous system. The large spaces which appear in tissues on the fifth day are apparently the same as those seen by Evans et al. ('61) again, under conditions of other injuries representing the disruption of astrocytes during edematous changes in the tissues. Evidently, the swelling and disruption of astrocytes following irradiation is a form of edema, not particularly different in its manifestations from the edema observed following other injuries to the central nervous system.

The exact cause of astrocyte swelling cannot be determined from our observations. Swollen endothelial cells, implied by several investigators (Pitcock, '62; Clemente and Richardson, '62) as the cause of increased migration of fluids into the central nervous system following irradiation, are

seldom seen in these tissues. Nor are the more damaged type of endothelial cells a common occurrence.

Early thickening of the basement membrane also presents a possible radiation effect that could lead to swelling in astrocytes. Palade ('61) has shown that the basement membrane may form an important filtration barrier in the region of capillaries. That it may be altered by irradiation is indicated by the experiments of Brinkman and Lamberts ('60) demonstrating increased permeability to substances injected into subcutaneous tissues following irradiation. The authors believe this is due to direct depolymerization of interstitial mucopolysaccharide material.

In addition, one cannot exclude the possibility that this swelling may be caused by direct disorganizational changes within astrocytes. De Robertis and Gerschenfeld ('61) have performed a number of experiments, specifically concerned with swelling in astrocytes. They believe that the astrocytes function as water-ion compartments, actively engaged in transporting substances between the blood and the cells of the nervous tissue. They feel that any interruption of the transport mechanism within these cells (they suggest it exists in the vicinity of the surface membrane facing capillaries) leads to their swelling.

We are not sure of the significance of the various changes that appear within astrocytes following irradiation. Swelling of mitochondria may be secondary to swelling of the cells as a whole. The increase in vesicles and granules and the formation of membranous whorls seem to be a reaction of the cytoplasm to injury; either directly effected by the irradiation, or secondary to the entrance of fluids and possibly other substances into the cells.

In the same manner, the precipitate-like strands may represent coagulated protein material suggested by Alexander ('61) as possibly occurring in irradiated cells, or it too, may be secondary to the damage of swelling.

Although the cause of the edematous changes remains a question, it appears that the eventual disruption of these cells initiates severe alterations in the tissues. The sudden appearance of large spaces in the tissues on the fifth day seems obviously the result of the disintegration of swollen astrocytes. A number of cells within and adjacent to these spaces show damage to a much greater degree than cells apparently more distant from the spaces. The fact that in many areas, the tissues undergo a general "loosening," indicates that the intact cells and their processes may tend to move into the regions vacated by disrupted astrocytes.

This general spreading of cells may be due to the "dissection" of the extracellular gap by fluids released from disrupted astrocytes and, as indicated by the denseness of the material in the spaces, by plasmatic fluids entering from the blood.

The more severely damaged areas seen in tissues from the sixth through the eighth days following irradiation, may be a direct reflection of the damaged areas apparently initiated by the disruption of astrocytes on about the fifth day. The graded manifestations of injury in other areas of these tissues, and the increase of severely damaged tissues on consecutive days, suggests that the damage may spread from these initial sites of injury.

Changes in neurons are not seen until the third and fourth days, a time when swollen and partially disrupted astrocytes are abundant in the tissue. These early neuronal changes are moderate, consisting of swollen cytoplasmic

structures and irregularly shaped nuclei. Although it is possible that these changes are directly effected by the irradiation, they may also result from the increased fluids and pressures now present in the tissues due to swelling in astrocytes. More exaggerated changes in neurons, e.g., loss of cytoplasmic granules and dissolution of processes, are not seen until severely damaged areas occur in the tissues associated with the disintegration of swollen astrocytes. During this and later phases of the injury the more profoundly changed neurons seem restricted to areas of severely damaged tissue.

Because of the close association of the alterations of neurons to the disruptive changes in astrocytes, we feel that most of the changes in nerve cells are secondary to damage of the astrocytes.

In a similar manner, alterations in microglia appear to be related to alterations in astrocytes. Swelling in cytoplasmic components of microglial cells is found to be coincidental with swelling in astrocytes. Loss of cytoplasmic granules accompanies the appearance of severe alterations of the tissues.

Oligodendroglial changes also occur concurrent with the disruption of astrocytes on the fifth day. Their changes at this time appear to be of a phagocytic nature, and are possibly a response of these cells to the products of cell disintegration.

#### The Electron and Light Microscopy of Edema in the Central Nervous System

As explained above, the swelling and disruption of astrocytes following irradiation, apparently represents a form of edema common to many injuries. The formation of large spaces and the general "loosening" of the tissues appear to be directly related to the disruption of astrocytes. According to

these findings, there seems to be no disparity between the edema seen with light microscopy and that seen with electron microscopy. Enlargements of the extracellular space are quite evident with electron microscopy in the more severe stages of injury, and are very likely comparable to those seen with light microscopy. However, it should be emphasized that edema of the brain is due initially to swollen cells and only later to accumulation of interstitial fluid.

### The Penetration of Ferritin

Under normal conditions the injected ferritin is found in the endothelium and basement membrane of capillaries, but is only rarely seen to penetrate deeper into the tissue.

In those capillaries showing early damage following irradiation, the ferritin has accumulated in damaged endothelial cells and in the basement membrane. If either of these structures were the site of a barrier mechanism, one would expect that under these conditions the ferritin would have penetrated the tissue. And yet, there is no significant change in the penetration of ferritin into the tissues external to these capillaries. Nor is there a change in penetration into the tissue at the periphery of capillaries in which the basement membrane is split and contains increased amounts of the ferritin.

A significant change in the penetration of ferritin into deeper portions of the tissue is not seen until the extracellular gap becomes enlarged. At this time, ferritin appears to pass readily into the enlarged spaces, and is also seen in increased amounts within many of the cells.

This correlation between the entrance of greatly increased amounts of ferritin and the sudden expansion of the extracellular space suggests that the

compactness of the tissue external to capillaries is the primary factor in the limited entrance of ferritin, during the previous periods and in normal tissue. This tends to support the view of Maynard et al. ('57) who believe that the slow entrance of substances into the central nervous system is a result of the lack of extracellular space in this tissue and the necessity of substances to enter directly into cells. The increased amount of ferritin within the cells of the irradiated neural tissue is probably due to the greater exposure of their surface to this substance. It is also probable that some of the cells are damaged, and thus may be more easily penetrated by the ferritin.

To the extent that the penetration of ferritin may be similar to the penetration of vital dyes, the events of the fifth day may coincide with what some investigators consider to be a "break down" of the blood-brain barrier.

#### Changes in Astrocytes Other Than Swelling

Some of the formations occurring in astrocytes following irradiation, e.g., an increase in cytoplasmic vesicles and granules and the presence of membranous whorls, seems to be a reaction of the cytoplasm to the injury. Many of these cells also show an increased denseness of the nucleus and appear to be quite viable. The significance of these changes remains obscure. These astrocytes are not similar to the reactive astrocytes seen by other investigators, where numerous fibrils are formed in the cytoplasm (Hager et al. '62). Perhaps they are anomalous forms of reactive astrocytes, or astrocytes in which the reactive process is interrupted by the severity of the injury.

#### Changes in Perivascular Cells and the Source of Phagocytes in the Irradiated Tissue

As shown by Torack ('61) in other injuries of this tissue, and seen again



during radiation injury, perivascular cells appear to be a source of phagocytes in the damaged central nervous system. Their early changes within the basement membrane are definitely those of differentiating phagocytes.

These changes may also be related to splitting and formation of fibrils in the basement membrane. As perivascular cells change in form, they may withdraw their elongate processes from some areas of the basement membrane. Since these processes are surrounded by the basement membrane, their withdrawal could result in the formation of perivascular spaces, bordered on both sides by basement membrane material, as seen in these observations. The potentialities of these cells, in that they apparently belong to the reticulo-endothelial system (and may be adventitial histiocytes) suggest that they may be responsible for the production of fibrils in the altered basement membrane as they become active in this area.

If phagocytic perivascular cells invade the tissues, as suggested by the similarity of these cells to a number of phagocytes seen in the tissues during the later phases of injury, they may do so by ingesting the basement membrane material. This is indicated by diminished basement membranes at the border of a few of these cells.

Most of the phagocytes which are not formed from perivascular cells, apparently enter the tissues from the blood. Microglial cells are not found to show phagocytic characteristics under the conditions of this experiment. Since it is commonly accepted that these cells transform into phagocytes in the injured central nervous system, perhaps they are inhibited in this function by the radiation.

As mentioned earlier, the changes in oligodendroglial cells suggest that

they may also have phagocytic properties. Admittedly, the oligodendroglial cells are not easily identified under these conditions, and the observed cells may be phagocytes of another origin. However, this would indicate a conspicuous absence of oligodendroglia from the tissues, an absence that would be difficult to explain, since oligodendroglial cells are not seen to undergo disintegration from the normal structure.

## CONCLUSIONS

1. Changes in capillaries and astrocytes are early events following irradiation of the cerebral cortex of the rat.
2. The swelling and disruption of astrocytes is the major change following irradiation.
3. Edema of the brain is due initially to the swollen astrocytes, and later to disruption of astrocytes and formation of large intercellular spaces.
4. Alterations in nerve cells, microglia and oligodendroglia are later events and probably are secondary to the destruction of astrocytes.
5. The relatively poor penetration of ferritin into the cerebral cortex under normal conditions and during the early periods following irradiation seems to be related to the compactness of the tissue and thus to the necessity that substances pass directly into cells. The enhanced entrance of ferritin as edematous spaces occur in the tissue, may coincide with what some authors consider to be a "break down" of the blood-brain barrier.
6. Changes in astrocytes, other than swelling, appear to represent a form of reactivity of the astrocytes to injury; however, these cells are not similar to reactive astrocytes seen by other authors.
7. Perivascular cells form phagocytes in the irradiated brain, a response that apparently occurs during other injuries. Their activity during injury may be responsible for the formation of perivascular spaces and fibrils within the basement membrane. It is possible that a number of the phagocytes seen in

the injured tissues distant from capillaries are differentiated perivascular cells.

8. Oligodendroglia may also become phagocytic under these conditions.

9. The remaining phagocytes seem to be formed by elements from the blood.

10. Microglial cells are not seen to become phagocytes; they are possibly inhibited in this function by the irradiation.

# LITERATURE CITED

- Alexander, P. 1961 Radiobiology. In: Proceedings of the Third Australasian Conference on Radiobiology held at the University, Sydney, August 1960. Ed. by P. L. T. Ilbery. Butterworths, London. Chap. I, 1-16.
- Arnold, A., P. Bailey, R. A. Harvey, L. L. Haas and J. S. Laughlin 1954 Changes in the central nervous system following irradiation with 23-mev x-rays from the betatron. Radiology, 62: 37-44.
- Bailey, O. T. 1962 Response of the Nervous System to Ionizing Radiation. Ed. by T. J. Haley and R. S. Snider. Academic Press, New York and London. Part II, 165-189.
- Bakay, L. 1956 The Blood-Brain Barrier. Charles C. Thomas, Springfield, Illinois.
- Bennett, H. S. 1956 A suggestion as to the nature of the lysosome granules. J. Biophys. Biochem. Cytol., 2, No. 4, Suppl., 185.
- Bennett, H. S., J. H. Luft and J. C. Hampton 1959 Morphological classifications of vertebrate blood capillaries. Amer. J. Physiol., 196: 381-390.
- Brinkman, R. and H. B. Lamberts 1960 Examples of immediate low-level x-ray effects: their significance for the study of chemical protection. Intern. J. Radiobiol., Suppl. 1, 167-181.
- Broman, T. and O. Olsson 1948 A tolerance of cerebral blood vessels to a contrast medium of the diodrast group. Acta Radiol., 30: 326-342.
- \_\_\_\_\_ 1949 An experimental study of contrast media for cerebral angiology with reference to possible injurious effects on the cerebral blood vessels. Acta Radiol., 31: 321-334.
- Clemente, C. D., J. Yamasaki, L. Bennett, R. McFall and E. H. Maynard 1961 Proc. Second International Conference on the Peaceful Uses of Atomic Energy. United Nations, Geneva. Volume XXII, 369-382.
- Clemente, C. D. and H. E. Richardson 1962 Response of the Nervous System to Ionizing Radiation. Ed. by T. J. Haley and R. S. Snider. Academic Press, New York and London. Part III, 411-428.

- de Duve, C. 1959 Subcellular Particles. Ed. by T. Hayashi. The Ronald Press Co., New York. Session III, 128-159.
- Dempsey, E. W. and G. B. Wislocki 1955 An electron microscopic study of the blood-brain barrier, employing silver nitrate as a vital stain. J. Biophys. Biochem. Cytol., 1: 245-256.
- De Robertis, E. and H. M. Gerschenfeld 1961 International Review of Neurobiology. Ed. by C. C. Pfeiffer and J. R. Smythies. Academic Press, New York and London. Vol. III, Chap. I, 1-65.
- Dobbing, J. 1961 The blood-brain barrier. Physiol. Revs., 41: 130-188.
- Ehrlich, P. 1885 Das Sauerstoff-Bedürfnis des Organismus. In: Eine Farbenanalytische Studie. Berlin. Cited by Tschirgi, R. D. 1960 Handbook of Physiology. Ed. by J. Field. American Physiological Society, Washington, D. C. Section I, Vol. 3, Chap. LXXVIII, 1871.
- Evans, J. P., E. Tani and A. J. Raimondi 1961 An electron microscopic study of brain swelling. Trans. Amer. Neurol. Assoc., 86: 28-29.
- Farquhar, M. G. and J. F. Hartmann 1956 Electron microscopy of cerebral capillaries. Anat. Rec., 124: 288-289.
- \_\_\_\_\_ 1957 Neuroglia structure and relationships as revealed by electron microscopy. J. Neuropath. Exp. Neurol., 16: 18-39.
- Farrant, J. L. 1954 An electron microscopic study of ferritin. Biochimica et. Biophysica Acta, 13: 569-576.
- Feigen, I. and N. Popoff 1962 Neuropathological observations on cerebral edema. Arch. Neurol., 6: 151-160.
- Goldmann, E. E. 1913 Vitalfärbung am Zentralnervensystem. Reimer, Berlin. Cited by Tschirgi, R. D. 1960 Handbook of Physiology. Ed. by J. Field. American Physiological Society, Washington, D. C. Section I, Vol. 3, Chap. LXXVIII, 1872.
- Granick, S. 1942 Ferritin. I. Physical and chemical properties of horse spleen ferritin. J. Biol. Chem., 146: 451-461.
- Gray, E. G. 1961 Electron Microscopy in Anatomy. Edward Arnold Ltd., London. Chap. VI, 54-73.
- Hager, H., W. Hirschberger and A. Breit 1962 Response of the Nervous System to Ionizing Radiation. Ed. by T. Haley and R. Snider. Academic Press, New York and London. Part II, 261-276.

- Luft, J. H. 1961 Improvements in epoxy resin embedding methods. J. Biophys. Biochem. Cytol., 2: 409-414.
- Luse, S. A. 1956 Electron microscopic study of the central nervous system. J. Biophysic. and Biochem. Cytol., 2: 531-543.
- \_\_\_\_\_ 1960 The ultrastructure of normal and abnormal oligodendroglial cells. Anat. Rec., 138: 461-492.
- Macklin, C. C. and M. T. Macklin 1920 A study of brain repair in the rat by the use of trypan blue, with special reference to the vital staining of macrophages. Arch. Neurol. Psychiat., 4: 353-394.
- Maynard, E. A., R. L. Schultz, and D. C. Pease 1957 Electron microscopy of the vascular bed of rat cerebral cortex. Amer. J. Anat., 100: 409-433.
- Mogilnitzsky, B. N. and L. D. Podljaschuk 1930 Röntgenstrahlen und sogenannte Hämatoenzephalische Barrier. Fortschr. Gebiete Röntgenstrahlen, 41: 66-75.
- Palade, G. E. 1952 A study of fixation for electron microscopy. J. Exp. Med., 95: 285-298.
- \_\_\_\_\_ 1961 Blood capillaries of the heart and other organs. Circulation, 24: 368-384.
- Palay, S. L. and G. E. Palade 1955 The fine structure of neurons. J. Biophys. Biochem. Cytol., 1: 69-88.
- Pease, D. C. 1960 The basement membrane: substratum of histological order and complexity. Proc. 4th Int. Conf. on Elect. Micros. Springer-Verlag, Berlin. Vol. II, 139-155.
- Pitcock, J. A. 1962 An electron microscopic study of acute radiation injury of the rat brain. Lab. Invest., 11: 32-44.
- Prados, M., B. Strowger and W. Feindel 1945 Studies on cerebral edema: II. Reaction of the brain to exposure to air; physiologic changes. A. M. A. Arch. Neurol. Psychiat., 54: 290-300.
- Rachmanow, A. 1926 Zur Frage über die Wirkung der Röntgenstrahlen auf das Zentralnervensystem. Strahlentherapie, 23: 318-325.
- Rodriguez, L. A. 1955 Experiments on the histologic locus of the hemato-encephalic barrier. J. Comp. Neurol., 102: 27-46.
- Ross, R. and E. P. Benditt 1961 Wound healing and collagen formation. I. Sequential changes in components of guinea pig skin wounds observed in the electron microscope. J. Biophys. Biochem. Cytol., 11: 677-700.

- Scholz, W., W. Schlote and W. Hirschberger 1962 Response of the Nervous System to Ionizing Radiation. Ed. by T. J. Haley and R. S. Snider. Academic Press, New York and London. Part II, 211-232.
- Schultz, R. L., E. A. Maynard and D. C. Pease 1957 Electron microscopy of neurons and neuroglia of cerebral cortex and corpus callosum. Amer. J. Anat., 100: 369-407.
- Torack, R. M. 1961 Ultrastructure of capillary reaction to brain tumors. Arch. Neurol., 2: 416-428.
- Torack, R. M., R. D. Terry and H. M. Zimmerman 1959 The fine structure of cerebral fluid accumulation. I. Swelling secondary to cold injury. Amer. J. Pathol., 35: 1135-1147.
- \_\_\_\_\_ 1960 The fine structure of cerebral fluid accumulation. II. Swelling produced by triethyl tin poisoning and its comparison with that in the human brain. Amer. J. Pathol., 36: 273-287.
- Van Breeman, V. L. and C. D. Clemente 1955 Silver deposition in the central nervous system and the hematoencephalic barrier studied with the electron microscope. J. Biophys. Biochem. Cytol., 1: 161-166.
- Van Dyke, D. C., P. Janssen and C. A. Tobias 1962 Response of the Nervous System to Ionizing Radiation. Ed. by T. J. Haley and R. S. Snider. Academic Press, New York and London. Part III, 369-381.
- Wissig, S. L. 1958 An electron microscope study of the permeability of capillaries in muscle. Anat. Rec., 130: 467.
- Wyckoff, R. W. G. and J. Z. Young 1956 The motorneuron surface. Proc. Roy. Soc., B144: 440-450.
- Zeman, W. 1961 Fundamental Aspects of Radiosensitivity: Brookhaven Symposia in Biology. Vol. 14, Session IV, 176-199.



TABLE 1

## FIXATION AND EMBEDDING SOLUTIONS

---

2% buffered osmium tetroxide (Palade, '52)

0.14 M sodium acetate and sodium veronal buffer . . . . .	2 parts
0.1 N hydrochloric acid . . . . .	2 parts
Mammalian Ringer's solution (Carolina Biological Supply Company) . . . . .	1 part
4% osmium tetroxide (Merck) in distilled water . . . . .	5 parts
(pH of this solution is approximately 7.3)	

## Epon embedding medium (Luft, '61)

Epon 812 (Shell Chemical Company) . . . . .	45 cc
Dodecenyl succinic anhydride (National Aniline Division, Allied Chemical Company) . . . . .	35 cc
Methyl nadic anhydride (National Aniline Division, Allied Chemical Company) . . . . .	20 cc
2,4,6,-tri (dimethylaminomethyl) phenol - DMP 30 Rohm and Haas Company) used as an accelerator . . . . .	1.8 cc

**TABLE II**  
**FIXATION, DEHYDRATION, AND EMBEDDING PROCEDURE**

---

**Fixation**

2% buffered osmium tetroxide (temperature 4°C.) . . . . . 60 min

**Dehydration**

50% ethanol . . . . . 10 min  
 70% ethanol (tissues slices trimmed during this step) . . . . . 30 min  
 95% ethanol (3 changes) . . . . . 30 min  
 100% ethanol (3 changes) . . . . . 30 min

**Embedding**

1 part Epon mixture without accelerator to 2 parts 100% ethanol  
 (with continuous agitation) . . . . . 30 min  
 1 part Epon mixture without accelerator to 1 part 100% ethanol  
 (with continuous agitation) . . . . . 30 min  
 2 parts Epon mixture without accelerator to 1 part 100% ethanol  
 (with continuous agitation) . . . . . 30 min  
 Epon mixture without accelerator . . . . . 30 min  
 Epon mixture plus DMP 30 (2 changes) . . . . . 60 min  
 Tissues transferred to gelatin capsules containing Epon mixture  
 plus DMP 30 and polymerization was effected in paraffin-ovens  
 according to the following progression:

35°C. . . . . 6 to 12 hours  
 45°C. . . . . 6 to 12 hours  
 60°C. . . . . overnight

**TABLE III**  
**EXPERIMENTAL ANIMALS AND SPECIAL PROCEDURES**

<b>Days after irradiation</b>	<b>No. of animals irradiated</b>	<b>No. injected with ferritin</b>	<b>Length of time between injection and sacrifice, hr</b>
1	4	1	1
2	5	2	1--2
3	6	4	2
4	3		
5	3	1	2
6	2		
7	4	1	2
8	3	1	2

## PLATE 1

## EXPLANATION OF FIGURE

- 1 Normal cerebral cortex. A capillary (C) containing an erythrocyte (E) is seen to the right in the field. The capillary endothelium (EN) is surrounded by a dense basement membrane (BM) which encloses perivascular cells (PVC). Astrocyte processes (AP) are in contact with much of the area peripheral to the capillary, and are also seen throughout the tissue as a whole. Cell bodies of an astrocyte (A), an oligodendroglial cells (O) and a neuron (N) are also found in the field. Note the differences of their nuclei (NU). X 7,000.

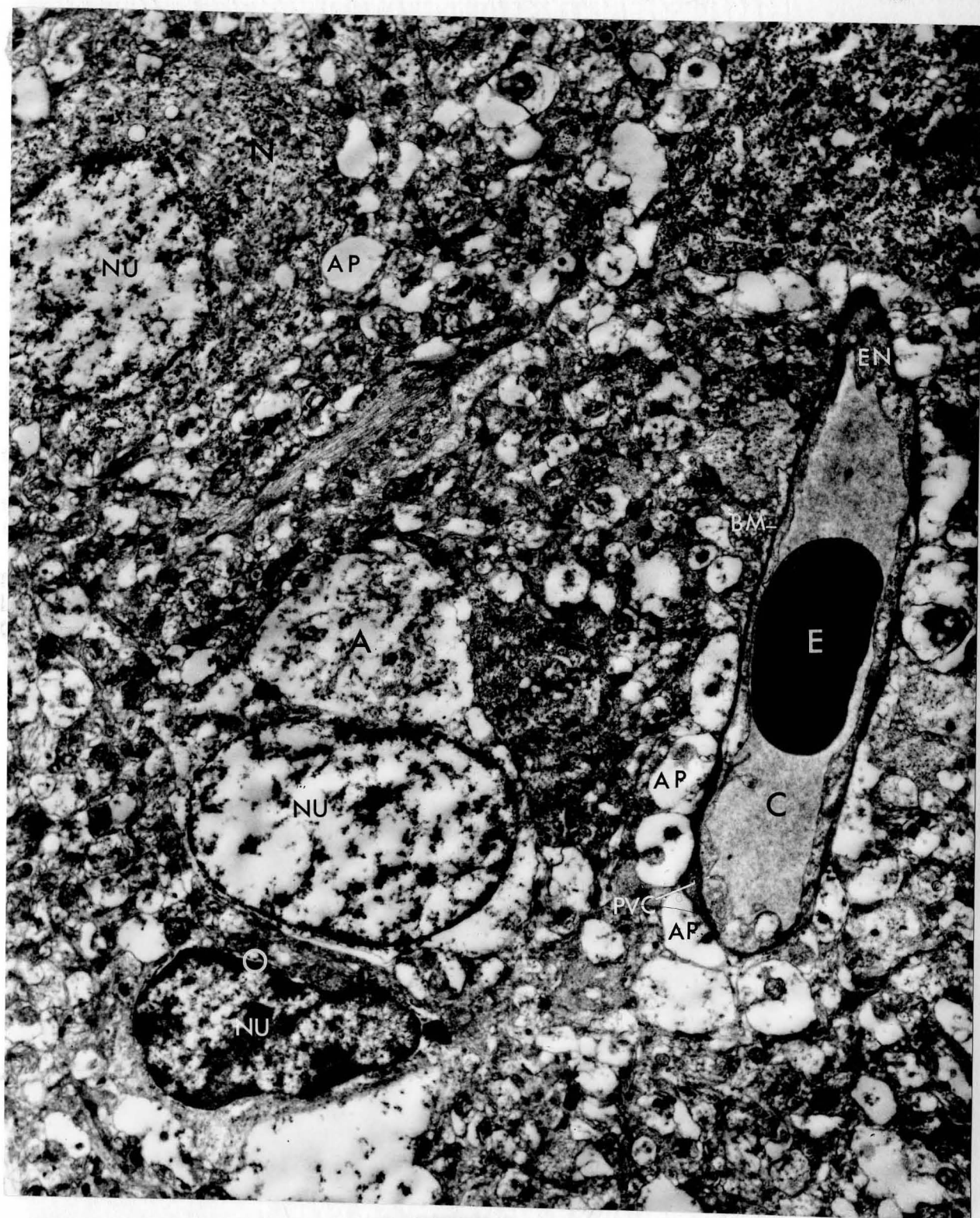
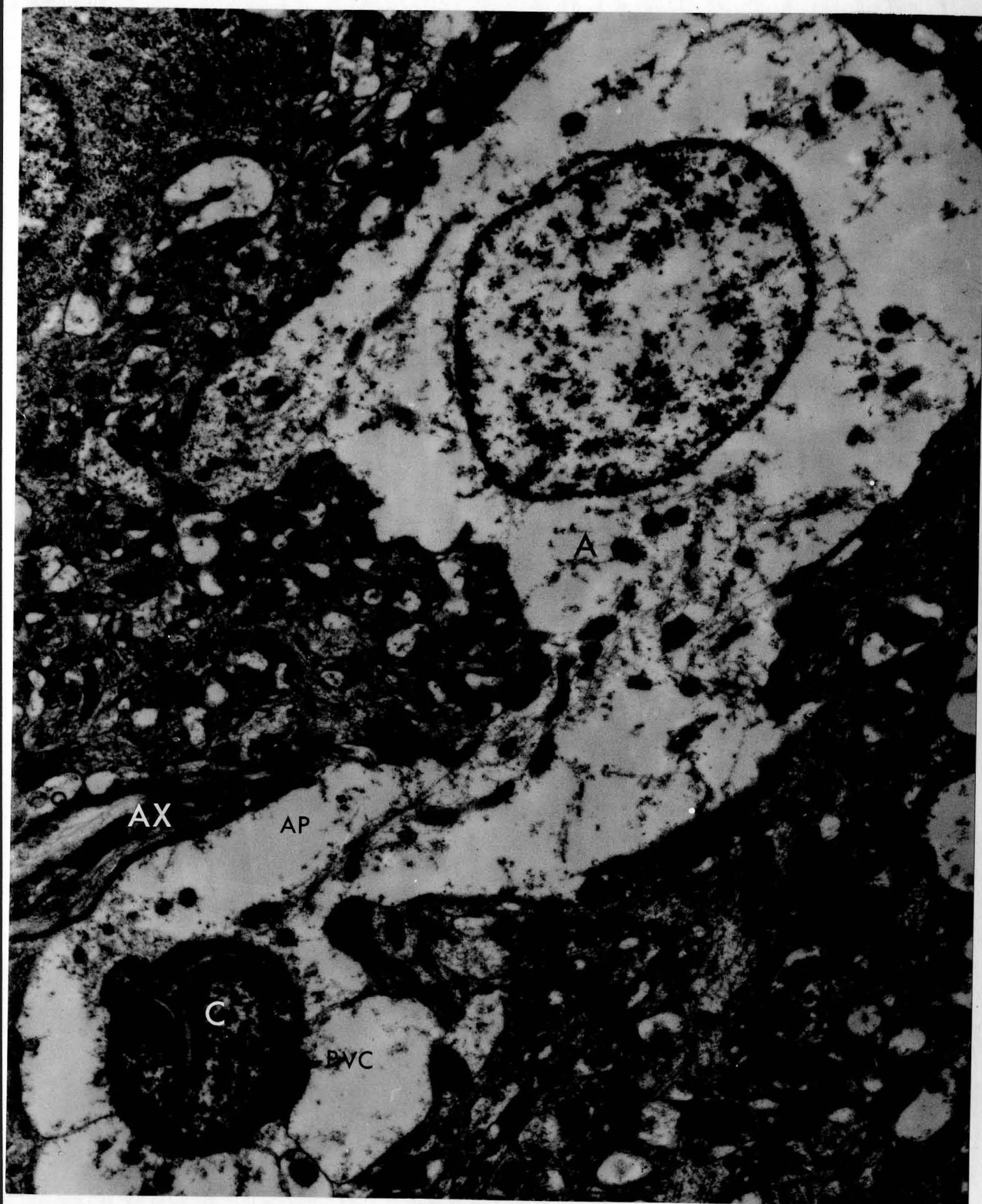

FIGURE 1

## PLATE 2

## EXPLANATION OF FIGURE

- 2 An essentially normal area in the cerebral cortex, 1 day after irradiation. An astrocyte process (AP) is seen to extend from the cell body (A) and attach to a capillary (C). Note the perivascular cells (PVC) at the periphery of the capillary, and the axons (AX) above the astrocyte process. X 8,300.

**FIGURE 2**

## PLATE 3

## EXPLANATION OF FIGURE

- 3 An essentially normal area in the cerebral cortex, 1 day after irradiation. Two neurons (N), an astrocyte (A) and a microglial cell (MI) are present in the field. Note the denseness of the nucleus (NU) of the microglial cell. A dendrite (D) and an axon (AX) can also be seen. X 4,500.



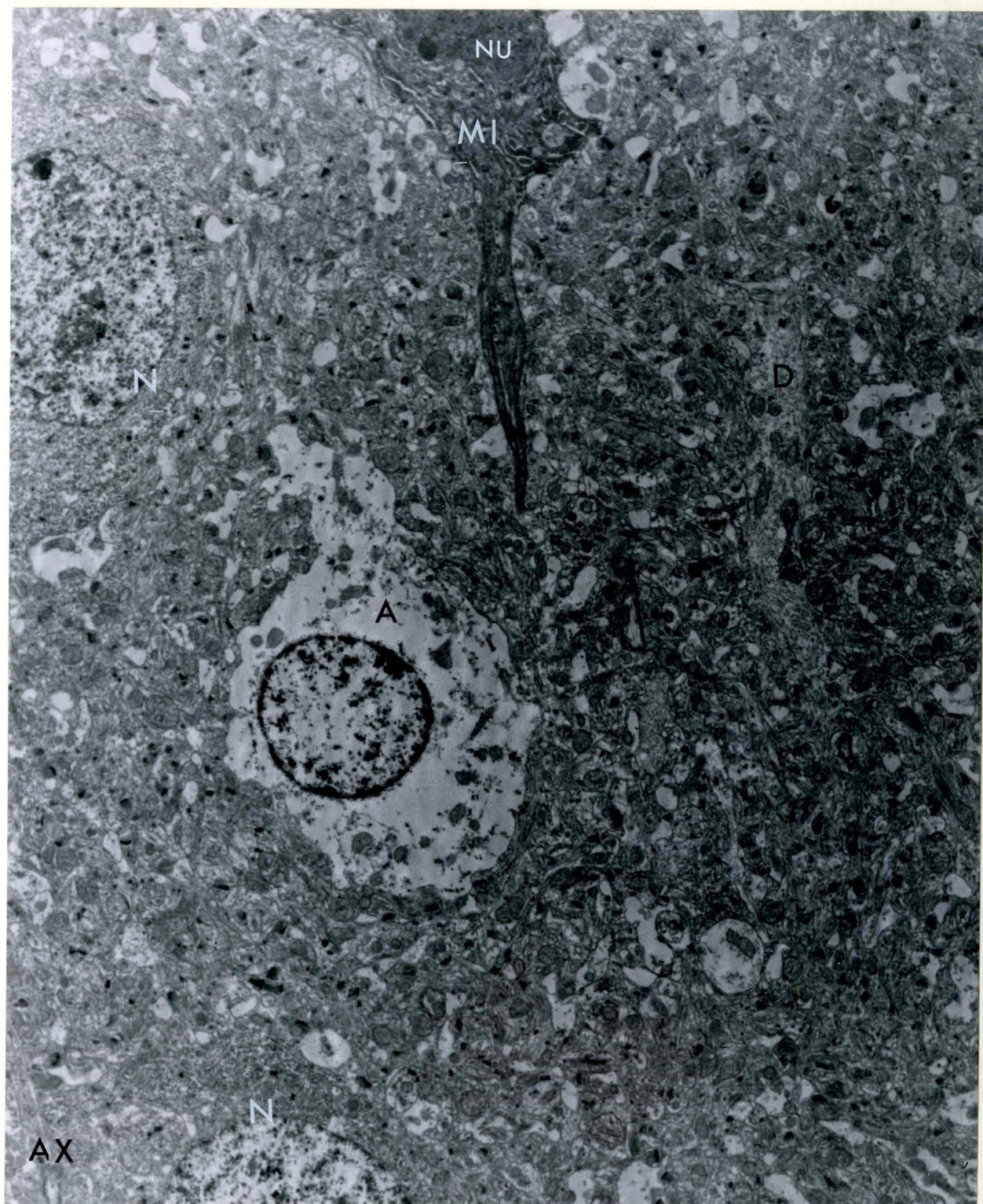


FIGURE 3

**PLATE 4****EXPLANATION OF FIGURE**

- 4 A portion of a normal neuron. Chromatin material is dispersed throughout the nucleus (NU). Cisternae of endoplasmic reticulum (ER) separate clusters of granules. Mitochondria (M) and dense bodies (DB) are also present in the perikaryon. Note the narrow gap (arrows) that represents the typical extracellular space in the central nervous system. X 24,000.



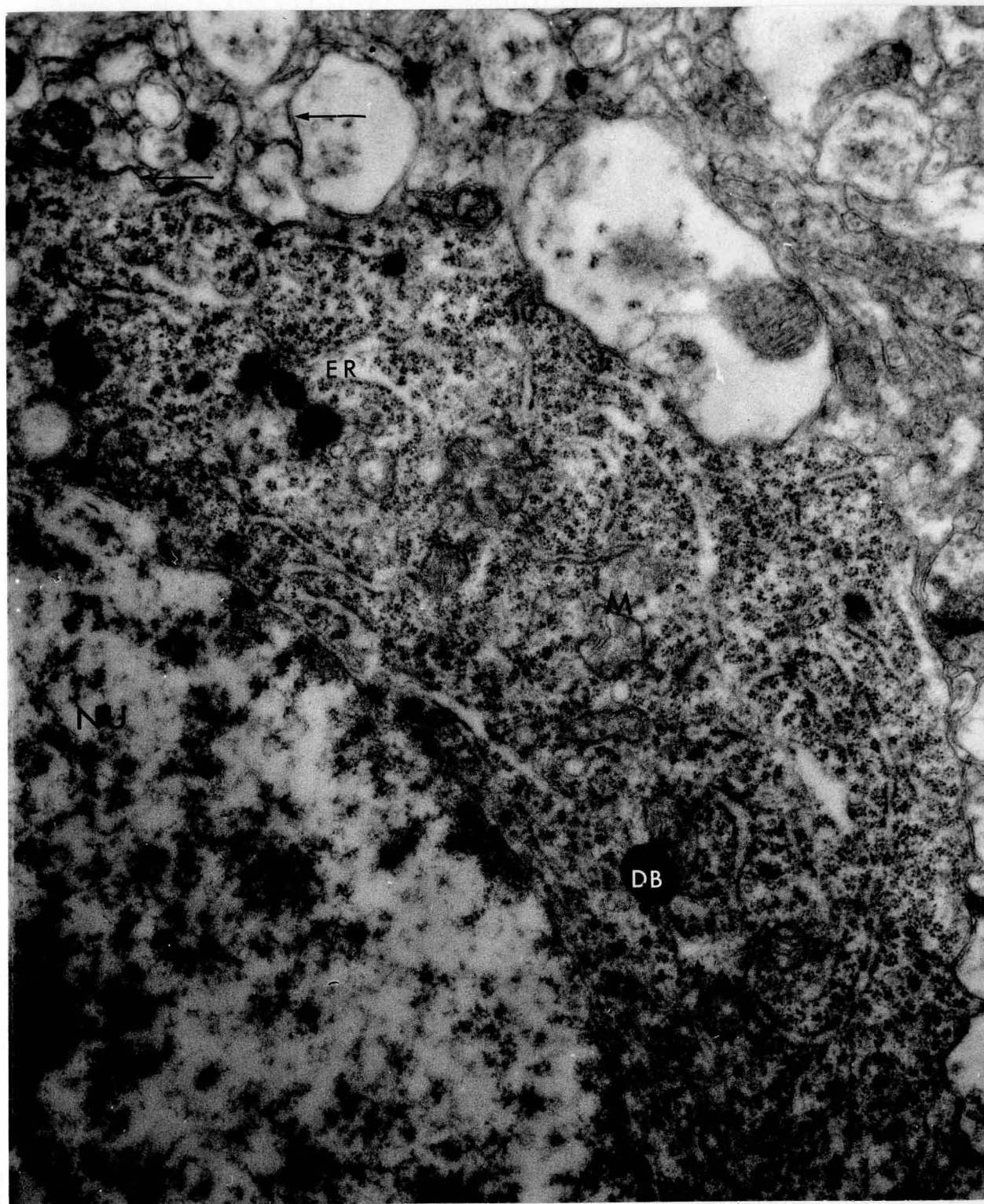


FIGURE 4

## PLATE 5

## EXPLANATION OF FIGURE

- 5 An essentially normal area in the cerebral cortex, 1 day after irradiation. An erythrocyte (E) is seen in the lumen of a capillary. The endothelial cells (EN) contain small vesicles, and are found to overlap in several areas (J). The basement membrane (BM) is recognized as an amorphous substance consisting of three distinct zones (arrows), at the periphery of the capillary. A perivascular cell (PVC) is seen to be surrounded by all three zones of the basement membrane. Astrocyte processes (AP) are present external to the basement membrane. Note the small extracellular space in the tissue. X 36,000.



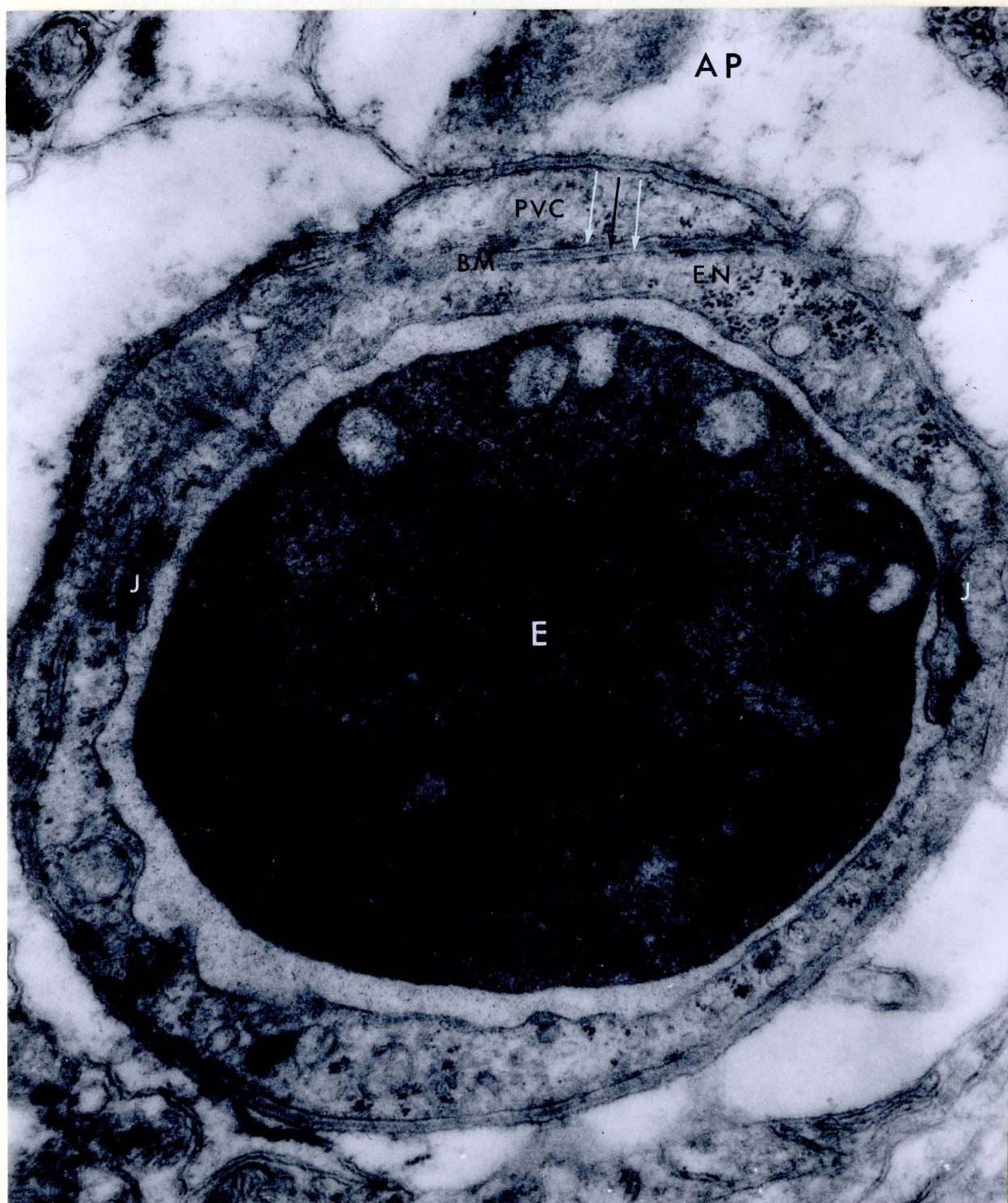


FIGURE 5

## PLATE 6

## EXPLANATION OF FIGURE

- 6 Normal cerebral cortex. A perivascular cell (PVC) is seen within the basement membrane (BM) of a capillary (C). Much of the cytoplasm is granular; the numerous vesicles (G) in the upper portion of the cell may be the result of an oblique section through the golgi apparatus. X 16,000.

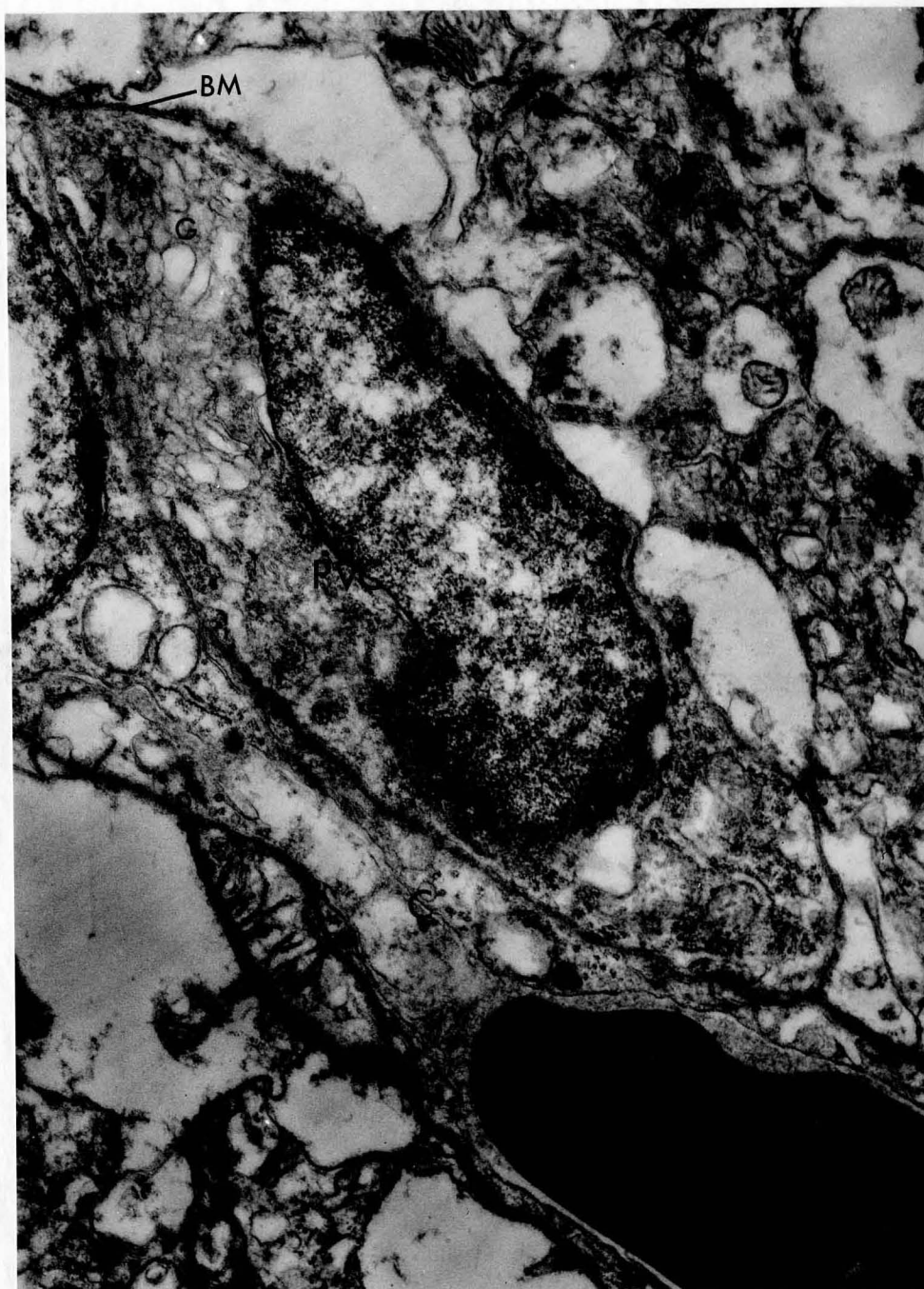


FIGURE 6

**PLATE 7****EXPLANATION OF FIGURE**

- 7 Tissue from the cerebral cortex, 5 days after irradiation. The small dark areas in the tissue are probably the result of petechial hemorrhages. X 12.



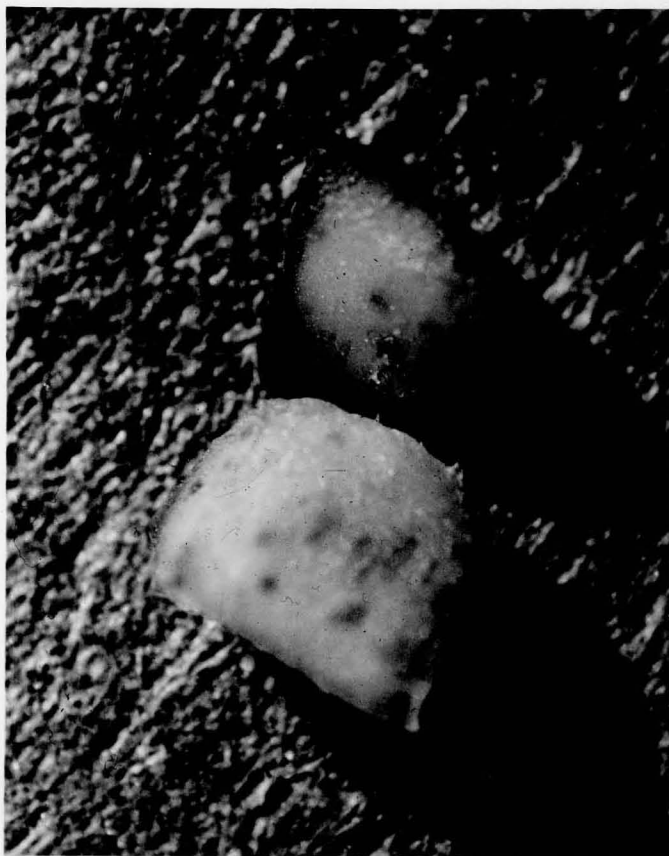


FIGURE 7

## PLATE 8

## EXPLANATION OF FIGURE

- 8 An altered area in the cerebral cortex, 1 day after irradiation. A capillary (C) contains an accumulation of dense material in the lumen (L), indicating a form of thrombosis. The astrocyte process (AP) above the capillary contains osmiophilic matter (IN) and an increased number of vesicles in the cytoplasm. A portion of a perivascular cell (PVC) is seen in the lower region of the field. X 17,000.

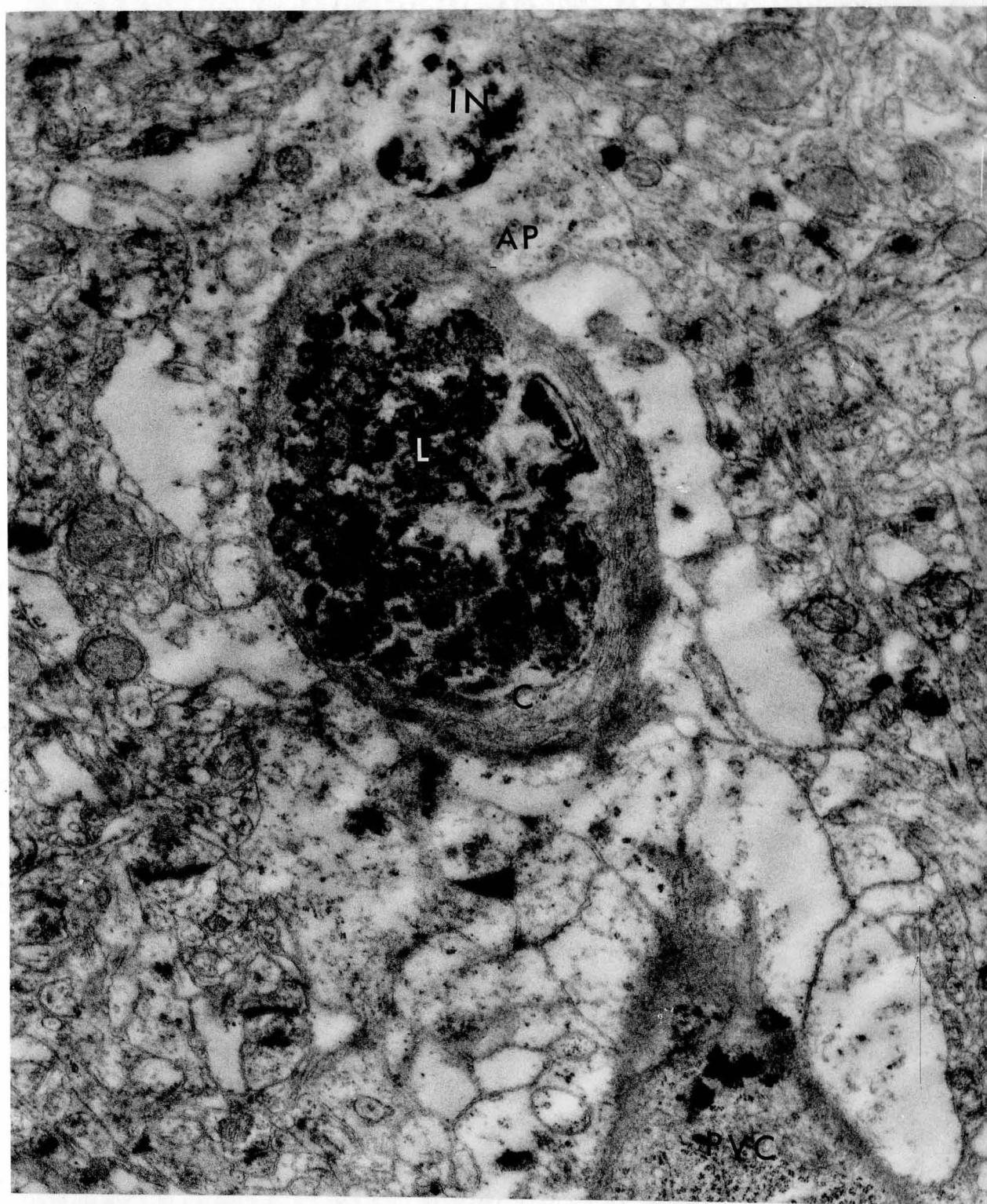


FIGURE 8

## PLATE 9

## EXPLANATION OF FIGURE

- 9 A damaged capillary in the cerebral cortex, 2 days after irradiation. The lumen of the capillary contains a vacuolated mass (R) and dense amorphous material (T) both of which are of questionable origin. The endothelium (EN) is thin and crowded with dark granules. A swollen mitochondrion (SM) and a mitochondrion lacking internal structure (DM) are seen in the endothelium. Ferritin has infiltrated a mitochondrion (DM), and appears in increased amounts in the basement membrane (arrows). X 24,000.



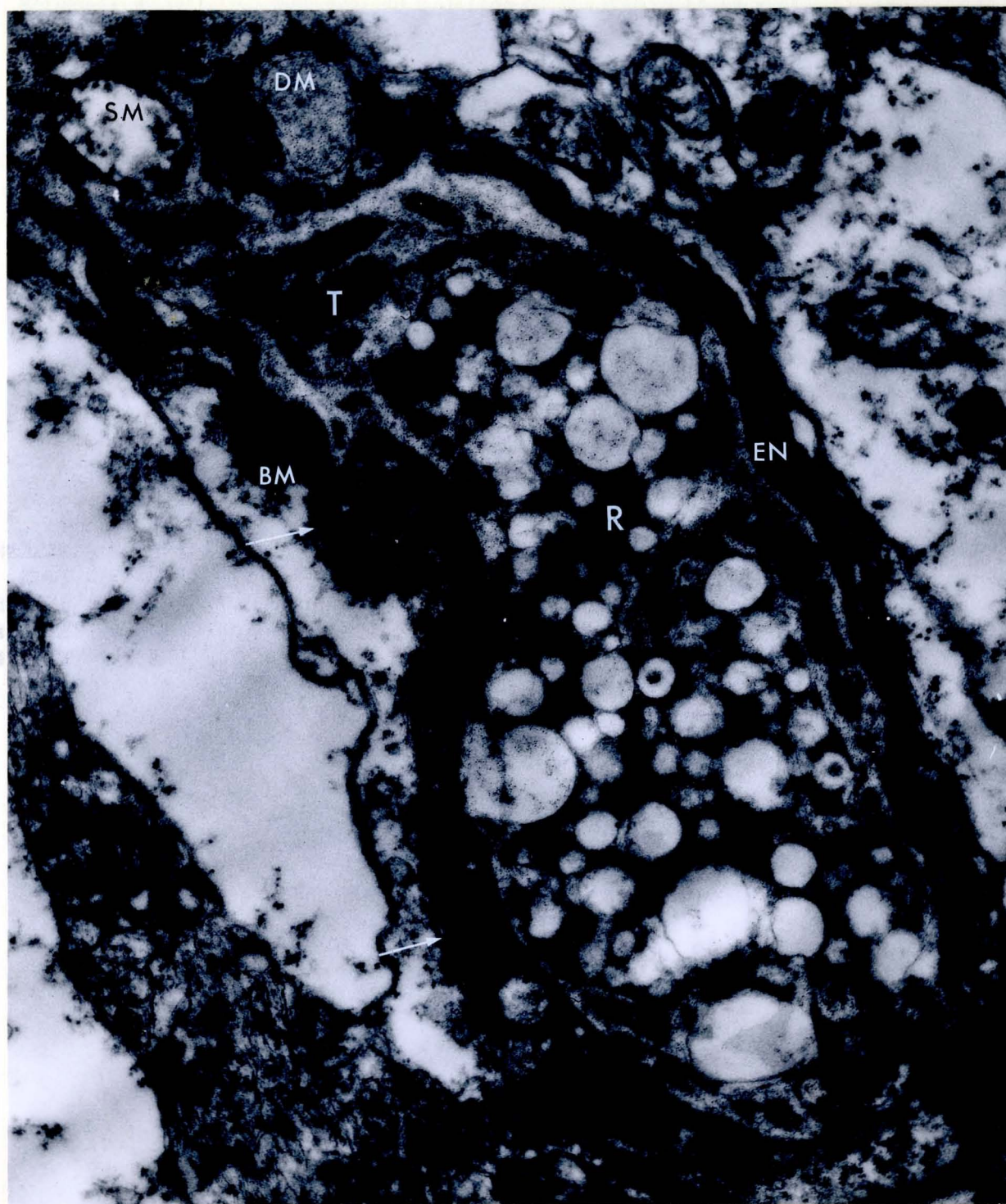


FIGURE 9

## PLATE 10

## EXPLANATION OF FIGURE

- 10 An altered area of the basement membrane, 2 days after irradiation. The basement membrane (BM) is thickened to over 2000 A in some areas, and contains indistinct fibrils (arrows). The endothelium (EN), perivascular cells (PVC), astrocyte process (AP) do not show significant changes. X 58,800.



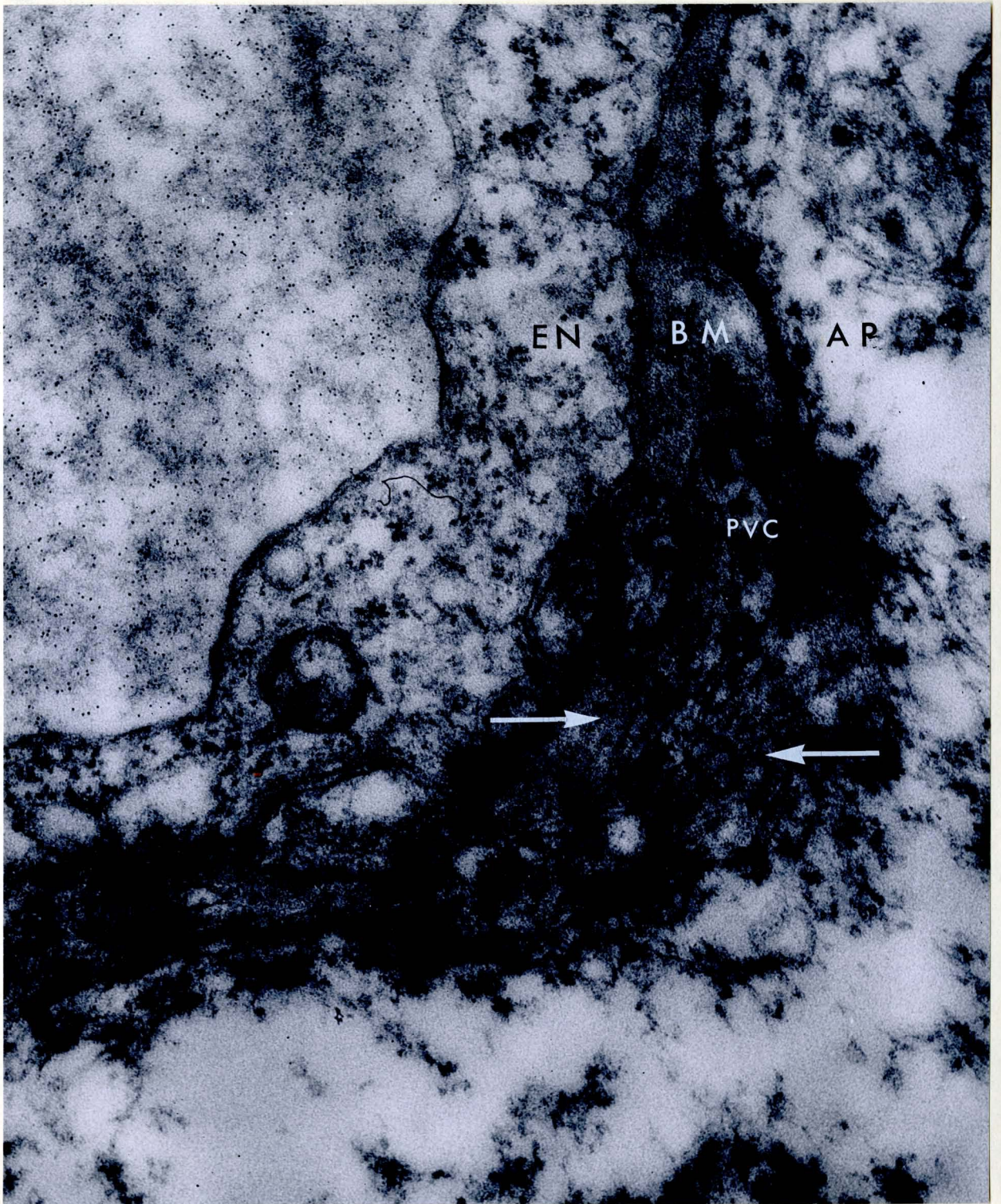


FIGURE 10

## PLATE 11

## EXPLANATION OF FIGURE

- 11 An altered area in the cerebral cortex, 2 days after irradiation. Swollen astrocyte processes (SAP) occupy the greatest portion of the field. Some of the mitochondria are swollen (SM) and ruptured (XM). An abundance of peculiar formations (See text, page 16) are also evident in the cytoplasm. A space (PS) is seen at the periphery of a capillary (C) and extending obliquely across the field between swollen astrocyte processes. The presence of dense material on both sides of the space (arrows) indicates that it is formed by a splitting of the basement membrane. The manner in which the space extends across the field is probably due to an arching of the capillary, above or below this section. The cells (PVC) seen within the space are very likely perivascular cells. X 6,300.



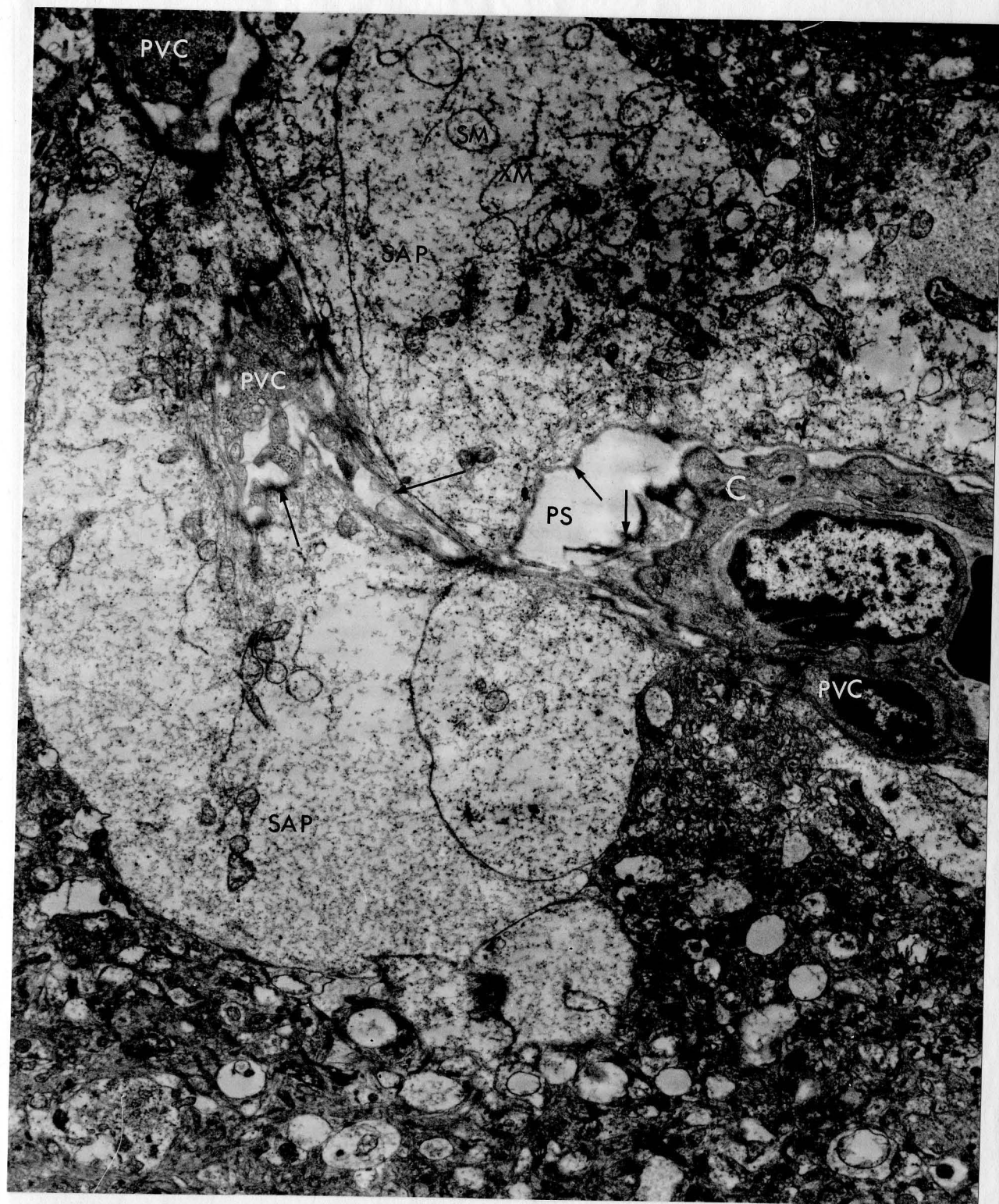


FIGURE 11

## PLATE 12

## EXPLANATION OF FIGURE

- 12 A pericapillary space (PS) in the cerebral cortex, 2 days after irradiation. Dense material of the basement membrane (BM<sub>1</sub> and BM<sub>2</sub>) is seen at the border of endothelial (EN) and perivascular cells (PVC) of a capillary, and also at the border of an astrocyte process (AP). Cross-banded fibrils (F) are present within the clear perivascular space. Ferritin (arrows) can be seen in increased amounts in the endothelium, perivascular cells, and various areas of the basement membrane, including the pericapillary space. X 74,000.



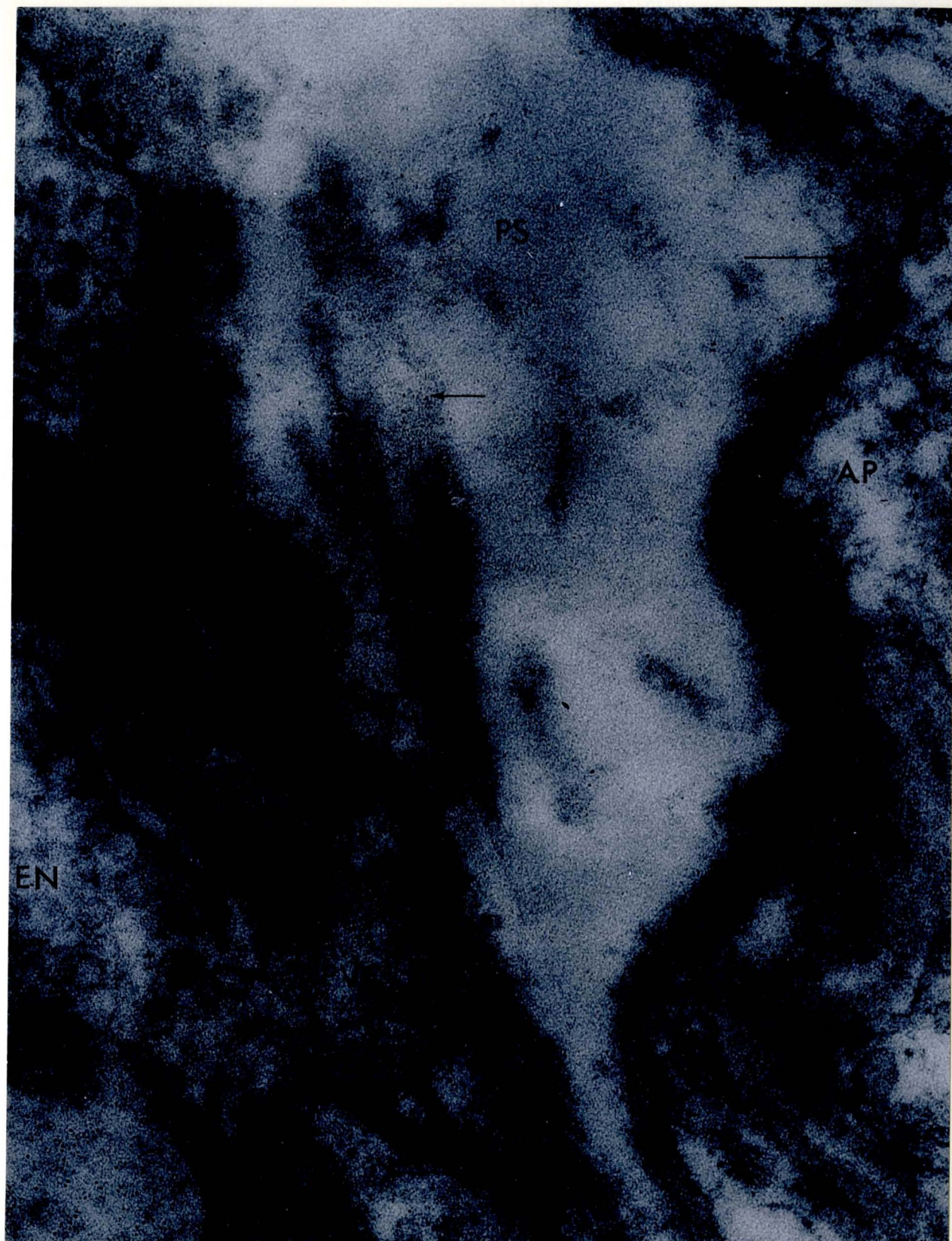

FIGURE 12

## PLATE 13

## EXPLANATION OF FIGURE

- 13 An altered perivascular cell in the cerebral cortex, 2 days after irradiation. A perivascular cell (PVC) is seen to be spheroidal in cross section, and contains an indented nucleus. Cytoplasmic extensions (arrows), some of which engulf osmiophilic material (IN), are present at the periphery of the cell. The basement membrane (BM) appears to be ill-defined at the upper portion of the cell, and is split (PS) in the region below. The endothelium (EN) of the capillary (C) is irregular in form. Note the excessive granules in the astrocyte processes (AP) at the periphery of the capillary. X 16,200.



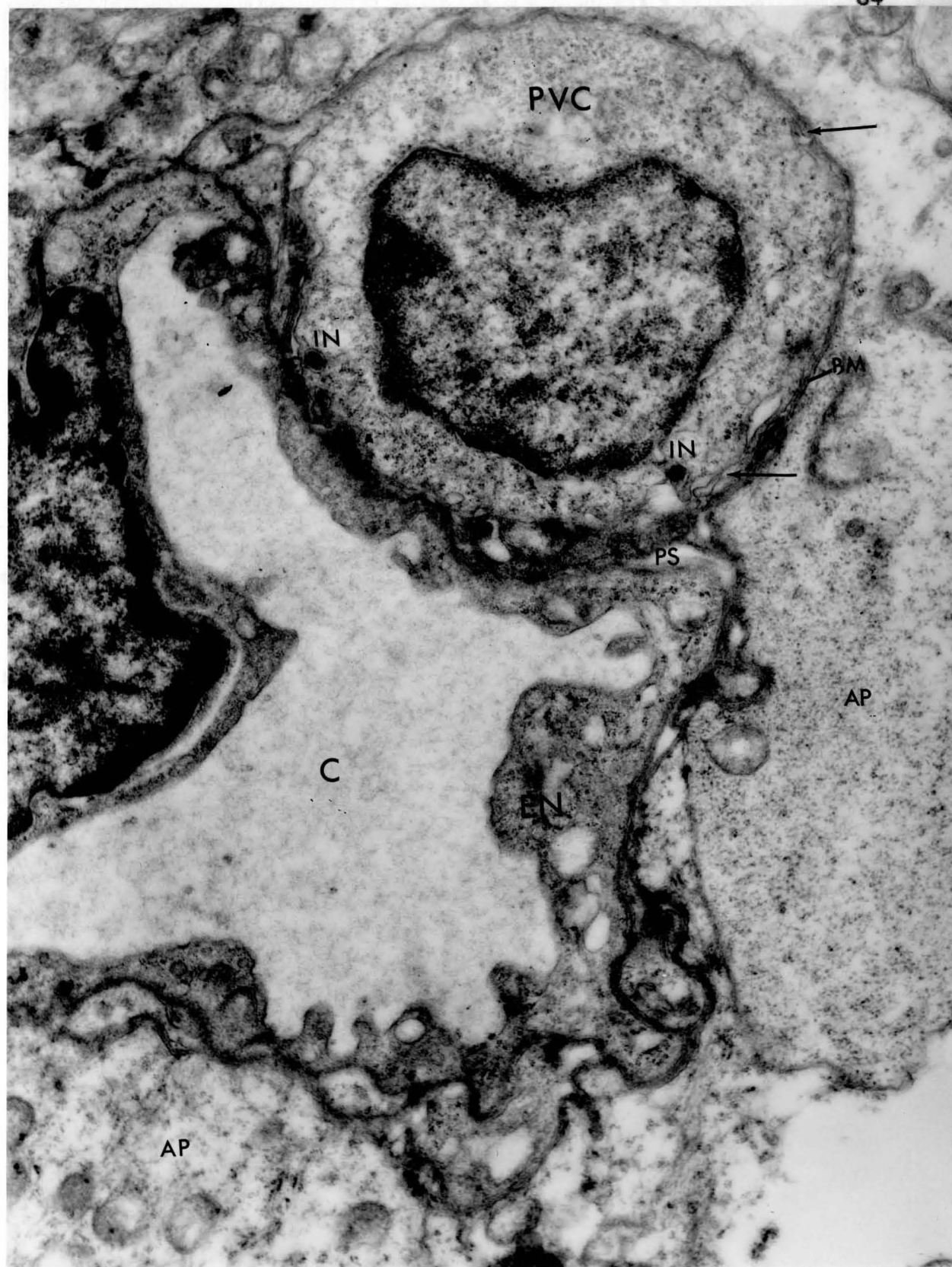

FIGURE 13

## PLATE 14

## EXPLANATION OF FIGURE

- 14 An altered perivascular cell in the cerebral cortex, 2 days after irradiation. A perivascular cell (PVC) showing peripheral cytoplasmic extensions (white arrows) and an indented nucleus, is seen to contain a number of dense bodies (DB) in the cytoplasm. The endothelium (EN) of the capillary (C) does not appear to be significantly changed. Note the odd proliferations of the basement membrane (black arrows) into the region of the adjacent astrocytes processes (AP). X 13,500.

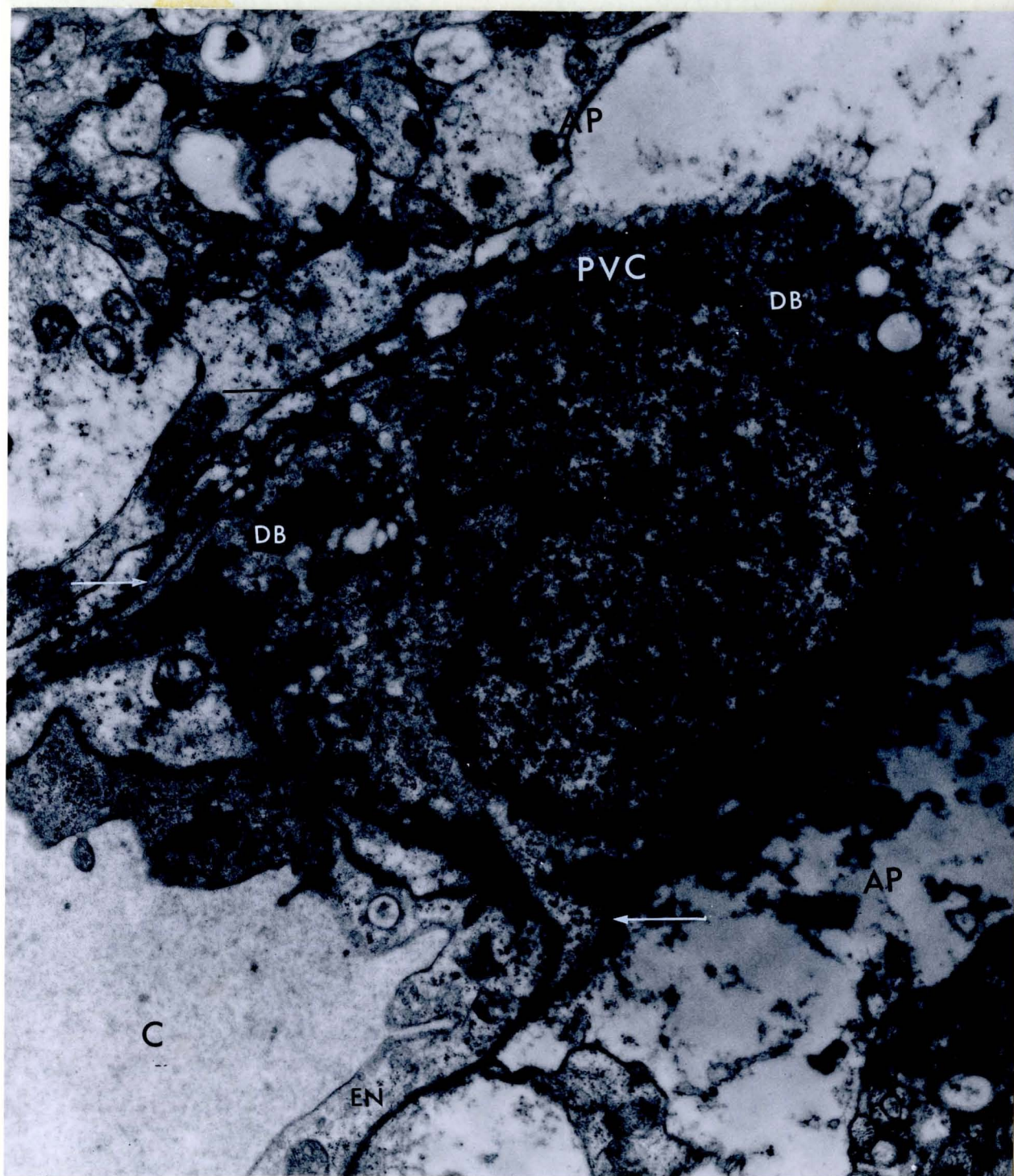


FIGURE 14



## PLATE 15

## EXPLANATION OF FIGURE

- 15 An altered area in the cerebral cortex, 3 days after irradiation. A swollen astrocyte process (SAP) showing discontinuities of the surface membrane (arrows) extends across the field. Granules and indistinct strands of material are prominent in the portion of its cytoplasm in contact with a damaged endothelial cell (EN). Another astrocyte process (PAP) is seen to remain intact, but contains an abundance of vesicles and ill-defined material in its cytoplasm. A neuron (N) contains an irregularly shaped nucleus and swelling is seen in some mitochondria (SM) and vacuoles (SV) within the perikaryon. Note the swollen mitochondrion in the axon (DA) in the lower portion of the field. X 6,900.



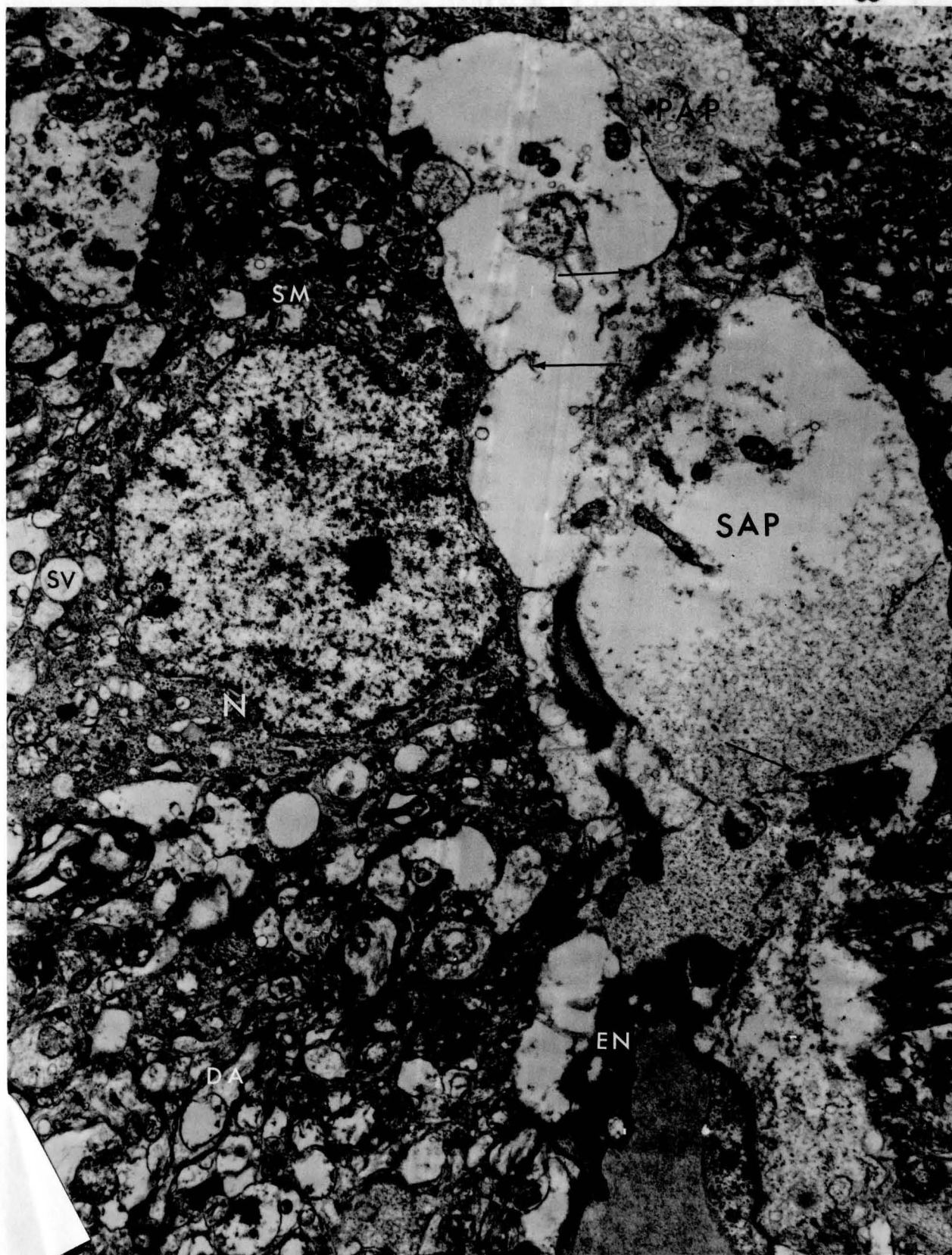


FIGURE 15

## PLATE 16

## EXPLANATION OF FIGURE

- 16 An altered area in the cerebral cortex, 3 days after irradiation. Discontinuities of the surface membrane of astrocytes (RM) are evident in several areas. The nucleus (NU) of an astrocyte (A) in the upper portion of the field contains wide spaces between the clumps of chromatin. Chromatin is lacking in some areas at the rim of the nucleus (black arrows), leaving obscure separations between the nucleoplasm and cytoplasm. The nucleus of a neuron ( $N_1$ ) to the left in the field is irregular in shape, and a number of the mitochondria in the perikaryon are swollen (SM). Swollen mitochondria are also evident in another neuron ( $N_2$ ), and its surface membrane as well as the surface membrane of an oligodendroglial cell (O) seems to be interrupted (white arrows) in the area facing a clear astrocyte process (AP). X 6,900.

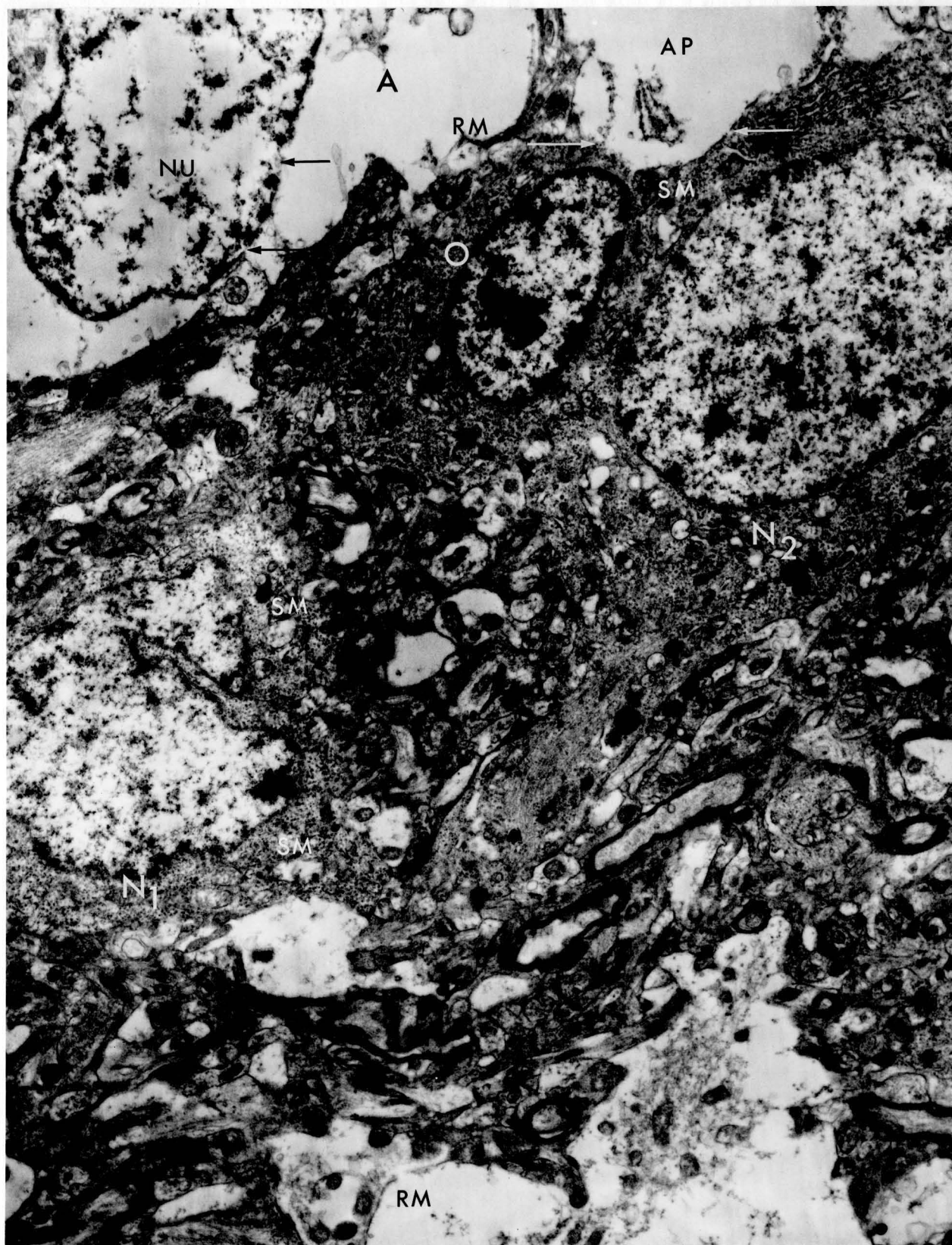


FIGURE 16

## PLATE 17

## EXPLANATION OF FIGURE

- 17 An altered area in the cerebral cortex, 3 days after irradiation. The cell (P) attached to the capillary (C) and projecting into the surrounding tissue, exhibits characteristics similar to those of the altered perivascular cells seen in figure 13 and 14, but is not enclosed in a basement membrane. Phagocytic characters in the form of extensions and invaginations of the peripheral cytoplasm (arrows) are evident. A microglial cell (MI) showing swollen endoplasmic reticulum (SER) and mitochondria (SM) is present above the phagocytic cell. X 11,400.



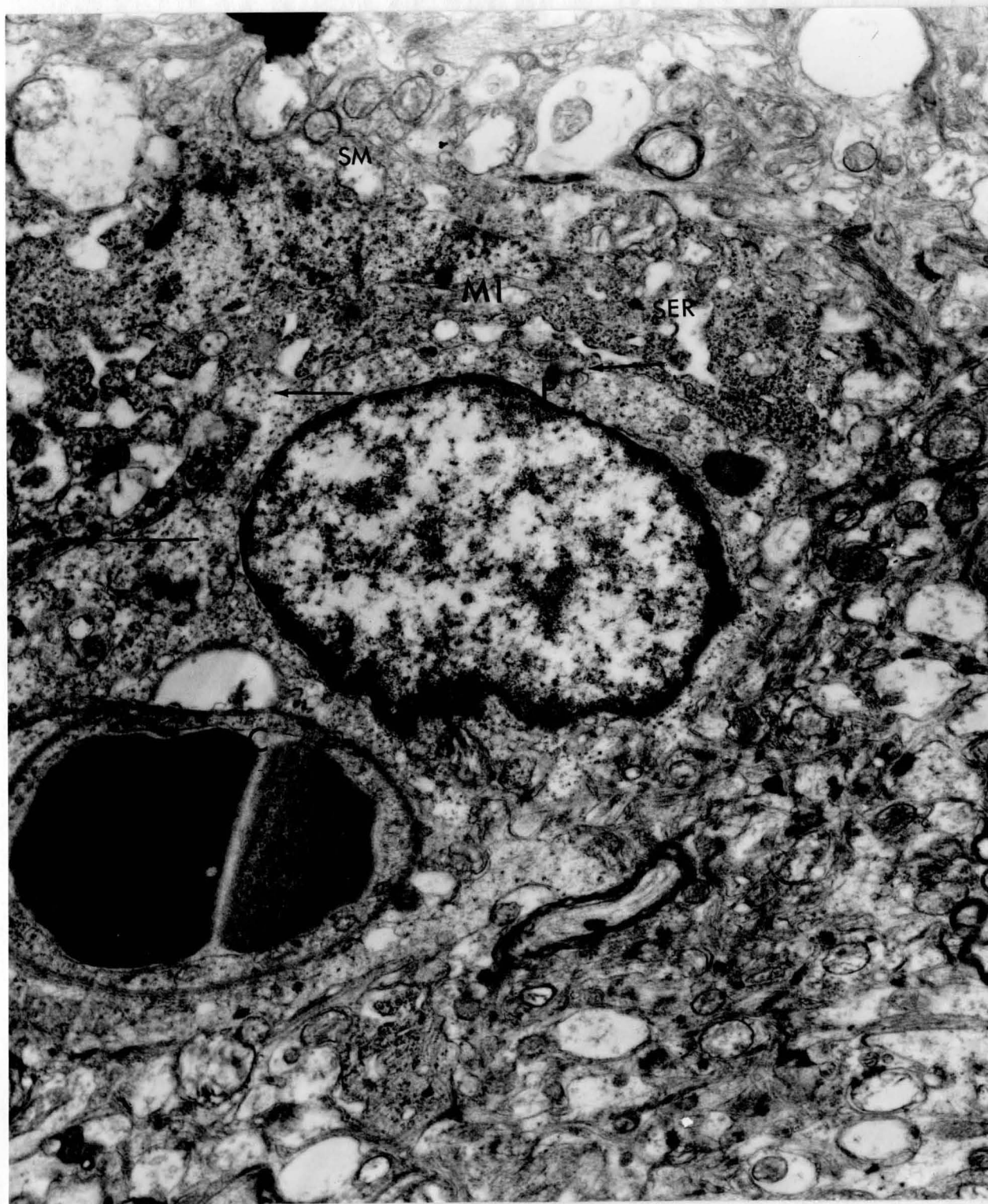


FIGURE 17

## PLATE 18

## EXPLANATION OF FIGURE

- 18 An altered area in the cerebral cortex, 5 days after irradiation. The astrocyte processes (SAP) to right in the field are extraordinarily swollen. Portions of other astrocytes (AP) can be seen at the periphery of a capillary (C) and densely distributed throughout the remainder of the field. They contain formations of differing composition including lipoid masses, granules, vesicles, and ill-defined material. Erythrocytes (E) are also seen within astrocytes. Two phagocytes (P) are present toward the center of the field. X 4,500.

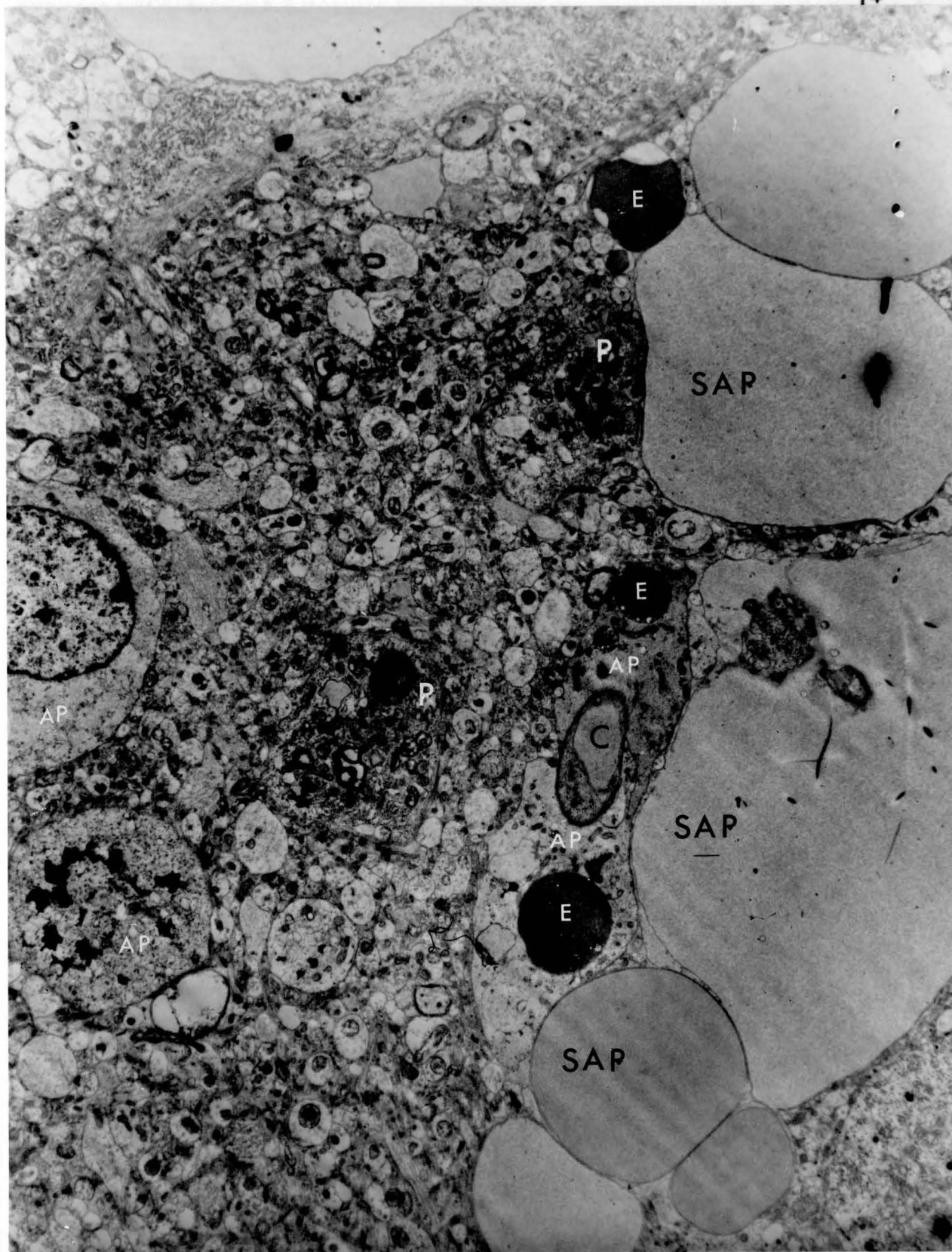


FIGURE 18

## PLATE 19

## EXPLANATION OF FIGURE

- 19 An altered area in the cerebral cortex, 5 days after irradiation. A large space (S) containing cellular debris and a myelin sheath in which the axon is absent (DA) is present in the tissue. A neuron (N) in the upper portion of the field shows an obvious lack of granules in the perikaryon. Phagocytes (P) have invaded the tissue space, and their cytoplasmic extensions are often seen to be in contact with fragments of disrupted cells (arrows). Most of the astrocyte processes (AP) appear to be either severely damaged or contain odd formations in their cytoplasm. X 5,400.



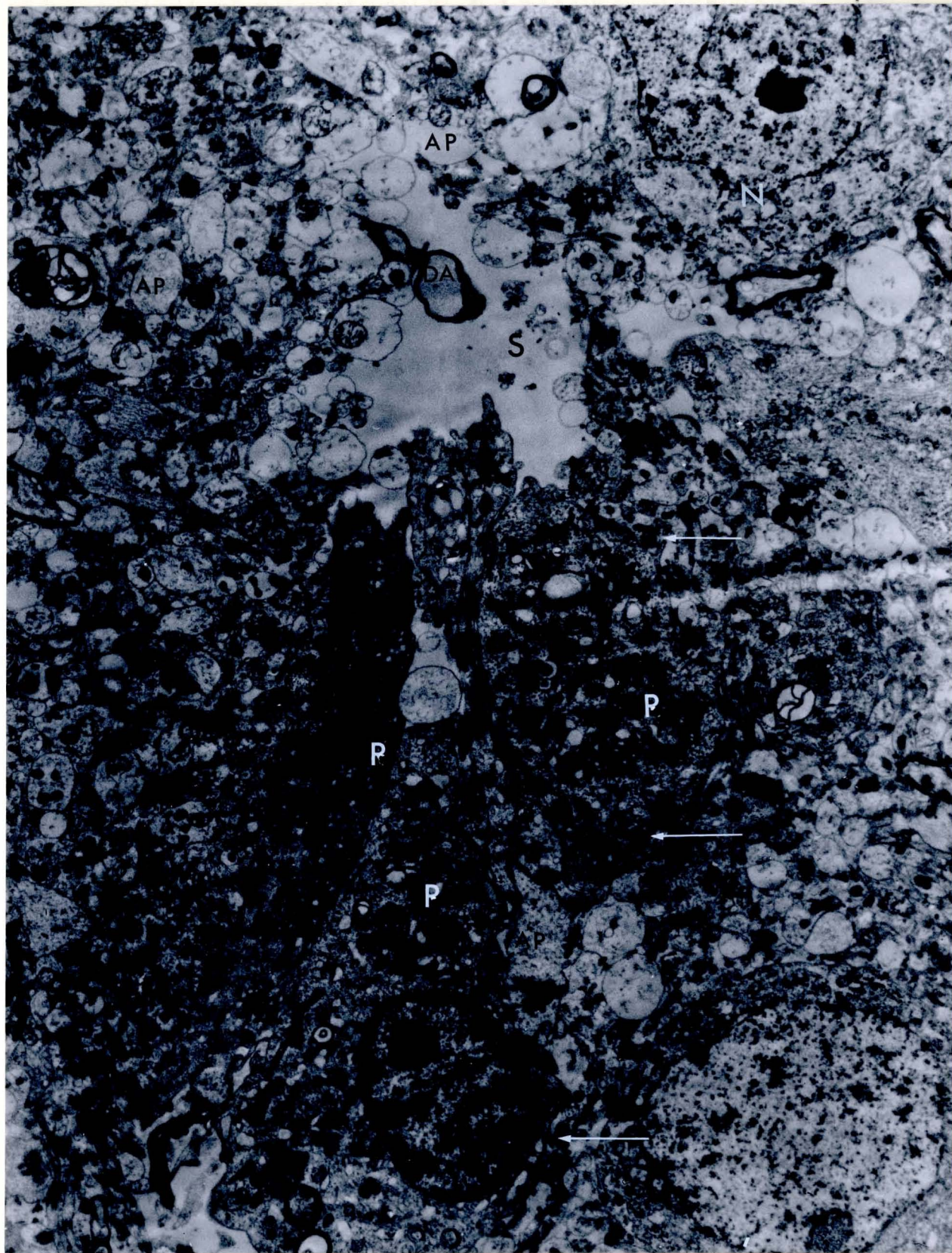


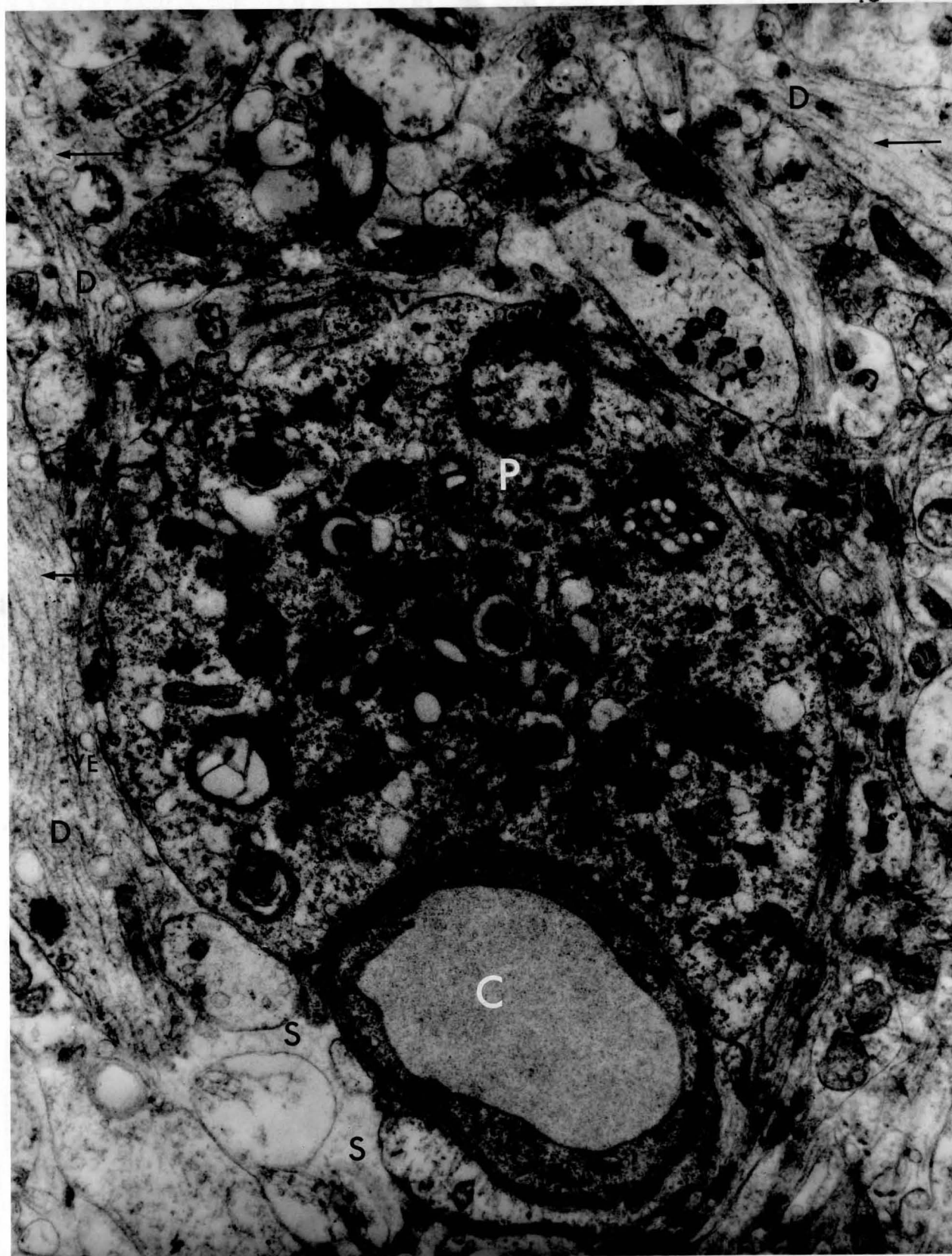
FIGURE 19

## PLATE 20

## EXPLANATION OF FIGURE

- 20 An altered area in the cerebral cortex, 5 days after irradiation. A phagocyte (P) at the periphery of a capillary (C) contains inclusions of a variety of forms. The extracellular space (S) is enlarged at the region to the left of the capillary. Tubules of dendrites (D) appear to be interrupted in some areas (arrows), and an unusually increased amount of vesicles (VE) are present in the cytoplasm. X 13,500.





**FIGURE 20**

## PLATE 21

## EXPLANATION OF FIGURE

- 21 A phagocyte in the cerebral cortex, 5 days after irradiation. Various forms of inclusions (IN) and small vesicles containing phagocytized ferritin (arrows) are present in the cytoplasm of a phagocyte (P). Note the similarity between the basic characteristics of this cell and those of the perivascular cells seen in figures 13 and 14. X 13,000.

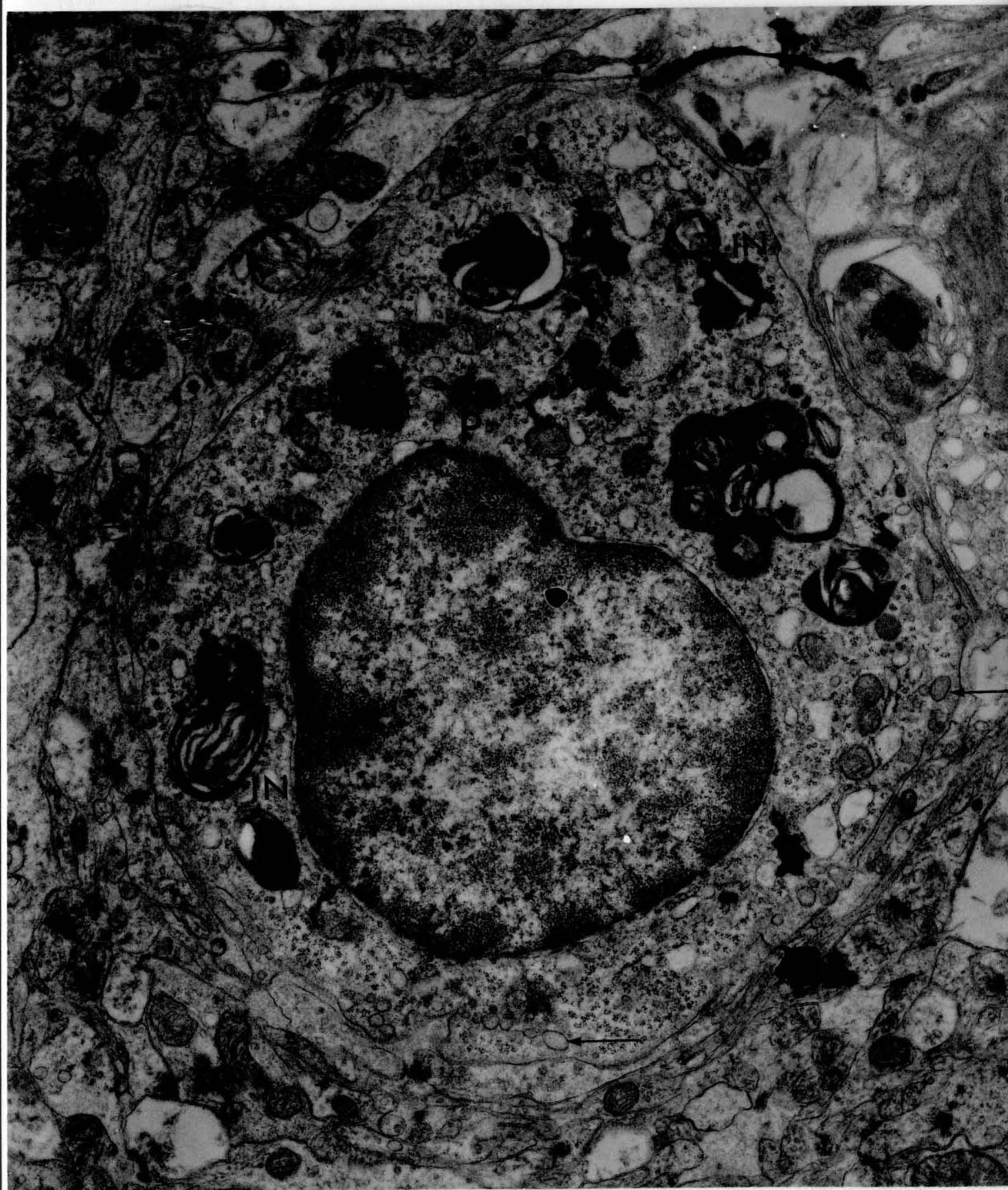


FIGURE 21

## PLATE 22

## EXPLANATION OF FIGURE

- 22 An altered capillary in the cerebral cortex, 5 days after irradiation. The basement membrane (BM) appears hypertrophied, extending as a meshwork into the tissue adjacent to the capillary (C). Indistinct fibrils (arrows) are present in some areas of the basement membrane. A perivascular cell (PVC) shows cytoplasmic extensions (CE).  
X 30,000.



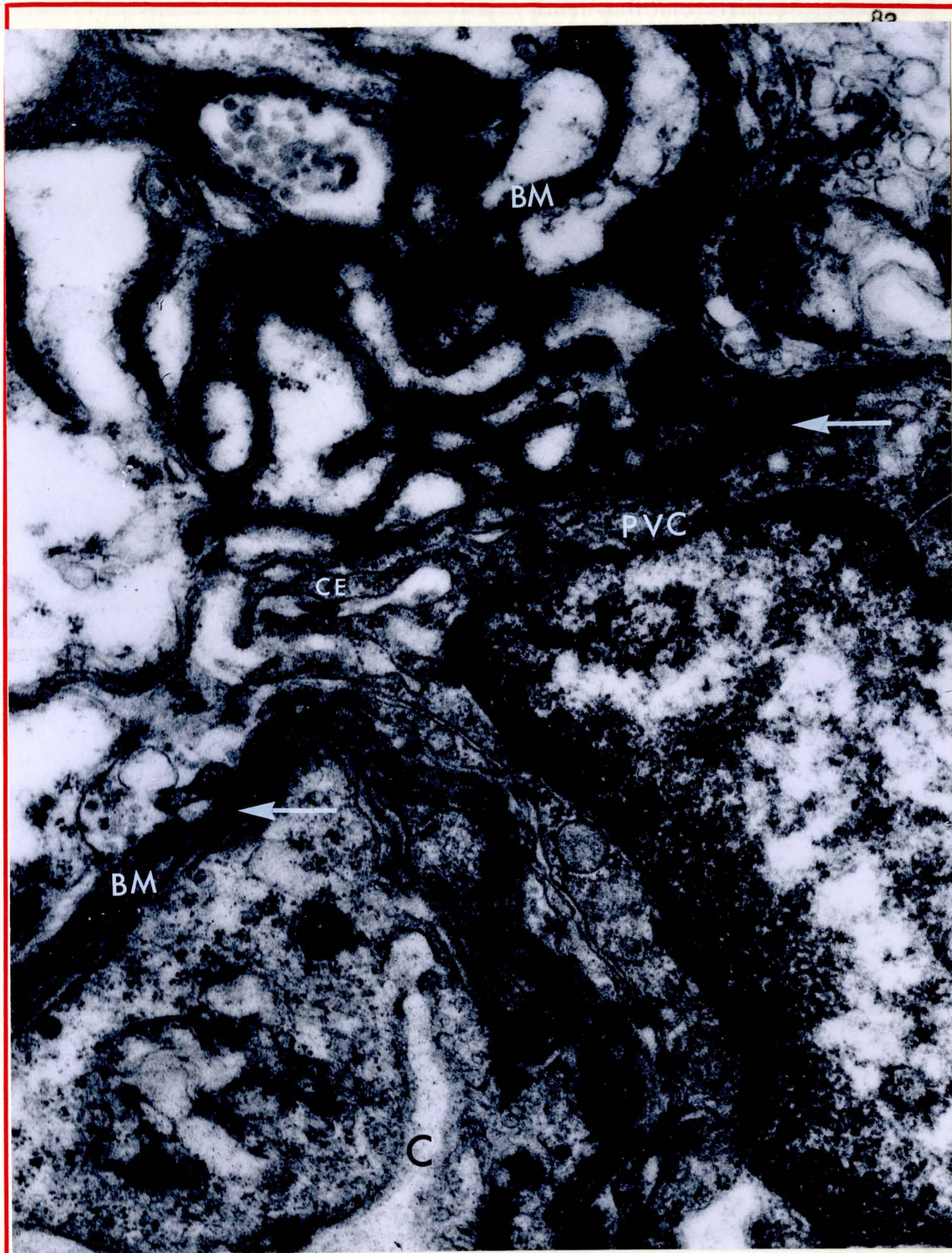


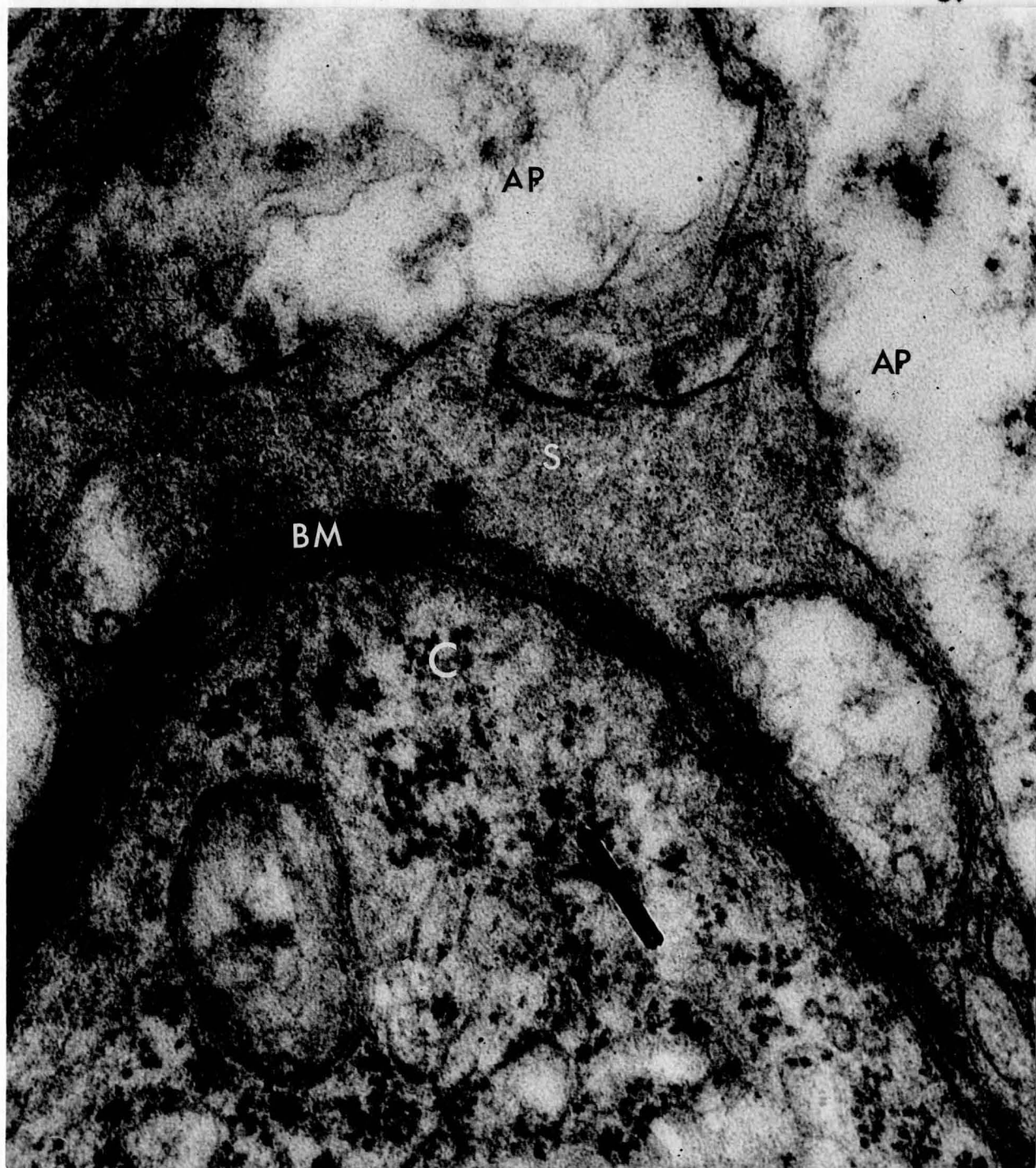
FIGURE 22

## PLATE 23

## EXPLANATION OF FIGURE

- 23 Expanded extracellular space in the region of a capillary in the cerebral cortex, 5 days after irradiation. An enlarged extracellular space (S) containing relatively dense material is seen to separate processes of astrocytes (AP) external to a capillary (C). The intermediate zone of the basement membrane (BM) is easily distinguished. Note the accumulation of ferritin (arrows) in the enlarged space and apparently in a portion of an astrocyte process. X 100,800.





**FIGURE 23**

## PLATE 24

## EXPLANATION OF FIGURE

- 24 The penetration of ferritin into astrocytes and other cells in the cerebral cortex, 5 days after irradiation. Ferritin (arrows) can be seen within the endothelium (EN) of a capillary (C) and in increased amounts in the basement membrane (BM). It is also seen diffusely located in astrocyte processes (AP) and dendrites (D) of the neural tissue. X 55,500.



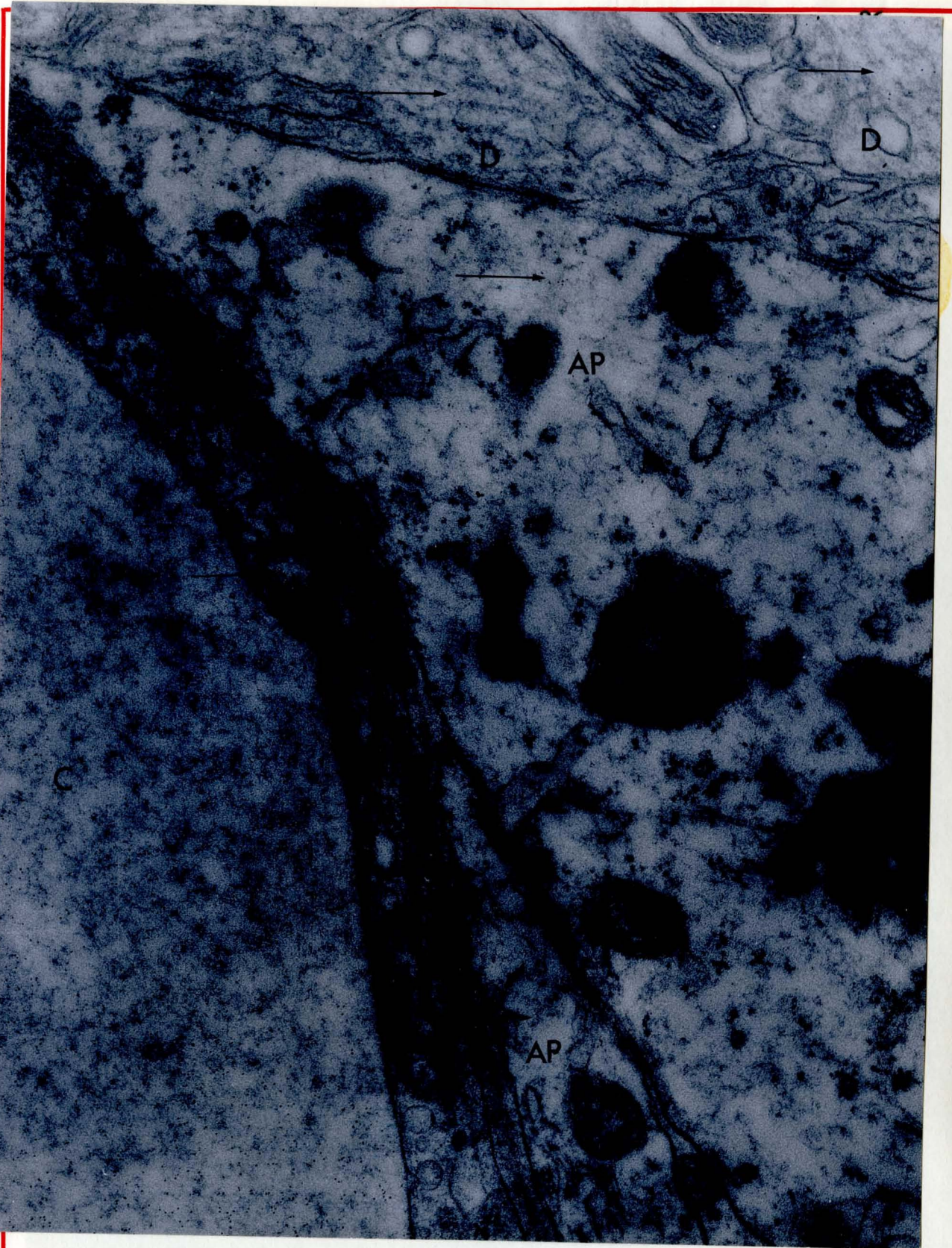


FIGURE 24

## PLATE 25

## EXPLANATION OF FIGURE

- 25 Localization of ferritin in the area of a phagocyte in the cerebral cortex, 5 days after irradiation. Ferritin (arrows) is seen to be engulfed in the cytoplasmic extensions (CE) at the periphery of a phagocyte (P), and is also present within small vesicles (VE) within the cytoplasm of this cell. Ferritin is also apparent within expansions of the extracellular space (S), and within some of the cells of the tissue. X 24,000.



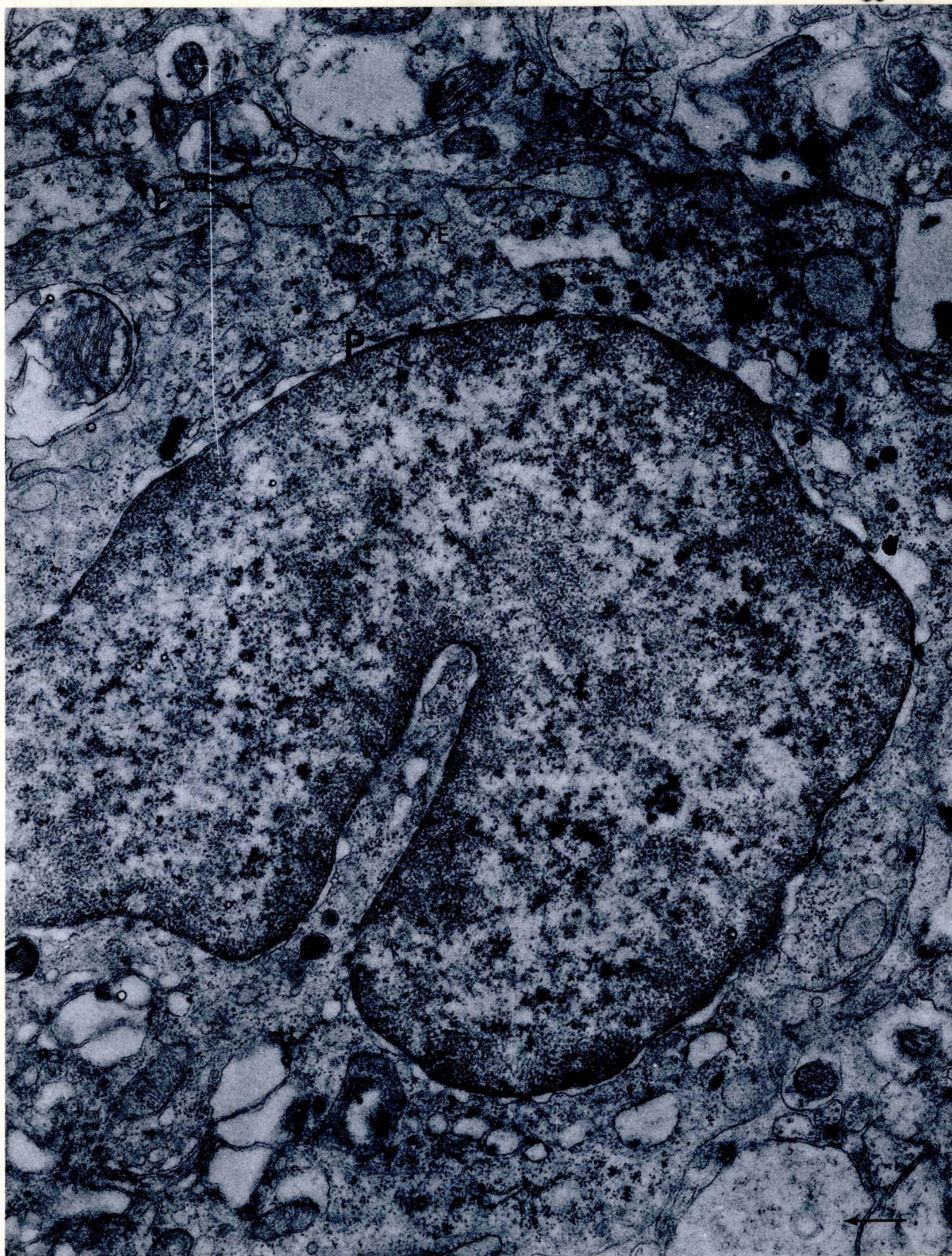

FIGURE 25



## PLATE 26

## EXPLANATION OF FIGURE

- 26 A relatively intact area in tissue of the cerebral cortex, 5 days after irradiation. The cell bodies of two astrocytes (A) and a neuron (N) are present in the lower portion of the field. The nuclei of the astrocytes appear slightly dense as compared to nuclei of astrocytes in control tissue. Their cytoplasm contains a number of additional forms, but the mitochondria seem normal. The astrocyte to the right contains an unusual whorl of membranes in the lower process (arrow). X 6,300.

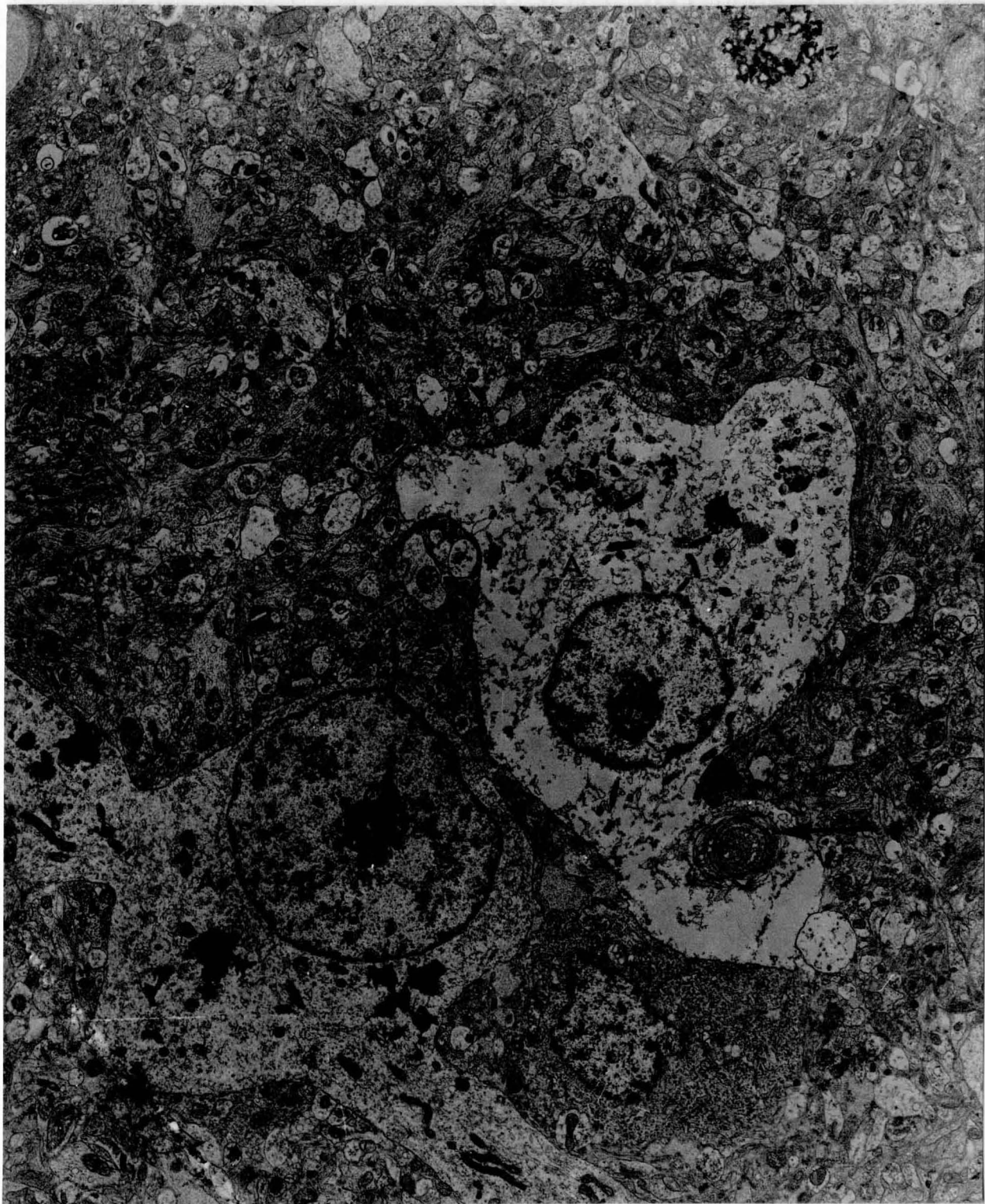

FIGURE 26

## PLATE 27

## EXPLANATION OF FIGURE

- 27 A membranous whorl in the cytoplasm of an astrocyte (A) in the cerebral cortex, 5 days after irradiation. A whorl (W) of lamellated membranes is seen among numerous vesicles (VE), many of which are associated with granules. The elongation (arrows) of a number of the vesicles both within and external to the lamellae, indicates that whorls of this type may be formed by a compression of the cytoplasmic vesicles. Note the ruptured membranes (RM) of several cell processes to the right of a capillary (C). X 39,000.



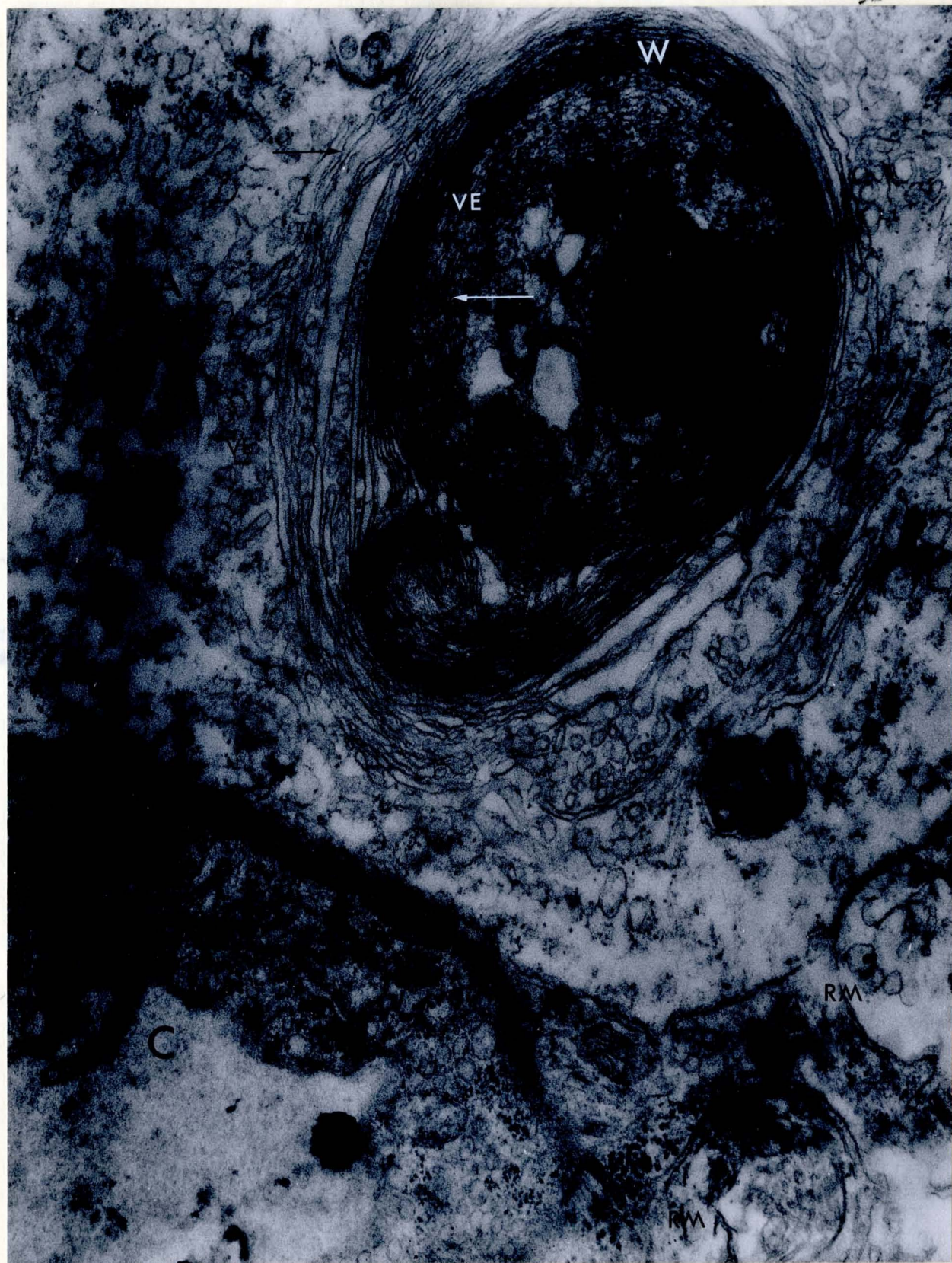


FIGURE 27

## PLATE 28

## EXPLANATION OF FIGURE

- 28 Altered cells in the cerebral cortex, 5 days after irradiation. A cell (O) in the upper portion of the field has characteristics similar to those of an oligodendroglial cell, but contains osmiophilic inclusions (IN) and a number of dense bodies (DB) in the cytoplasm. In the lower portion of the field, a microglial cell (MI) is seen to have a noticeable reduction in the amount of granules in one area of the cytoplasm (arrow). Swollen mitochondria (SM) are also apparent. The identification of the cell (Q) to the right of the microglial cell is questionable, but the basic structure of the cytoplasm resembles that of the cell (O) in the upper portion of the field. X 8,300.



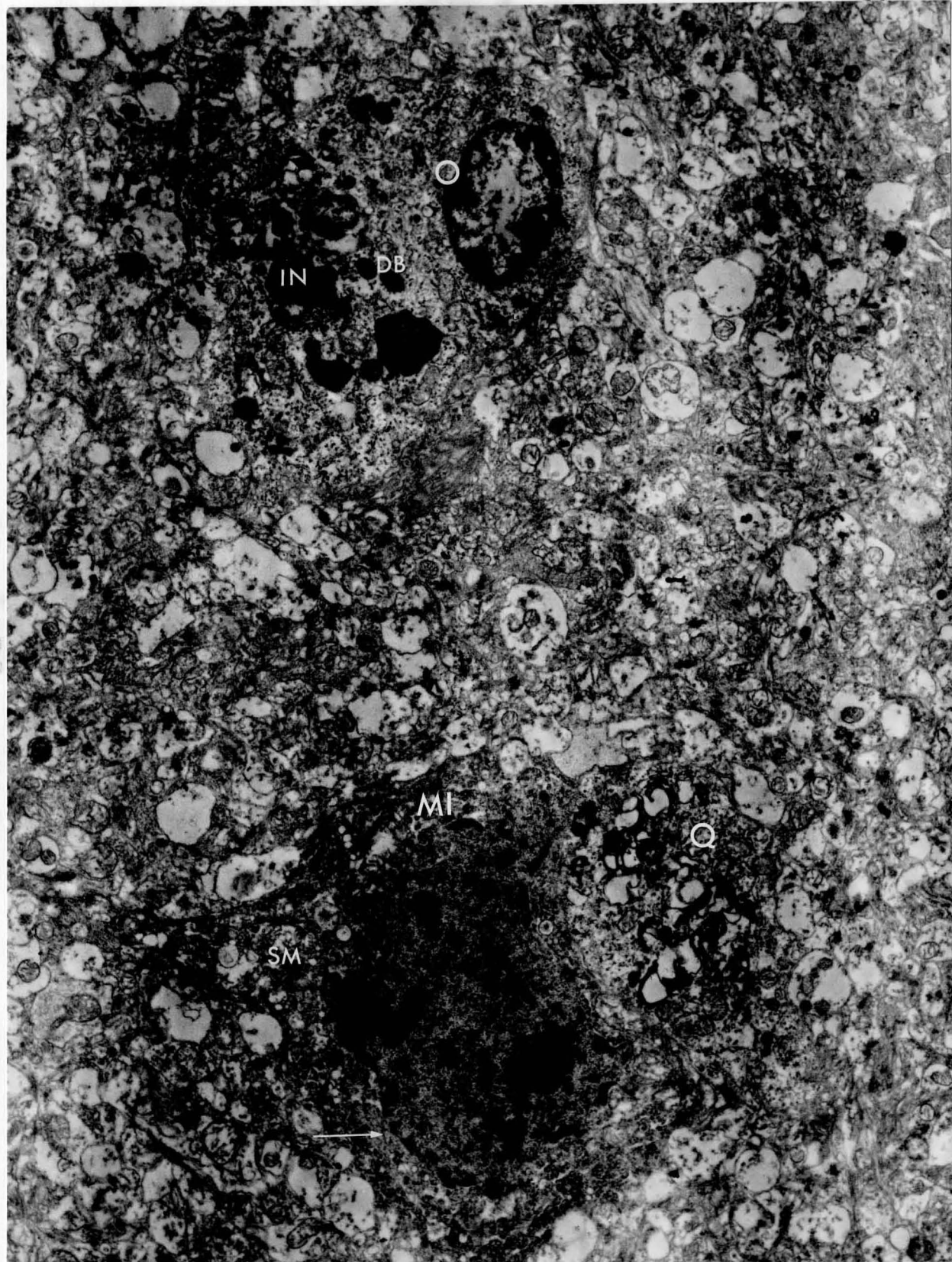


FIGURE 28

## PLATE 29

## EXPLANATION OF FIGURE

- 29 Altered cells in the cerebral cortex, 5 days after irradiation. The cell (O) in the lower portion of the field has characteristics similar to those of an oligodendroglial cell. However, it contains a number of dense bodies (DB), and cytoplasmic extensions (arrows), indicative of phagocytic activity, are seen in several areas at its periphery. A neuron (N) in the upper portion of the field contains swollen mitochondria (SM). X 16,000.

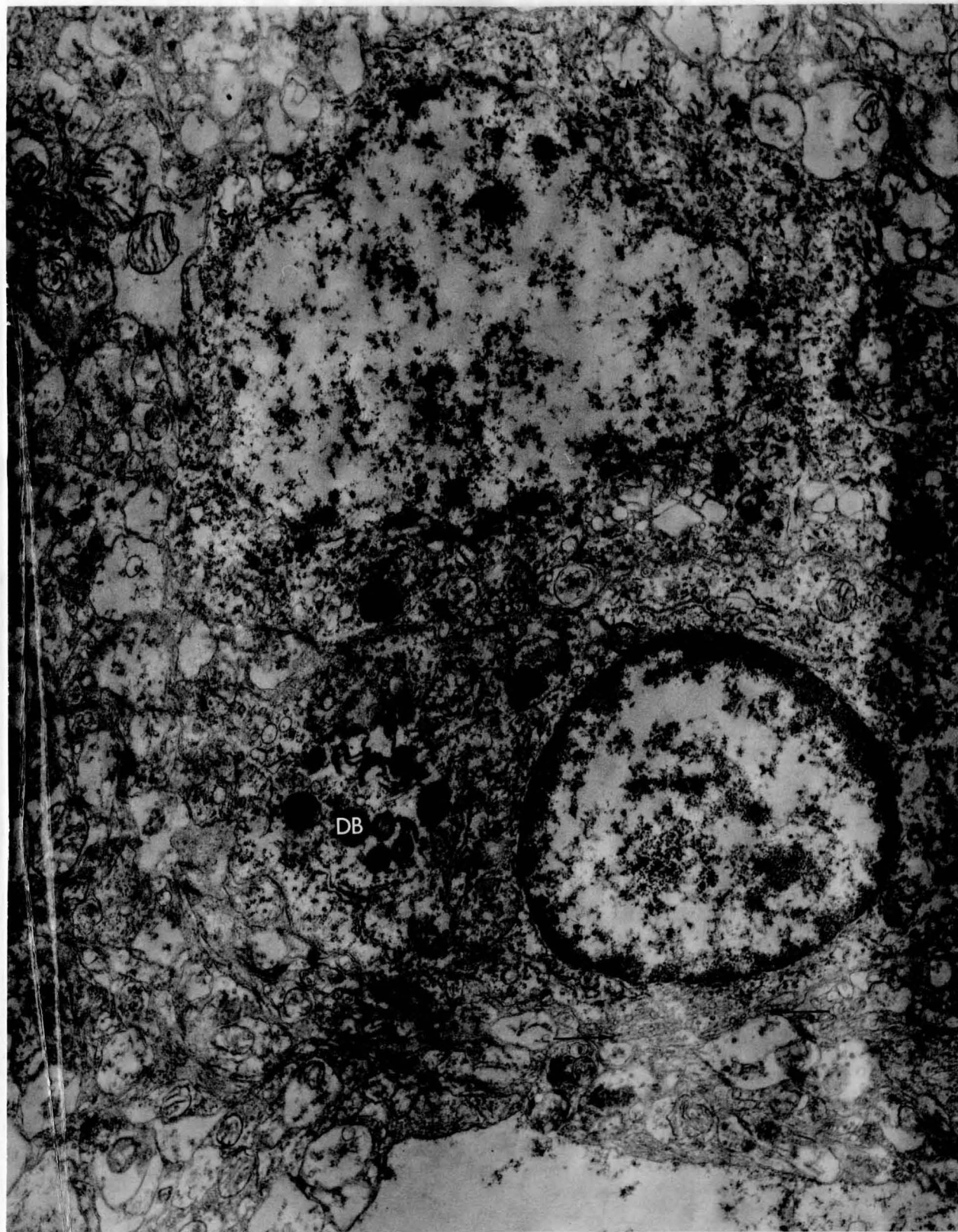

FIGURE 29

## PLATE 30

## EXPLANATION OF FIGURE

- 30 A relatively intact area in the cerebral cortex, 7 days after irradiation. A neuron (N) is seen to contain swollen mitochondria (SM) but the nucleus is similar to those of control tissue. An astrocyte ( $A_1$ ) has a comparatively dense nucleus, and the cytoplasm is filled with vesicles and granules. A cell of a similar nature ( $A_2$ ), although containing large lipoid masses, is present in the upper right portion of the field. Phagocytes (P) are in contact with capillaries (C). Numerous erythrocytes (E) have invaded the tissue. Note the relative compactness of the cells throughout most of the field, and the sudden enlargement of the extracellular space (S) above. X 4,500.



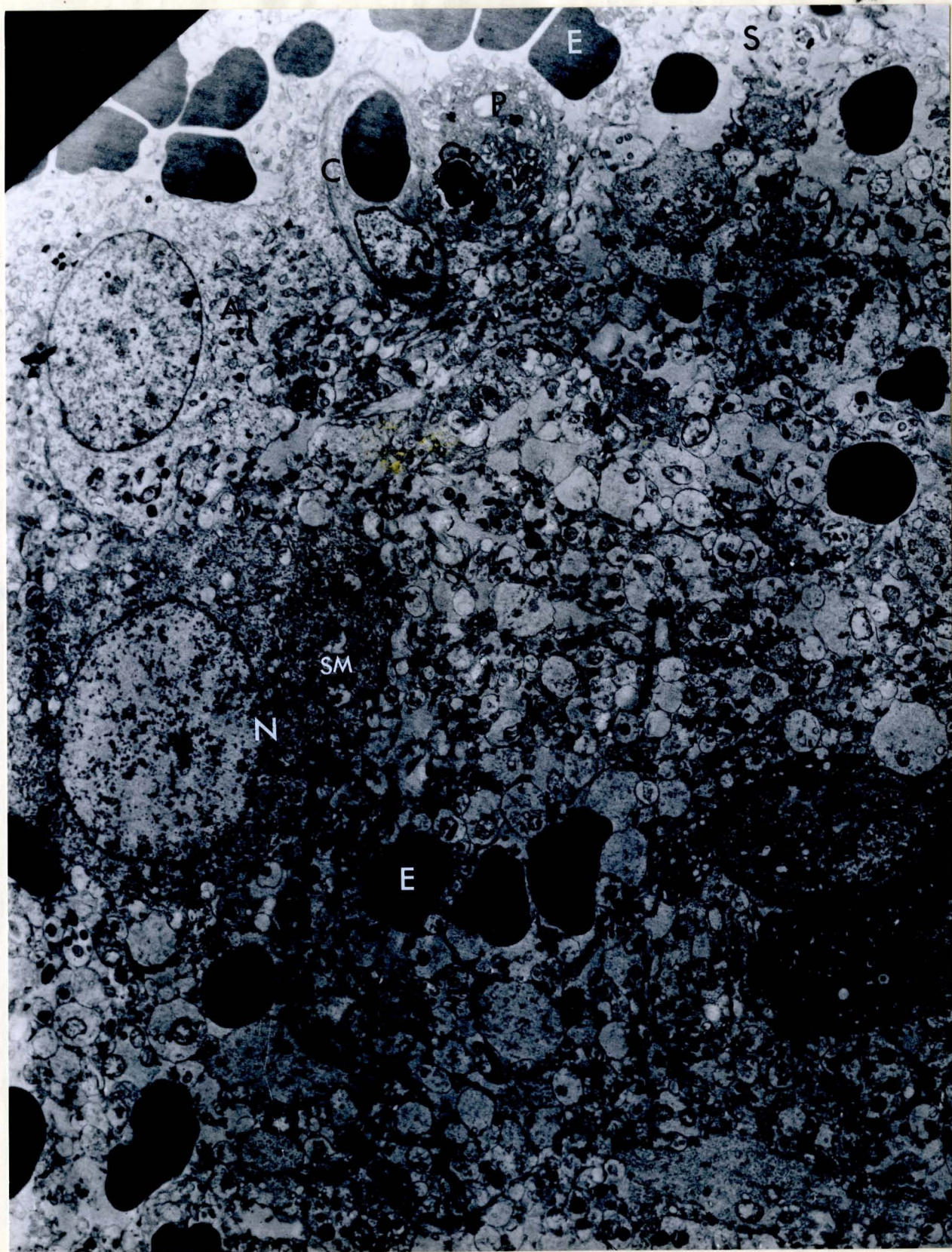


FIGURE 30



## PLATE 31

## EXPLANATION OF FIGURE

- 31 Altered neurons in a severely damaged area in the cerebral cortex, 7 days after irradiation. Of those cells which can be definitely recognized, two neurons (N) are seen to have extremely dense, apparently pyknotic, nuclei (NU). Their mitochondria are swollen (SM), and there is a lack of granules in a portion of the cytoplasm of one cell (arrow). Phagocytes (P) are present in an enlargement of the extracellular space (S) above and below the lower neuron. Note the dendrite (D) continuous with the lower nerve cell body. X 8,000.




FIGURE 31

## PLATE 32

## EXPLANATION OF FIGURE

- 32 A severely damaged microglial cell in the cerebral cortex, 7 days after irradiation. The nucleus (NU) of a microglial cell (MI) is relatively unchanged, but, with the exception of a few areas (arrows), the cytoplasm is deplete of granules. X 10,800.



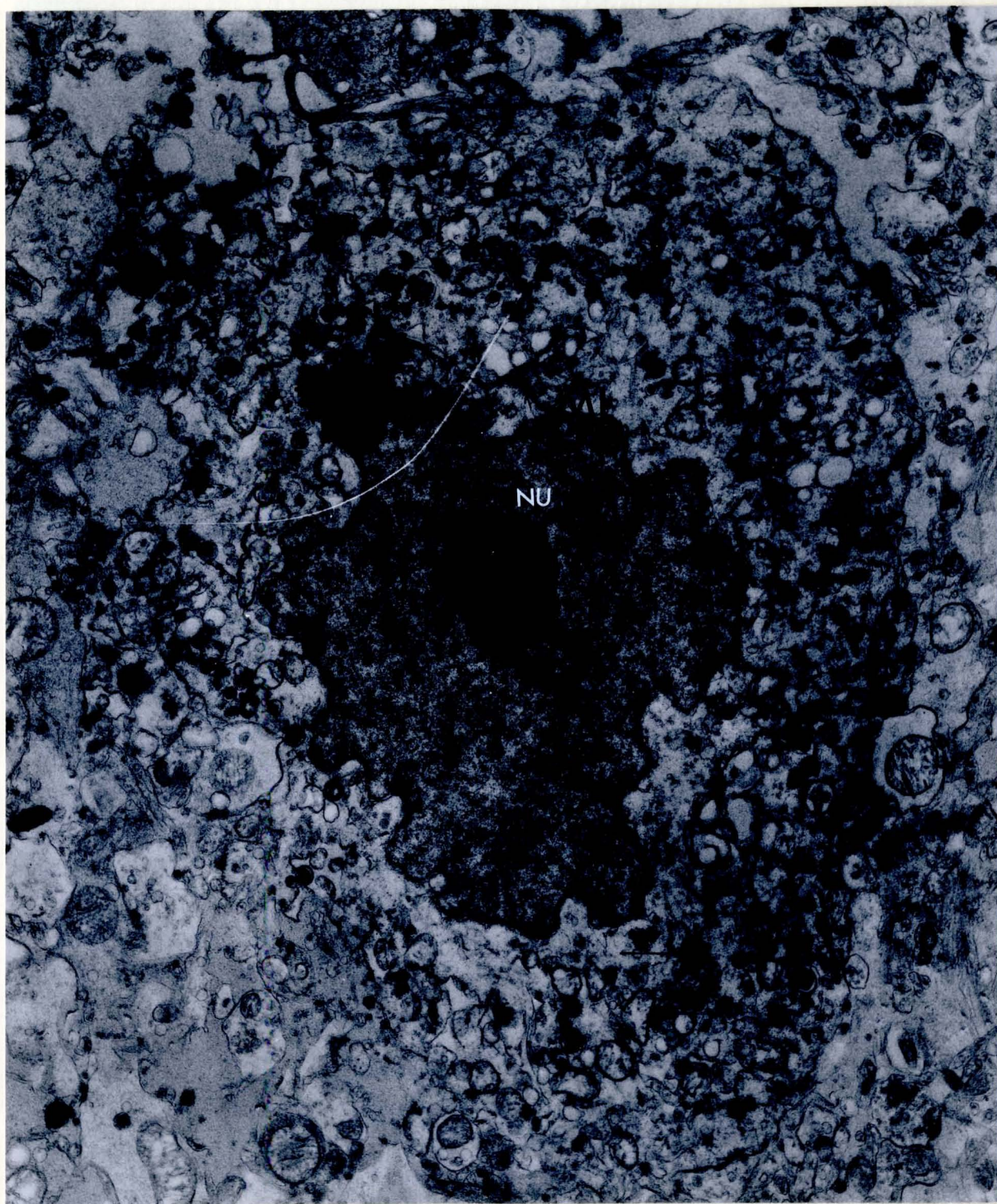


FIGURE 32

## PLATE 33

## EXPLANATION OF FIGURE

- 33 A severely damaged capillary in the cerebral cortex, 8 days after irradiation. The endothelium is missing from the area within the basement membrane (BM). The cells in contact with the basement membrane have swollen mitochondria (SM). A phagocyte (P) is seen in the lower portion of the field.  
X 39,000.



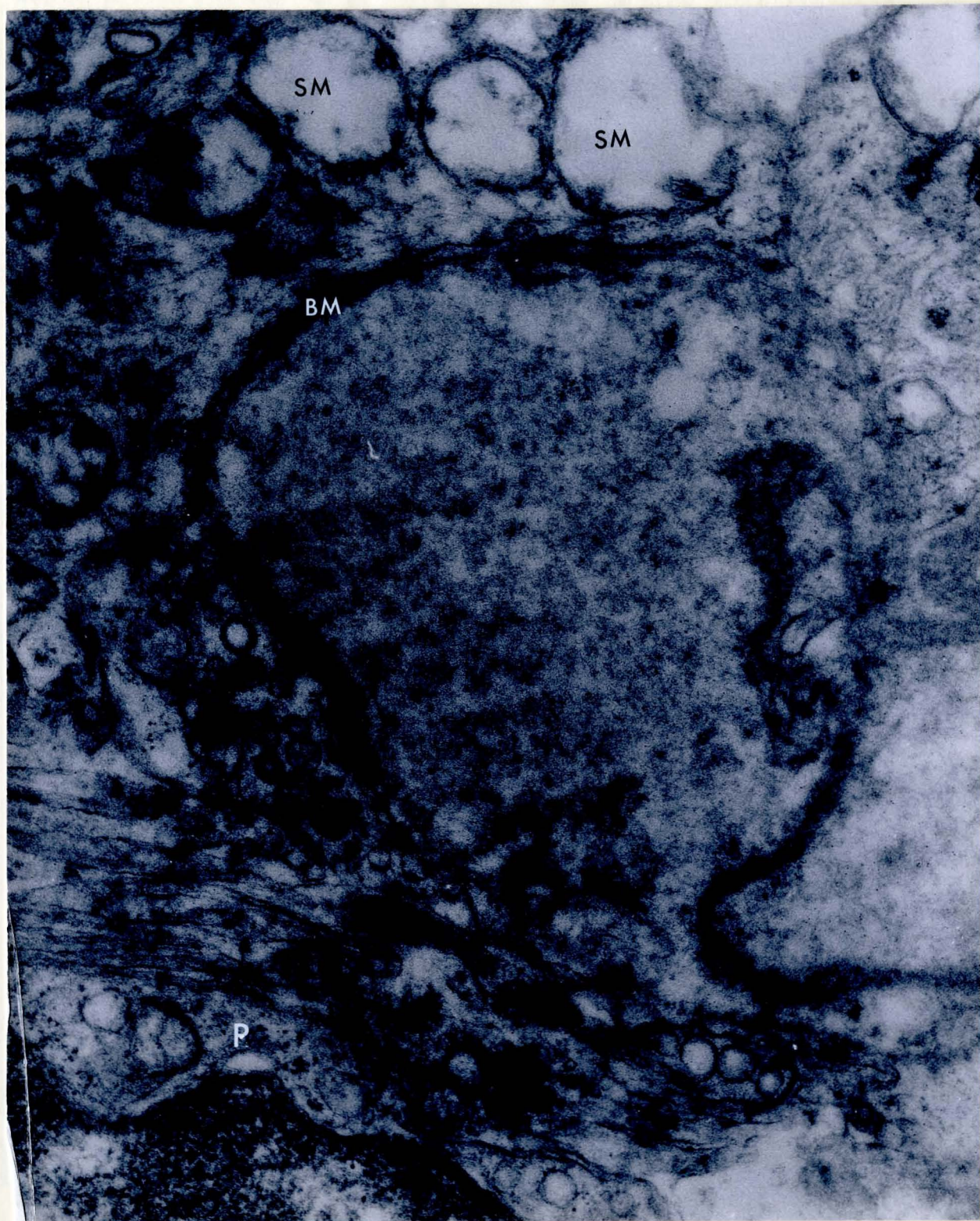


FIGURE 33



## PLATE 34

## EXPLANATION OF FIGURE

- 34 Altered cells in the cerebral cortex, 8 days after irradiation. A perivascular cell (PVC) containing osmiophilic inclusions is seen within the basement membrane (BM). A phagocyte (P) having the same characteristics as the perivascular cell is present in the tissue space in the upper portion of the field. The neuron (N) in the lower portion of the field has maintained much of its normal structure e.g., cytoplasmic granules, intact mitochondria and evenly dispersed chromatin in the nucleus, however, the surface membrane appears to be absent in several areas allowing the cytoplasmic components to slough off into the surrounding tissue space (arrow). X 11,500.

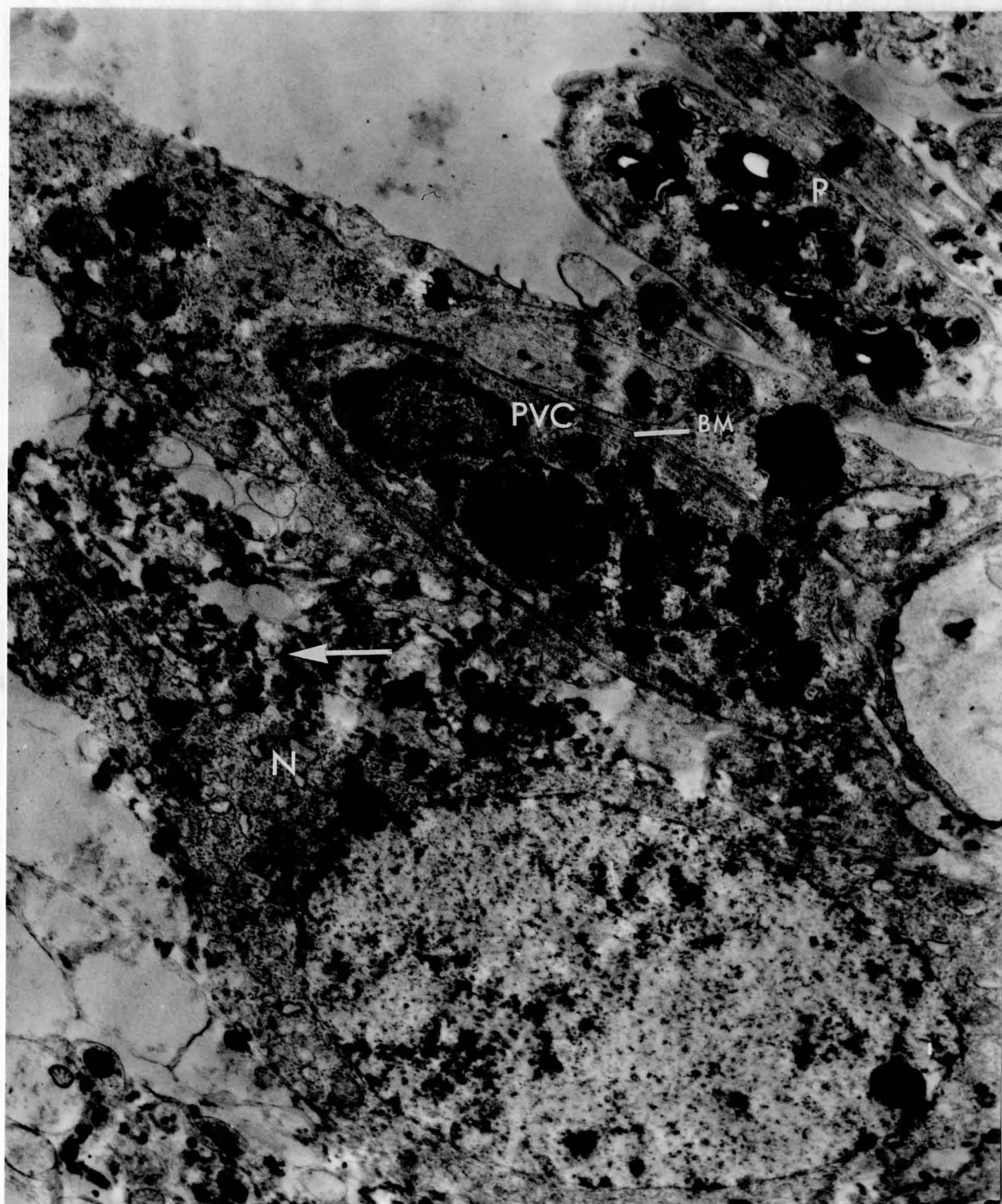


FIGURE 34

## PLATE 35

## EXPLANATION OF FIGURE

- 35 A severely damaged area in the cerebral cortex, 8 days after irradiation. Most of the native cells have disintegrated leaving a large space (S) in the tissue. Remnants of disrupted cells, including broken membranes (RM) are present in the space. The endothelium of a capillary (C), an extravasated erythrocyte (E), and phagocytes (P) represent the limited amount of intact cells remaining in this area. Many of the inclusions (IN) in the phagocytes are of a homogeneous nature, and may contain clear areas in their dense substance. Note the cytoplasmic extensions at the periphery of the phagocytes. X 4,500.

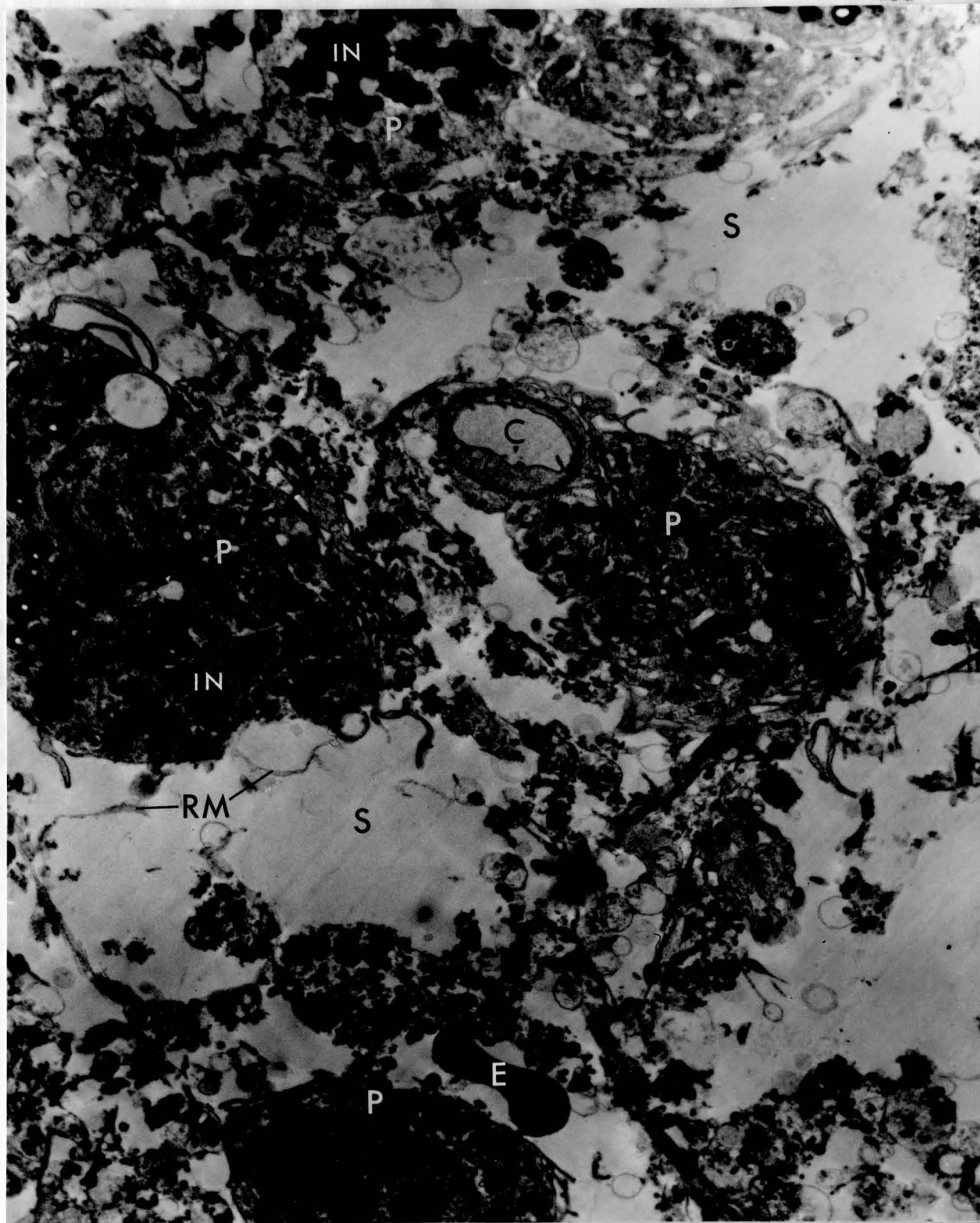


FIGURE 35

## PLATE 36

## EXPLANATION OF FIGURE

- 36 The penetration of ferritin in a normal cerebral capillary of an animal sacrificed one hour after injection. Ferritin (arrows) is present in the lumen (L) of the capillary and in the endothelium (EN) where it occurs as either solitary molecules or a congregate (double arrow). Ferritin can also be seen in the basement membrane (BM). The presence of a ferritin-like particle in the astrocyte process (AP), suggests that the ferritin may gain limited entrance into the tissue beyond the basement membrane under normal conditions. X 78,000.



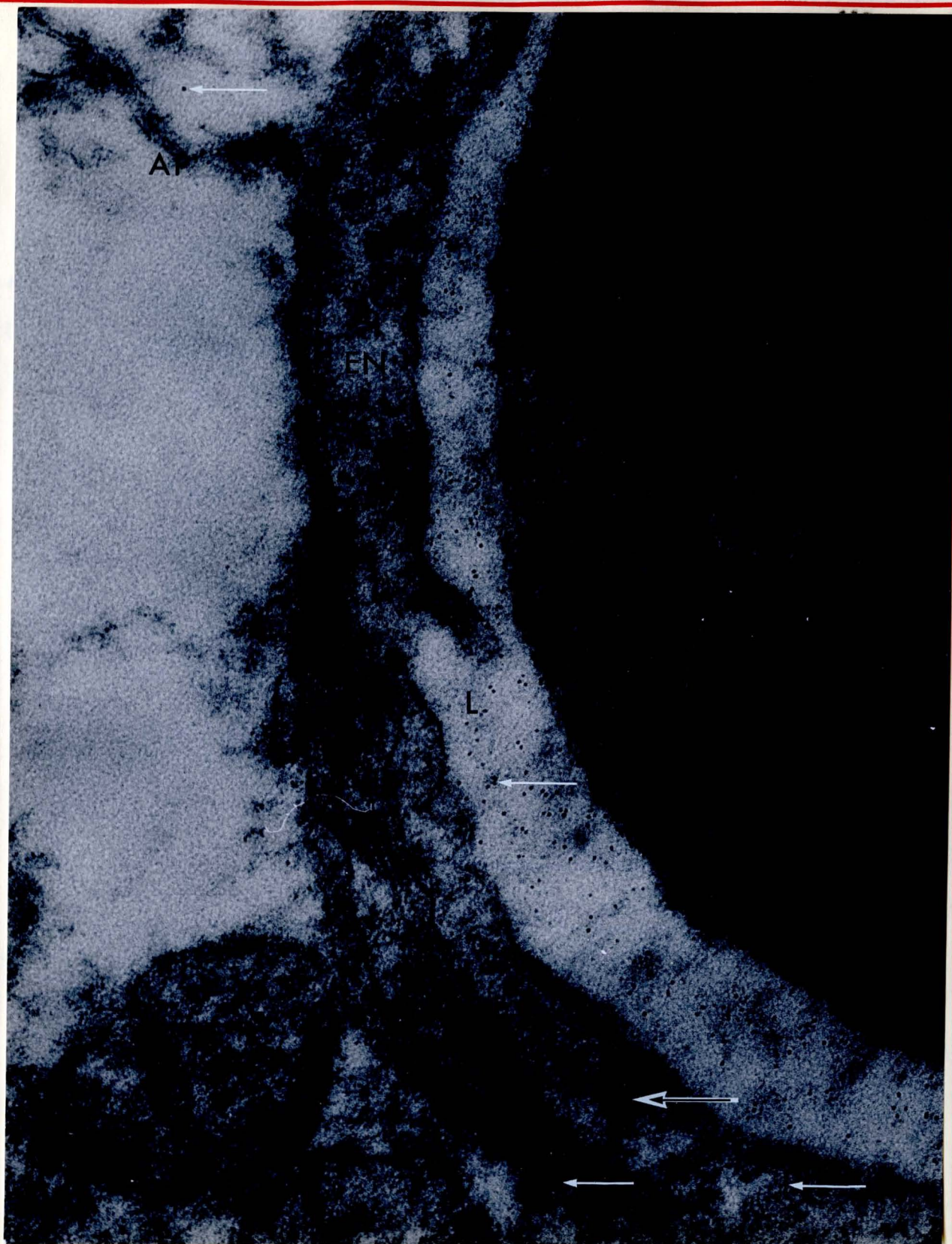


FIGURE 36

APPROVAL SHEET

The dissertation submitted by Thomas Francis McDonald has been read and approved by five members of the Department of Anatomy.

The final copies have been examined by the director of the dissertation and the signature which appears below verifies the fact that any necessary changes have been incorporated, and that the dissertation is now given final approval with reference to content, form, and mechanical accuracy.

The dissertation is therefore accepted in partial fulfillment of the requirements for the Degree of Doctor of Philosophy.

1-16-63

Date

David S. Jones

Signature of Adviser

## ABSTRACT

Male Sprague-Dawley rats weighing 90 to 110 gm were administered 26,000 r of X-irradiation to the middle third of the cranial surface by means of a horizontally collimated beam measuring 1 cm in diameter. Tissues were removed from the cerebral cortex during eight consecutive days following irradiation, and examined with electron microscopy. Intravenously injected ferritin was used as a "vital stain," and its penetration was observed in the area of cerebral capillaries under normal conditions and following irradiation.

Alterations in capillaries and astrocytes are early events. Swollen and partially necrosed capillary endothelial cells are seen, and the basement membrane is thickened, in some instances split, and contains fibrils. Perivascular cells are found to differentiate into phagocytes, and may be responsible for the splitting and formation of fibrils in the basement membrane.

Some astrocytes undergo swelling and disintegration. This apparently represents the major manifestation of edema in the brain, and appears to be the principal source of tissue destruction. Other astrocytes appear to remain viable, but they undergo changes indicative of a progressive reaction.

Changes in the neurons and microglia are later events. They consist of disintegrative alterations, and seem to be secondary to the disruptive changes in astrocytes. Some oligodendroglial cells seem to become phagocytic in the later phases of injury.

Under normal conditions and during the early phases of injury, ferritin

is seen in the endothelial cells and the basement membrane of capillaries, but rarely seen beyond these structures. As enlarged extracellular space occurs in the tissues following the disruption of astrocytes, the ferritin passes into the available space and into a number of the cells of the tissue.