



1956

## The Relation of the Muscle Fiber to the Tendon Fibers at the Muscle-Tendon Junction

Thomas F. McDonald  
*Loyola University Chicago*

Follow this and additional works at: [https://ecommons.luc.edu/luc\\_theses](https://ecommons.luc.edu/luc_theses)

 Part of the [Medicine and Health Sciences Commons](#)

---

### Recommended Citation

McDonald, Thomas F., "The Relation of the Muscle Fiber to the Tendon Fibers at the Muscle-Tendon Junction" (1956). *Master's Theses*. 886.

[https://ecommons.luc.edu/luc\\_theses/886](https://ecommons.luc.edu/luc_theses/886)

This Thesis is brought to you for free and open access by the Theses and Dissertations at Loyola eCommons. It has been accepted for inclusion in Master's Theses by an authorized administrator of Loyola eCommons. For more information, please contact [ecommons@luc.edu](mailto:ecommons@luc.edu).



This work is licensed under a [Creative Commons Attribution-Noncommercial-No Derivative Works 3.0 License](#).  
Copyright © 1956 Thomas F. McDonald

THE RELATION OF THE MUSCLE FIBER TO THE  
TENDON FIBERS AT THE MUSCLE-TENDON  
JUNCTION

by

Thomas Francis McDonald

A Thesis Submitted to the Faculty of the Graduate School  
of Loyola University in Partial Fulfillment of  
the Requirements for the Degree of  
Master of Science

June

1956

LOYOLA UNIVERSITY  
CHICAGO, ILL.

APPROVAL SHEET

The thesis submitted by Thomas F. McDonald has been read and approved by three members of the faculty of the Graduate School.

The final copies have been examined by the director of the thesis and the signature which appears below verifies the fact that any necessary changes have been incorporated, and that the thesis is now given final approval with reference to content, form, and mechanical accuracy.

The thesis is therefore accepted in partial fulfillment of the requirements for the Degree of Master of Science.

June 11, 1956  
Date

Arthur J. Gatz  
Signature of Adviser

### LIFE

Thomas Francis McDonald was born in Chicago, Illinois, June 7, 1927.

He was graduated from Saint Augustine High School, June, 1945, and entered the United States Army in August of the same year. He received the degree of Bachelor of Science in June, 1953, from Spring Hill College, Spring Hill, Alabama.

He was accepted as candidate for the Master of Science degree in the department of Anatomy of Loyola University, Chicago, in September, 1953.

## TABLE OF CONTENTS

	Page
INTRODUCTION . . . . .	1
REVIEW OF THE LITERATURE . . . . .	2
MATERIALS AND METHODS . . . . .	7
OBSERVATIONS . . . . .	11
DISCUSSION AND CONCLUSIONS . . . . .	20
SUMMARY . . . . .	23
BIBLIOGRAPHY . . . . .	26
TABULATION . . . . .	28
PLATES . . . . .	31

## INTRODUCTION

The present study is not of recent origin. The problem of the relation of the muscle fiber to the tendon at the muscle-tendon junction has been studied since the advent of histology. Observations by numerous investigators have led to the following major concepts:

1. Continuity theory--The proponents of this idea maintain that the myofibrillae of the muscle fiber lose their structural character and contractile property at the end of the muscle cell. Their fibers then continue, to their insertion on a skeletal component of the body, as the collagenous fibers in the tendon.
2. Contiguity theory--The proponents of this theory maintain that there is no direct fibrillar continuity between muscle and tendon. Two separate groups have arisen to support this concept. One group maintains that the muscle membrane, the sarcolemma, either is dove-tailed into the tendon at the point of juncture; or that the sarcolemma contains pits, or bodies, in which small fibrous extensions of the tendon are cemented. A second group of observers have presented evidence for the presence of a

third component, the reticular fiber, which serves as the intermediary connection between the muscle and tendon fibers.

The histological observations at the anatomical juncture of skeletal muscle and tendon are still controversial. Consequently this study was undertaken in order to determine the anatomical relationship of the tibialis anterior muscle to its tendon in fetal, neonatal, and mature albino rats.

#### REVIEW OF THE LITERATURE

Schwann (1839) reviewed some of the structural components of the muscle cell which are of importance in this problem. He maintained that the muscle cell was enclosed in a structureless membrane which he considered to form a definite border around the cell. He also stated that the muscle fibers terminated abruptly at the tendon.

Bowman (1840) described "a tubular membranaceous sheath of most exquisite delicacy." He proposed the term sarcolemma for the enclosing sheath or membrane. Bowman believed the sarcolemma isolated the myofibrils from all surrounding structures.

Haggqvist (1931) presented a comprehensive summary on the research accomplished up to that time concerning the binding of muscle to tendon. He reviewed the theories that had come into existence as more was discovered about muscle. Thus, the conti-

guity theory was explained by Weisman (1861) and Ranvier (1875). They postulated that the connection of muscle fibers to tendon was accomplished through the medium of a cement substance. This concept had very likely stemmed from the famed cell theory which considered that cells were held together like bricks by a cement substance.

As early advocates of the continuity theory, Haggqvist cited Fontana (1781), Ehrenberg (1836), Kölliker (1850), Fick (1856), Wagner (1863), Golgi (1880 and 1882), Podwyssozki (1887), Bimer (1892) and others. Haggqvist suggested that many of these might have written without sufficient consideration.

Schultz (1912) published observations favoring the continuity theory. He worked with a number of vertebrates and concluded that he could find no cementing substance separating the muscle fiber from its tendon fibers; but rather, that the myofibrils continued as the tendon fibrils.

In 1913, Baldwin refuted Schultz's paper. He stained sections of a variety of muscles from different animals, and he found that in muscles where the long axis of the muscle fibers coincided with the long axis of the tendon fibers, the sarcolemma of those muscle fibers presented a dove-tailed extension into the tendon. He also showed that in muscle fibers that met the tendon at an angle, the sarcolemma forms a flat surface. In both instances Baldwin stated that the myofibrils attached to the



inside of the sarcolemma, and the tendon fibrils attached to the outside of the sarcolemma.

The work of Schmidt (1927) produced a view which approached a compromise between the opposing concepts. He observed that, though the sarcolemma completely invested the muscle fiber, it was perforated at the tip of the cell, and through the perforations the myofibrils continued into the tendon. Shortly thereafter, Carr (1931) using fetal material as did Schmidt, denied the existence of a sarcolemma at the tip of the muscle fiber. He maintained that, in thinly sectioned muscle (one micron) the myofibrils could be seen passing out into the tendon with no interruption from a sarcolemma.

More recent in developmental studies was the work of Adams, Denny-Brown and Pearson (1953). They agreed with Carr that sometime during development there is a continuity, but stated further that "the formation of a terminal cone is a later event." In the mature muscle they found a distinct boundary between the muscle fiber and its tendon.

The stains employed for the above research differentiated muscle and collagen material primarily. Other stains have been used which showed the existence of additional fibrous material found in the muscle-tendon region, and thereby broadened the possibilities of the manner in which these may be attached.

Haggqvist (1931) cited an early worker, Toldt (1877) who placed

The advent of electron microscopy has also widened the concept of the manner in which the muscle attaches to its tendon.

Jones and Barer (1948) with a magnification of 25,000 times, discovered numerous small spots present on the sarcolemma. They postulated that these spots may have been points of attachment for either connective tissue fibers or myofibrils. In the same year, Reed and Rudall observed fine, uniform, collagen-type fibrils located on the outer surface of the sarcolemma. They also found spots or "corpuscles" on the sarcolemma, but they considered these to exist on the under surface. Again in 1953, Bennett and Porter identified collagen-like fibers closely applied to the outside of the sarcolemmal membrane. They were unable to identify any pits in the sarcolemma, but noticed that the reticular strands of the sarcoplasm were adherent to its inner surface.

Porter (1954) extended the term sarcolemma to include an outer fibrous portion and an inner nonfibrous cuticular portion of the muscle cell periphery. He worked with Amblystoma punctatum larvae and found that the myofibrillae terminated short of the end of the muscle cell in the developing myotomes. He further observed that toward the end of the muscle cell the sarcolemma extended as a number of projections. He defined the outer fibers of the sarcolemma as different from a collagen type, because they showed no clear periodicity. However, he did contend that these fibers originated from the sarcolemma and its projections, and

that they continued from these origins into the tendon.

Bennett (1955) using young zebra fish agreed with Porter. He stated, ". . . the sarcomere banding of the myofibrils stops a micron or so short of the terminal sarcolemma, that tapering strands of fibers of unknown nature traverse this intervening sarcoplasmic space between termination of myofibril and terminal sarcolemma, appearing to be a non contractile continuation of the myofibril, and that tendon fibers appear to insert in the sarcolemma opposite the attachments of the connecting fibrils, forming extensions or extrapolations of them." Bennett also added that the myotendon junction had not yet been adequately studied with the electron microscope.

#### MATERIALS AND METHODS

The tibialis anterior muscle of fetal, neonatal and mature litter-mate albino rats, of the Sprague Dawley strain, were used in this study.

The rats were mated between five and six o'clock in the evening. Then, between eight and ten o'clock of the following morning, vaginal smears were made of the females. The presence of sperm in the smear allowed that day to be considered the date of insemination. The following day therefore was termed the first day after insemination. This method was used to identify fetuses from the date of insemination to birth.

Under ether anesthesia the hind limbs were severed from all animals age twenty days after insemination up to and including the adult. The skin was removed from the limbs except in the younger fetuses. The muscles were fixed intact with the limbs. Younger animals were fixed in their entirety. The fixatives used were Helly's fluid and 10 per cent calcium formalin (40 per cent formalin-10 ml., 1 per cent calcium chloride-10 ml. and distilled water-80 ml.).

After fixation, muscles, older than eighteen days after insemination, were dissected from their bony attachments, but entire limbs had to be taken from the younger animals. These tissues were dehydrated in alcohol, cleared in benzene, and embedded in paraffin under vacuum. The younger limbs were marked with carmine ink for orientation in the paraffin. The muscle-tendon material was sectioned at five microns in thickness, and the sections were mounted in serial order.

The Periodic Acid Leuco-fuchsin and Bielschowsky methods were tested for their staining effectiveness in this problem. The Bielschowsky method\*, which provided tinctorial differentiation of muscle, collagenous, elastic and reticular fibers, was used.

The procedure for the stain employed in this problem is

---

\*H. J. Conn and Mary Darrow, Staining Procedures, Geneva, N. Y., 1943, Part 1B<sub>2</sub>, 20.

as follows:

1. Remove paraffin from sections (1 per cent celloidin was added during this step to coat the slides for the lengthy procedure following).
2. Place five minutes in 0.5 per cent iodine in 95 per cent alcohol (this step was omitted in formalin fixed tissue).
3. Wash in tap water and place for five minutes in 5 per cent sodium thiosulfate.
4. Wash in tap water.
5. Treat sections five minutes in 0.25 per cent aqueous potassium permanganate.
6. Rinse in tap water.
7. Place sections fifteen to twenty minutes in 5 per cent aqueous oxalic acid.
8. Wash thoroughly in tap water.
9. Rinse in distilled water.
10. Leave sections forty-eight hours in 2 per cent silver nitrate in subdued light, but not in the dark.
11. Wash a short time in distilled water.
12. Place in an ammoniacal silver solution (add twenty drops of 40 per cent aqueous sodium hydroxide to 20 ml. of 10 per cent aqueous silver nitrate. Dissolve the formed precipitate by adding 27-28 per cent ammonium water drop by drop while shaking. Leave a few granules of the

precipitate to be sure that there is not an excess of ammonium ions. Add 80 ml. of distilled water and filter). Thirty minutes is sufficient time.

13. Wash quickly in distilled water.
14. Reduce thirty minutes in a 5 per cent neutral formalin solution, changing the solution after the first ten or fifteen minutes.
15. Rinse in tap water.
16. Tone one hour in 1 per cent aqueous gold chloride.
17. Rinse in tap water.
18. Remove excess silver by treating sections two minutes with 5 per cent aqueous sodium thiosulfate.
19. Wash thoroughly for several hours in running tap water.
20. Stain (Harris' alum hematoxylin) ten minutes.
21. Wash in tap water until blue.
22. Counterstain in Van Gieson's solution one to three minutes.
23. Dehydrate in 95 per cent alcohol, followed by absolute alcohol (a pure acetone solution, and an acetone-xylene solution were added here to remove the celloidin). The addition of picric acid to above solutions aids in retention of the muscle stain.
24. Clear in xylene and mount with clarite.

This procedure enabled the differentiation of: collagen-

ous fibrils that stained red to rose, reticular fibers that stained black or brown and muscle fibers that stained yellow.

### OBSERVATIONS

#### Fifteen day fetus:

The sections studied for the fifteen day fetuses were made from the entire hind limb. The differentiation of the muscle was in progress. The myoblasts had become oriented to some degree and constituted rather condensed zones in the more loosely arranged connective tissue cells (mesenchyme and/or reticular cells). The myoblast nuclei were elongate as contrasted to the more spherical connective tissue cell nuclei. The tissues which were fixed in 10 per cent calcium formalin exhibited an argyrophilic meshwork. In some instances fibers were identified, presumably the reticular fibers; in other areas the silver appeared as a scattered granular deposit. No collagenous or elastic fibers were observed between the differentiating myoblasts or in the subcutaneous tissue or dermis.

#### Sixteen day fetus:

These studies were again made on sections of the entire limb. Differentiation of the muscle had progressed. The myoblasts had become more elongate and had assumed an appearance which was comparable to the adult smooth muscle cell. The nuclei had become more compressed than they were on the previous day.

The developing skeletal muscle fibers appeared to be enveloped by an orderly arrangement of parallel argyrophilic fibers. The reticular fibers, while wavy in appearance, extended approximately the length of the muscle. Again the nuclei of connective tissue cells were apparent between the muscle fibers. The collagenous and elastic fibers could not be identified in this stage. The cartilage anlage of the developing tibia had become apparent.

Seventeen day fetus:

Some of the muscle fibers had become multinucleated. The nuclei of these fibers were smaller than those observed on the previous day. The muscle cells had also become somewhat longer. The reticular fibrous mesh which enveloped the muscle fiber had become more pronounced (Fig. 1). The cartilaginous anlage had developed to a greater degree than on day sixteen. The matrix had become much more abundant. The collagenous and elastic fibers had not differentiated. The latter fibers also were not observed in the perichondrial region of the cartilage nor in the dermis of the skin.

Eighteen day fetus:

The muscle fibers had developed to a considerably greater length, and the multinucleate condition was much more prominent. Furthermore, broad myofibrils could now be identified at the periphery of the fibers, although striations were not apparent. The prominent reticular meshwork again enveloped the



muscle fibers.

The site of the tendon was definitely observed in this stage. It consisted of an aggregation of fibroblasts associated with a few collagenous fibers. The muscle fibers terminated in narrow cone-like tips at the point of junction. The termination appeared to be abrupt, and the myofibrils terminated within the muscle cell. The reticular mesh, which enclosed the end of the muscle fiber, appeared to terminate in fine strands between the cells and fibers of the developing tendon. The muscle-tendon junction at this period appeared to be by means of the reticular fibers continuing from the meshwork about the muscle fiber into the tendon.

Nineteen day fetus:

The muscles for this and succeeding days were dissected from the hind limb. The muscle fibers had an appearance similar to that observed on the previous day. They retained non striated, broad, peripheral myofibrils. The reticular meshwork surrounded each muscle (an homology to the endomysium of the adult) and thereby remained the conspicuous feature of these early tissues. There appeared to be numerous small branchings which connected the main broader reticular fibers.

The tendon appeared as in day eighteen, consisting of some collagenous fibers and the accumulation of fibroblast nuclei. The muscle-tendon junction appeared to be through the medium of

the reticular mesh which continued from the muscle fiber into the tendon.

**Twenty day fetus:**

Cross striations were observed for the first time in the muscle fibers of this age. They consisted of the dark and light bands of equal width. The myofibrils had increased in number and decreased in width.

Mitotic figures (Fig. 2) were not uncommon in the early stages of developing muscle cells. The argyrophilic fibers at the periphery of the muscle fibers were also demonstrated. The reticular fiber meshwork which consisted of numerous anastomosing fiber branches, formed a conspicuous sheath about the individual muscle fibers. The point of muscle-tendon junction was similar to that observed on the previous day. The muscle fibers terminated between the fibroblastic nuclei and collagenous fibers of the tendon.

Small caliber collagenous fibers were observed for the first time in association with the reticular meshwork.

**Twenty-one day fetus:**

On the day before birth, the nuclei of the muscle cells were still centrally located as they had been since their development. The dark bands of the cross striations seemed to be slightly diminished in width. The muscle fibers, surrounded by the meshwork of reticulum, seemed to be growing into the spaces

between the collagenous fibers of the tendon. Also numerous fibroblasts and some small collagenous fibers were found in the region of the endomysium.

Some of the sections showed entire muscle fibers that had become loose from their neighboring tissue. The majority of these fibers (Fig. 3) terminated in slender tips, though some of them bifurcated. The sarcoplasmic constituents were completely enclosed within the cell periphery, and the myofibrillae ended just short of the termination. The muscle-tendon junction again appeared to be through the medium of the endomysial fibers, collagenous and reticular as described above.

#### First day post-partum:

Nuclei of the muscle fibers on the first day after birth were both centrally and peripherally located. The Qh band appeared in the heavy cross striations. The reticular fibers about the muscle fibers were extremely large and plentiful. Their continuance between the collagenous fibers of the tendon was very obvious. The meshwork from a single fiber had several tapering extensions into the tendon, but the muscle, in all cases observed, ended in a single elongate tip (Fig. 4).

Also, at this stage the tendon extended vertically up into the aggregate of muscle fibers. The fibers of the muscle no longer remained parallel to the tendon, but the majority joined the tendon at an angle, which gave the muscle a bipinnate form

which was retained in the adult muscle.

Second day post-partum:

The nuclei in the region of muscle fiber termination tended to be centrally located and numerous, while those in the region of the muscle fiber distal to the tendon were more sparse and usually peripherally located. The muscle fibers were larger in size, and the number of collagenous fibers in the tendon was greatly increased.

The muscle-tendon junction showed few apparent changes. The pointed muscle termination, surrounded by a heavy reticulum, was observed at the periphery of the tendon. The reticular mesh extended into the tendon and was observed to occupy the interstices between the collagenous fibers.

Third day post-partum:

The majority of the muscle nuclei were located peripherally with the exception of the muscle cell terminations, in which the nuclei were centrally located and numerous. As many as three nuclei, lined up end to end, could be seen in the tips of some of these muscle fibers (Fig. 5). The reticulum, surrounding the region of the muscle cells distal to the tendon, was decreased in thickness, becoming a finer mesh, but the reticular fibers, extending from the pointed tip of the muscle fiber into the tendon, remained heavy. The endomysium showed an increase in collagenous fibers.

**Fourth day post-partum:**

The primary change from the previous day involved the endomysial structures. The collagenous fibers had become more prominent, and the reticular fibers were less conspicuous.

**Fifth day post-partum:**

The Z bands appeared in the cross striations of this stage. The muscle fiber terminations retained their pointed endings, which contained numerous, centrally located nuclei, and were joined to the tendon by means of heavy reticular fibers continuing from the muscle into the tendon.

**Sixth day post-partum:**

There was no apparent change on this day from the previous day.

**Seventh day post-partum:**

The muscle fibers of the seventh day were similar to those of days five and six. Heavy reticular fibers continued from the muscle into the tendon, as it had occurred previously, but fibroblasts and collagenous fibers were added to the reticulum about the muscle cell tip.

**Eighth day post-partum:**

This stage showed a substantial increase in the size of muscle fibers. The terminations of the muscle fibers approached the heavy collagenous tendon at an angle, extended down adhering to the side of the tendon, and tapered to a point enclosed by

reticular and collagenous fibers.

Tenth day post-partum:

The muscle cells of this stage were similar to those of the previous day. Although collagenous fibers were added to the region of the muscle termination, there was no obvious decline in the reticulum, which was dense about the region of the muscle cell tip. These fibers became much finer at regions more distant from the tendon, but the reticular sheath was maintained throughout the length of the muscle fiber.

Eleventh day post-partum:

There was no apparent change from the previous day.

Twelfth day post-partum:

By the twelfth day after birth the tendon extend far up into the region of the muscle fibers. At the origin it consisted of the collagenous fibers surrounding muscle tips. It increased in width as it extended down through the muscle. The terminal portion of the tendon was narrowed. The muscle fibers angled in toward the tendon and were flattened against the periphery of the tendon (Fig. 6). The pointed muscle termination extended downwards ensheathed in reticular and collagenous fibers. The muscle fibers had enlarged, and the nuclei were primarily peripheral in location.

Thirteenth and fourteenth day post-partum:

Aside from the increase in size due to growth, there was

no apparent change during these days over the previous day.

Fifteenth day post-partum:

The relation of the tendon and muscle fibers are well shown in figure seven. The tendon can be located along the left margin of the field. The muscle fibers, three in number, can be located on the right margin of the figure. The terminations of the upper two muscle fibers can be observed. Each fiber terminates in a conical tip. The striations extend to approximately the extreme tip of the fiber. Fairly large centrally located nuclei can be observed near the termination of the fiber. The muscle fibers appear to be flattened against the tendon. The reticular fibers can be observed to form a reticular sheath about the muscle fibers. The reticular fibers continue into the tendinous matrix and terminate in the cementing substance between the collagenous fibers. Some fine collagenous fibers appear to be intermixed with the argyrophilic reticulum.

Adult muscle-tendon junction:

In the adult muscle fiber the termination was rounded or cone-shaped, according to its position as it joined the tendon, e.g. directly or at an angle. The same general relationships which have been described for the fetal and neonatal rats were apparent. The reticular fibrous sheath which enclosed the muscle had become less apparent, because of the collagenous fiber reinforcement. The collagenous and reticular fiber endomysium was

inserted in the tendinous matrix as observed in the younger stages studied.

## DISCUSSION AND CONCLUSIONS

The fetal and neonatal muscles provided the best material for the study of the relationship of muscle and connective tissue fibers at the muscle-tendon junction.

The earliest observations, on the fifteenth day after insemination, showed an intimate relationship of the myoblasts, which were undergoing differentiation, and the reticular fibers. The latter fibers were observed to form an enveloping meshwork about the primitive muscle cells.

During the next day the differentiation of the muscle fiber had progressed sufficiently so that it was identified by its spindle shape as well as nuclear characteristics. The intimate nature of the reticular fiber endomysium was again apparent. The multinucleated muscle cells of the seventeenth day were ensheathed by broader reticular fibers.

The collagenous fibers were not identified until the eighteenth day in the primitive tendon. The latter consisted of an aggregation of fibroblasts and some scattered fine collagenous fibers which were arranged parallel to the muscle fibers. The tendon occupied a position just distal to the terminals of the muscle fibers. The only anatomical connection between the



primitive tendon and the muscle fibers was through the reticular fibers which bridged the gap.

On the nineteenth day the reticular fibers enclosing the muscle fibers and continuing into the tendon displayed extensive cross branchings which linked the muscle fibers together and strengthened the entire muscle-tendon connection. This formed a unit by combining individual muscle fibers into a bundle, and the action of any individual fiber could be spread over a greater area of tendon.

Collagenous fibers did not appear in the endomysium until twenty days after insemination, but from this time on there was a steady proliferation of these fibers in both endomysium and tendon. With the presence of collagenous fibers in the endomysium the anatomical constituents of the adult muscle-tendon junction was complete, and the changes from this time on were in growth and form.

The majority of muscle fibers from the first day of birth took an oblique position to the tendon, directed downward in true bipinnate form. The reticular fibers retained a harnessing meshwork about the muscle fibers, cross branched throughout the muscular tissue, and continued into the substance of the tendon. The collagenous fibers, although last to appear in development, were more prominent in the adult.

Two neonatal muscle fibers terminating at the muscle-

tendon junction are diagrammatically shown in figure eight. The reticular meshwork which surrounds the skeletal muscle fibers can be likened to a stocking or harness. The coarse reticular fibers continue beyond the conical muscle tips and are embedded between the collagenous fibers. The coarse fibers are connected by the numerous smaller reticular strands which surround the individual muscle cells. In the later fetal, neonatal and adult animals, the collagenous fibers form a reinforcement for the reticular harness. The collagenous fibers of the endomysium are continuous with those observed in the perimysium and epimysium, all of which continue into the tendon.

The effect of muscle contraction and the subsequent effect on the endomysium and the tendon was not observed. However, the following action could be postulated. The contraction of the muscle could cause a shortening and a thickening of the muscle fibers. The bulging of the muscle could in turn exert a pressure or pull on the reticular harness which surrounds each muscle fiber. Since one margin of the harness is fixed in position, the origin, the opposite end or the muscle insertion would effect the pull upon the tendon. The only anatomical connections observed in this area were continuations of the reticular and collagenous fibers into the intercellular substance of the tendon. These fibers, according to their attachment in the tendon, would therefore be responsible for the skeletal movements

which originate in the skeletal muscle cells.

The observations which have been described failed to support the continuity theory. There was no evidence for a continuation of the myofibrils into the tendon, which had been proposed by Schultz (1912), Schmidt (1927), Carr (1931) and others. The study verified the previous observations by Goss (1944) on adult monkeys, and Long (1947) on the soleus muscle of the rat. Our data affords support to the contiguity theory. In our study the reticular fibers formed the major junction in the fetal stages. In the post-partum rats, the reticular stroma was reinforced by a collagenous fiber stroma. The latter formed the major components in the adult rat endomysium, though a reticular meshwork could still be observed surrounding the sarcolemma of the skeletal muscle fibers.

#### SUMMARY

1. Fifteen day fetuses showed differentiating myoblasts and connective tissue cells. Argyrophilic fibers and granules were also present throughout the region of the differentiating myoblasts.
2. Sixteen day fetal muscle cells were similar to the spindle-shaped smooth muscle cells. Wavy reticular fibers were located between the muscle cells.
3. Seventeen day fetal muscle cells were multinucleated and ensheathed by a meshwork of reticular fibers.

4. Eighteen day fetal muscle fibers showed thick peripheral myofibrils. Collagenous fibers of the tendon appeared, and the junction between the muscle and the tendon was by means of an extension of the reticular fiber mesh that surrounded the muscle.
5. In nineteen day fetuses, the reticular fibers exhibited fine cross branchings between the larger fibers, forming a reticular endomysium for the developing muscle.
6. Cross striations appeared in the twenty day fetus muscle fibers. The myofibrils were thinner, but they were more numerous. Also sparse collagenous fibers became apparent in the region of the reticular endomysium.
7. The twenty-one day fetus exhibited an increase of fibroblasts between the muscle cells. There also was an increase in collagenous fibers in both endomysium and tendon.
8. The tibialis anterior muscle of the one day rat exhibited a true bipinnate form. The Qh band also became apparent at this stage.
9. Two and three day old muscle fibers exhibited aggregated nuclei in their terminations. The remaining nuclei became more sparse and peripheral in location.
10. The endomysial structure of the four day old muscle showed an increase in collagenous fibers.
11. The Z band appeared in the cross striations of the five day old muscle fiber.

12. The significant change in the remaining neonatal muscle fibers studied was growth. Likewise, the fibrous tissue increased in amount, especially the collagenous fibers. The fifteen day old muscle-tendon junction was essentially the same as the differentiated prenatal muscle-tendon junction. It differed only in size and the amount of connective tissue which enveloped the muscle fiber termination. The reticular mesh that surrounded the muscle fiber termination extended into the tendon as it had on the eighteenth day after insemination.

13. The adult muscle fibers showed no nuclei in their terminations. An increase of collagenous fibers in the endomysium reinforced the reticular fibers which ensheathed the muscle fiber. Both collagenous and reticular fibers continued into the tendon.

14. The only visible anatomical connection between the muscle and tendon fibers at the muscle-tendon junction in the fetus was by means of the reticular fibers. In the adult rat reticular and some collagenous fibers appeared to bridge the junction.

## BIBLIOGRAPHY

- Adams, R., Denny-Brown, D., and Pearson, C., Disease of Muscle, Paul B Hoeber, Inc., New York, 1953.
- Baldwin, W. M., 1913, The relation of muscle fibrillae to tendon fibrillae in voluntary striped muscle of vertebrates, *Morph. Jahrb.*, 44: 249-266.
- Barer, Robert, 1948, The structure of the striated muscle fibre, *Biol. Rev.*, 23: 159-200.
- Bennett, H. Stanley, 1955, Modern concepts of structure of striated muscle, *Am. J. Phys. Med.*, 34: 46-51.
- Bennett, H. Stanley, and Porter, Keith R., 1953, On electron microscope study of sectioned breast muscle of the domestic fowl, *Am. J. Anat.*, 93: 61-105.
- Bowman, W., 1840, On the minute structure and movements of voluntary muscle, *Phil. Trans. Royal Soc.*, 130, Part 2: 457-501.
- Carr, Ralph W., 1931, Muscle-tendon attachment in the striated muscle of the fetal pig; demonstration of the sarcolemma by electric stimulation, *Am. J. Anat.*, 49: 1-42.
- Conn, H. J., and Darrow Mary, Staining Procedures, Geneva, N. Y., 1943, Part 1B<sub>2</sub>, 20.
- Goss, C. M., 1944, The attachment of skeletal muscle fibers, *Am. J. Anat.*, 74: 259-289.
- Haggqvist, G., 1931, Gewebe und System der Muskulatur, Möllendorff Handb. mikr. Anat. Menschen, 2: 223-233.
- Jones, W. M., and Barer, Robert, 1948, Electron microscopy of the sarcolemma, *Nature*, 161: 1012.
- Long, Margaret E., 1947, The development of the muscle-tendon attachment in rats, *Am. J. Anat.*, 81: 159-187.

- Porter, K. R., 1954, The myo-tendon junction in larval forms of Amblystoma punctatum, Anat. Rec., 118: 342.
- Ranvier, L., Traite Technique D'histologie, Paris, 1875, Cited from Haggqvist: 224.
- Reed, R., and Rudall, K. M., 1948, Electron microscope studies of muscle structure, Bichim. Biophys. Acta, 2: 19-26.
- Schmidt, V., 1927, Die Histogenese der quergestreiften Muskelfaser und des Muskelsehnenüberganges, Zeitschr. mikr. Anat. Forsch., 8: 97-184.
- Schultz, O., 1912, Über den direkten Zusammengang von Muskelfibrillen und Sehnenfibrillen, Arch. mikr. Anat., 79: 307-331.
- Schwann, Th., 1839, Microscopical Researches into the Accordance in the Structure and Growth of Animals and Plants, London, 1847.
- Toldt, C., Lehrbuch der Gewebelehre, Stuttgart, 1877, Cited from Haggqvist: 227.
- Weisman, A., 1861, Über das Wachsen der quergestreiften Muskeln nach Beobachtungen am Frosch, Z. rat. Med. 3 Reihe 10, 263-284, Cited from Haggqvist: 224.

### Tabulation of the Development of the Muscle-tendon Junction

Age	Specimens	Structure of tibialis anter muscle	Structure of the endomysium	Structure of the tendon
<u>Fetal</u>				
15 day	8	Differentiating myoblasts. Single elongate nuclei.	Small reticular fibers surround the myoblasts.	Absent.
16 day	8	Myoblasts assume spindle similar to smooth muscle cell.	Reticular fibers located parallel to myoblasts.	Absent.
17 day	7	Lengthening muscle fiber multinucleated. Nuclei centrally located.	Forms heavy reticular mesh about muscle fiber.	Absent.
18 day	7	Thick and peripherally located myofibrils apparent. Nuclei centrally located.	Similar to previous day.	Few fibers appeared in connective tissue primordia at termination of muscle fibers.
19 day	8	Muscle fibers terminated in conical tips; do not extend into tendon.	Cross branchings of reticular fibers apparent.	Definitive tendon more prominent because of increased collagenous fibers.
20 day	7	Cross striations appear. Myofibrils increased in number and decreased in diameter. Mitotic figures common.	Numerous anastomotic fibers ensheath muscle continue into the tendon. Collagenous fibers appear.	Similar to previous day



Tabulation continued;

21 day	7	Muscle fibers seen to taper at terminations.	Reticular fibers dense. Increase in collagenous fibers. Continues into tendon.	Collagenous fibers increased in diameter and number.
<u>Post-partum</u>				
1 day	7	Nuclei distal to tendon are peripherally located. Qh bands appear.	Increase in collagenous fibers. Reticular fibers dense. Continues into tendon.	Tendon extends into muscle to form bipinnate arrangement.
2 day	10	Numerous nuclei toward termination. Other nuclei peripherally located.	Similar to previous day.	Reticular fibers occupy interstitial areas.
3 day	7	"	"	"
4 day	10	Z bands appear	"	"
5 day	9	Shows normal growth. 1 to 4 nuclei may appear at terminations of muscle fibers.	Steady increase in reticular and collagenous fibrous material. Both types of fibers continue into the tendon	Shows steady increase in collagenous fibers.
6 day	9			
7 day	4	Developmental between 6 to 15 day post-partum is similar to that described for fifth day.		
8 day	8			
9 day	7			

## Tabulation continued;

10 day 5

11 day 6

12 day 8

13 day 7

14 day 7

15 day 7

Adult	1	Nuclei absent in muscle fiber tips, others are peripheral	Reticular mesh about muscle fiber. Reinforced by collagenous fibers. Continues into tendon.	Dense collagenous fibers. Includes reticular fibers.
-------	---	---	---	--

## PLATE I

## Figure 1

Reticular fibrous mesh surrounding muscle fibers in the  
seventeen day fetus. Fixation, 10 per cent calcium formalin;  
stain, Bielschowsky method. x2000.

M--muscle fiber

R--reticulum

F--fibroblasts

## PLATE I



—F

—M

—R



## PLATE II

## Figure 2

Mitotic figure in muscle tip in twenty day fetus.

Fixation, Helly's fluid; stain, Bielschowsky method. x2000.

Mf-mitotic figure

R--reticular fiber

## PLATE II



Figure 2

## PLATE III

## Figure 3

Muscle fiber termination in the twenty-one day fetus.  
Fixation, Helly's fluid; stain, Bielschowsky method. x2000.

T--muscle fiber tip

## PLATE III

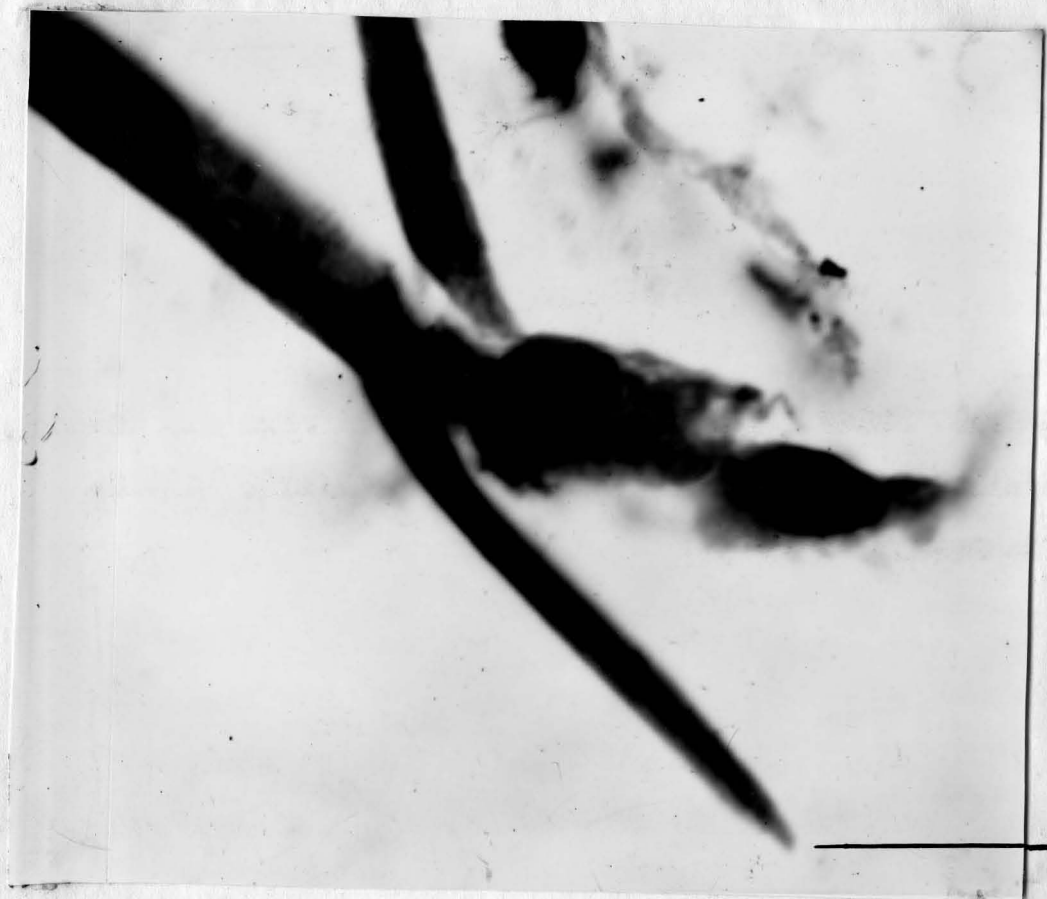

Figure 3



## PLATE IV

## Figure 4

Heavy reticular fibers surrounding muscle termination and continuing into tendon in a one day old animal. Fixation, 10 per cent calcium formalin; stain, Bielschowsky method. x1000.

M--muscle fiber at tip

R--reticular fiber

T--tendon

## PLATE IV

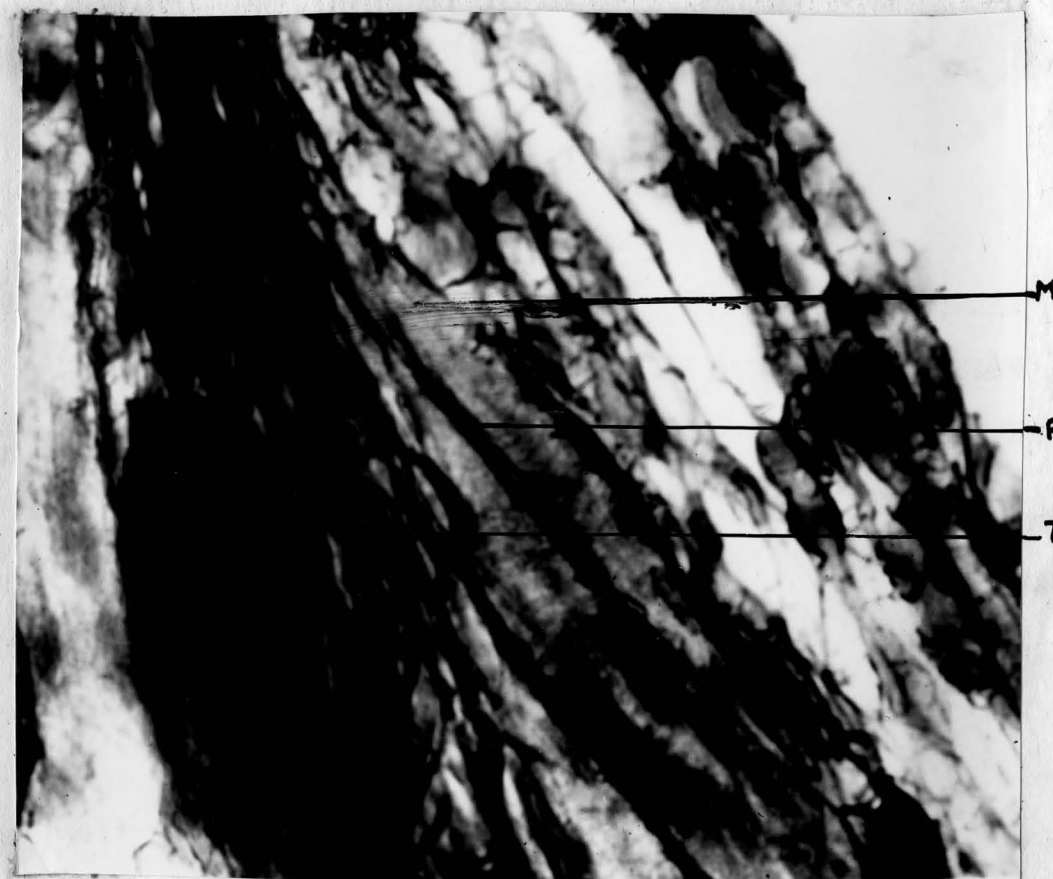


Figure 4

## PLATE V

## Figure 5

Three day post-partum muscle fibers showing nuclei in their terminations. Fixation, 10 per cent calcium formalin; stain, Bielschowsky method. x1000.

M--muscle fiber

N--nuclei at tip of muscle

T--tendon

F--fibroblast

## PLATE V

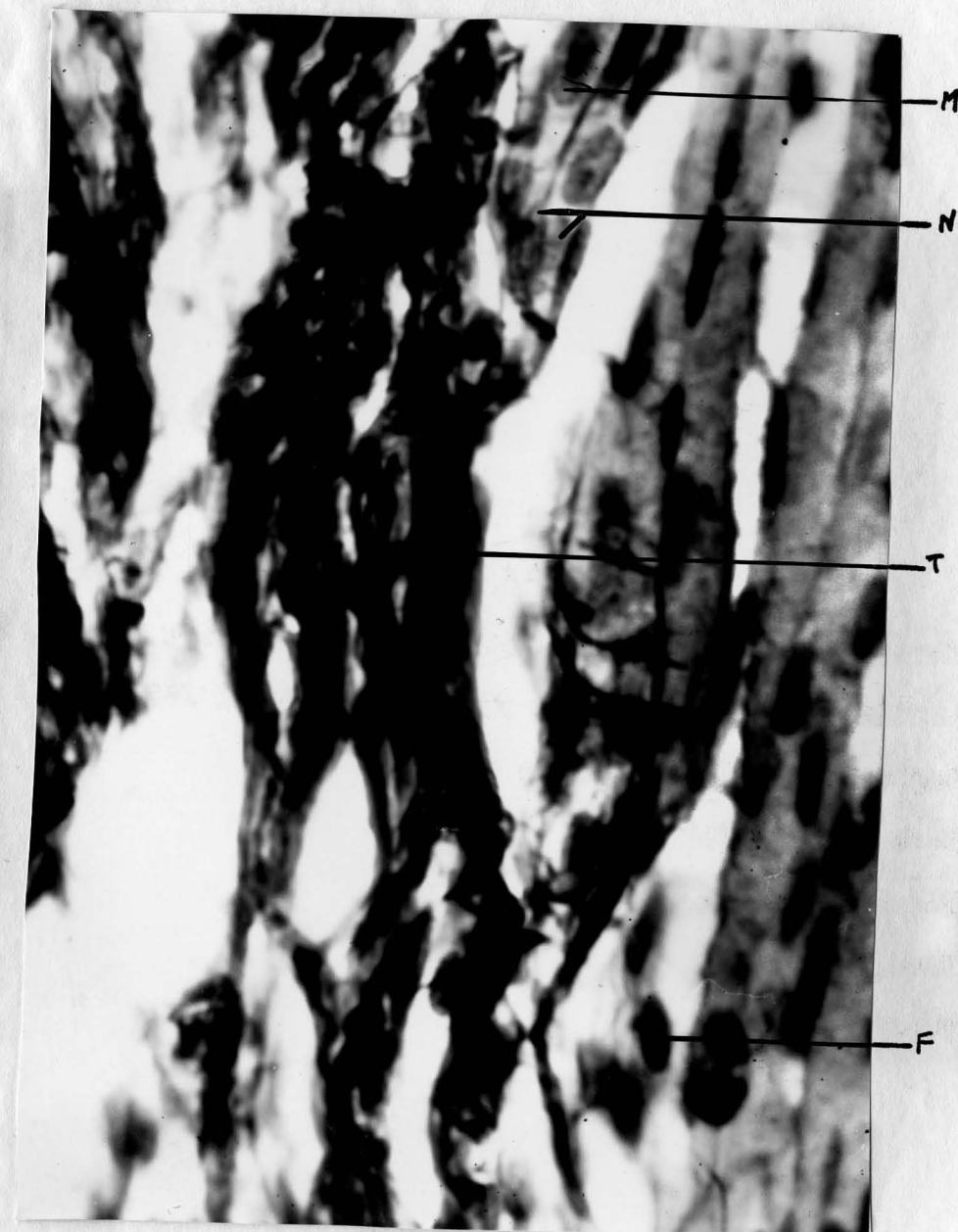

Figure 5



## PLATE VI

## Figure 6

Muscle-tendon junction of a twelve day old rat. The endomysium consists of reticular and collagenous fibers which terminate between the tendon fibers. Fixation, 10 per cent formalin; stain, Bielschowsky method. x1000.

M--muscle fiber

T--tendon

Mt-termination of muscle

E--endomysium

## PLATE VI



Figure 6



## PLATE VII

## Figure 7

Separated muscle tendon junction in the fifteen day old rat. Heavy reticular fibers continue into the tendon. The muscle fiber terminations contain nuclei, and the striations continue to the tip of the cell. Cross branching reticular fibers are also obvious. Fixation, Helly's fluid; stain, Bielschowsky method. x1000.

M--muscle fiber

N--nucleus

MT--muscle fiber termination

R--reticular fiber

## PLATE VII

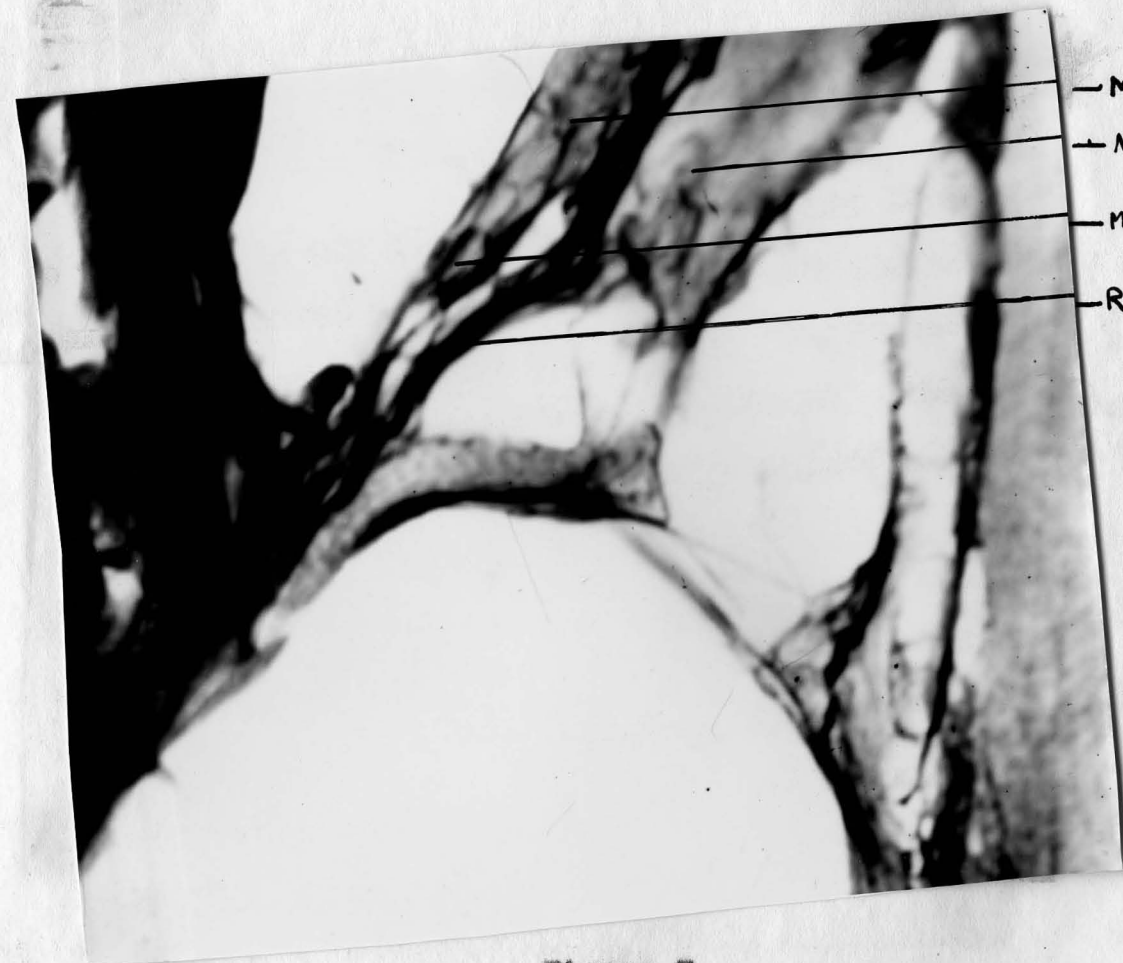


Figure 7



## PLATE VIII

Figure 8

A diagram of the manner in which the muscle fiber is attached to the tendon. The fibrous stocking surrounds the muscle fiber and continues into the tendon.

M--muscle fiber

R--reticular fibers

T--tendon

E--endomysium

C--collagenous fiber

## PLATE VIII




Figure 8