



1961

The Historical Changes in the Tooth and Surrounding Structure Following Apicoectomy in Dogs

Gokul Das Ojha
Loyola University Chicago

Follow this and additional works at: https://ecommons.luc.edu/luc_theses

 Part of the [Medicine and Health Sciences Commons](#)

Recommended Citation

Ojha, Gokul Das, "The Historical Changes in the Tooth and Surrounding Structure Following Apicoectomy in Dogs" (1961). *Master's Theses*. 1476.

https://ecommons.luc.edu/luc_theses/1476

This Thesis is brought to you for free and open access by the Theses and Dissertations at Loyola eCommons. It has been accepted for inclusion in Master's Theses by an authorized administrator of Loyola eCommons. For more information, please contact ecommons@luc.edu.



This work is licensed under a [Creative Commons Attribution-Noncommercial-No Derivative Works 3.0 License](#).
Copyright © 1961 Gokul Das Ojha

**THE HISTOLOGICAL CHANGES IN THE TOOTH AND SURROUNDING
STRUCTURE FOLLOWING APICOECTOMY IN DOGS**

By

Gokul Das Ojha

**A Thesis submitted in partial fulfillment
of the requirements for the Degree of
Master of Science to the Graduate School
of Loyola University**

Chicago

June 1961

LOYOLA UNIVERSITY MEDICAL LIBRARY

VITA

Gokul Das Ojha

Born in Calcutta, India, December 3, 1932

Attended Public School in Calcutta. Matriculated June 1948.

Pre-dental: Bangbasi College, Calcutta, 1948-1950.

Studied B. Sc. - City College, Calcutta, 1950-1952.

Received the degree of Bachelor of Dental Surgery from the
Calcutta Dental College, Calcutta University, 1957.

Honorary Clinician Oral Surgery Department Calcutta Dental
College Hospital, January 1958-July 1958.

D.P.D. Queen's College Dental School, University of St. Andrews,
U.K., June 1959.

Member All India Dental Association.

ACKNOWLEDGEMENTS

This research work was initiated with the help of Dr. Nicholas Choukas, to whom I am indebted for his supervision. To Dr. Patrick Toto I am deeply grateful for his patience and constructive criticism and photomicrography. Above all I owe a special sense of gratitude to Dr. Joseph G. Kostrubala, for his generous assistance, advice and many helpful suggestions.

I also sincerely appreciate with thanks the help rendered by Dr. Maria Gylis and the associates in preparing the microscopic sections.

TABLE OF CONTENTS

| CHAPTER | PAGE |
|----------------------------------|------|
| INTRODUCTION..... | 1 |
| REVIEW OF THE LITERATURE..... | 6 |
| METHODS AND MATERIALS..... | 15 |
| FINDINGS..... | 17 |
| DISCUSSION..... | 30 |
| SUMMARY AND CONCLUSIONS..... | 35 |
| BIBLIOGRAPHY..... | 37 |
| PHOTOS AND PHOTOMICROGRAPHS..... | 41 |

INTRODUCTION

History of dental diseases is as old as the history of mankind itself. A reference to the physical anthropology and examination of the centuries - old skulls found in the different parts of the world at different ages will confirm this belief. Although the nature and intensities of the different varieties of dental disease vary from country to country, as revealed by the epidemiological studies of various investigators, the scientific data at our disposal leads us to accept the existence of dental ailments since the beginning of history.

Root-resection, also known as apicoectomy and meaning amputation of the apex of the root, originated as a treatment for dento-alveolar abscess in early eighties as revealed by a glance through the old periodical dental literature. It has been impossible to locate the originator of this operation. The first description of a case in which an alveolar abscess of long standing was treated by incision through the soft tissue and the alveolar plate is that which is described in the Dental Register of 1856-1857 by Prof. White who operated on a 14-year old boy in 1846. (Transaction of the A.D.A. 1863-1864). Long before the

complete excision of the end of a root was performed, the operation of entering through the alveolar process with a trephine and a bur in the dental engine and drilling away the diseased area of tissue, was quite well established. This led to the more radical method of completely excising the end of a root and the total amputation of one of the roots of the multi-rooted teeth.

In the primitive age of root-resection, the early pioneers in this field started without any form of anesthesia and applied 95% Phenol on the gum, scraped the coagulated tissue until the alveolar bone covering the apex of the involved tooth was exposed for trephining and burring. Later on local injection of Cocaine was tried as an anesthetic. Compared to these crude methods, the current scientific and refined technique of root-resection is a big advancement towards the successful achievement of the goal of apicoectomy.

In this connection the names of Drs. Farrar, Rhein and Atkinson in America and Dr. Dunn in England are the earliest to appear in our literature. These early enthusiasts, especially Dr. Farrar, were very prompt to advocate what they call the heroic method of treating an alveolar abscess by total amputation of the root. Dr. Rhein presents 3 such cases, which he treated in 1882, at the 13th annual meeting of the A.D.A. in

1891. We find the operation referred to by Dr. Dunn in England in the British Journal of Dental Science in 1884. In the American System of Dentistry, published in 1886, Dr. G. V. Black devotes a few pages to it with cuts illustrating the technique. Among other things Dr. Black states that this operation has been recommended for at least two decades prior to 1886. After that the subject drew the attention in the continent especially in Germany.

In the Dental Review of 1890 C. E. Bentley reports of a case of apicoectomy which was performed before the senior class of C.C.D.S. by Dr. Truman Brophy using 4% solution of Cocaine hydrochloride by injection as an anesthetic.

With the origin of the theory of focal infection this received a severe blow. All infected teeth were condemned. The wane of enthusiasm seemed to recede and this operation received considerable criticism.

In the autumn of 1921 Dr. Thomas P. Hinman of Atlanta, Georgia, read a paper before the 1st. Dist. Dental Society in New York City on the management of infected teeth in which he remarked, "Apicoectomy is rarely successful." This prompted the editor of Dental Items to send letters of inquiry for an opinion on this question to several men of wide repute of those days on this phase of dentistry. Dr. Joseph Novitsky of San

Francisco and Dr. Carl Lucas of Indiana opposed this treatment whereas Dr. Theodore Blum of New York and Dr. Kurt H. Thomas of Boston favored it. This investigator feels that apicoectomy still has its place and why should not it succeed at least in carefully selected cases, if not in all.

The histological changes following apicoectomy can be divided into two classes:

- I) changes involving the Dental tissues themselves (e.g. Dentine, cementum etc.)
- II) Changes taking place in the periodontal structures (e.g. Periodontal membrane and the surrounding bone.)

The ideal results in root-resection would be the covering of the resected surface of the root by a new layer of cementum. This new layer of cementum should be covered by periodontal membrane. Moreover the space formerly occupied by the resected apical part should be filled with bone. This would be ideal. Most of the experimental root-resection was performed on the root-filled teeth. But the results obtained by various investigators, as will be clear from the review of literature shortly, are in some cases not only far from ideal but also histologically markedly dis-similar varying in the extreme from bone regeneration to infection and abscess formation. Euler was the first to attempt this procedure on a living pulp in addition to a few

root-filled teeth. Sacrificing the animals from six to twelve weeks, he found no instance of complete healing but observed inflammation and abscess formation.

Since only one such experiment on living pulp by Euler has been performed and his findings of apicoectomy on root-filled as well as vital pulp are the same it was desired to continue Euler's experiment to see if any kind of reparative activity could be observed and a clearer picture be obtained if the experiment is continued for a longer period.

REVIEW OF LITERATURE

The work so far reported in this field by different investigators with divergent findings can be divided into the following two classes for review.

- (I) Experimental root-resection on laboratory animals and
- (II) Histologic observation on human material.

(I) Experimental root-resection on laboratory animals:

- A. The first experimental study of root-resection was done by Bauer in 1922 on cats in Germany. He resected the root-apices of six maxillary canines. The animals were sacrificed after a period of one to six months. The microscopic examination of the histologic sections showed newly formed cementum covering the trans-section of the root stump on both sides which in its turn was grown-over by the periodontal membrane. He also found osteoid-like tissue over the stump.
- B. In 1923 Euler performed root-resection on the canines of dogs, sacrificing them from six to twelve weeks. The number of animals used is not known. One tooth was not root-filled. He found no instance of complete healing and observed various degrees of inflam-

mation and abscess-formation.

C. In 1923 Bauer made a further study of root-resection this time working on three dogs and two cats. Using the maxillary canines he sacrificed the animals from one to six months. Several sections showed regeneration of bone and periodontal membrane over the newly laid cementum on the root-stump. A few sections showed abscess formation.

D. In 1929 Schachtel amputated the roots of ten maxillary and mandibular canines in three dogs. The animals were sacrificed from one to six months. He showed histologically that:

(a) In seven specimens there were regeneration of bone, periodontal membrane and cementum but

(b) In three specimens there were infection and abscess-formation.

The experimental root-resection can be summarized as follows:

The experimental investigation on this problem was carried out in Germany between 1922-1929. Dogs and cats were used as laboratory animals. The teeth operated upon were the maxillary and mandibular canines or both. The animals were sacrificed from one to six months. The problem was attempted by three

different workers at four different times. Two of the three investigators (Bauer and Schachthel) had the root canals filled while Euler performed apicoectomy on one of the teeth that had no root filling of any kind in addition to the other teeth which were root-filled. Their results, as enumerated above, are markedly different. A brief summary of the experimental work in a tabular form appears on the next page.

SUMMARY OF THE EXPERIMENTAL WORK ON ROOT-RESECTION IN TABULAR FORM

| <u>YEAR</u> | <u>INVESTIGATOR</u> | <u>ANIMAL USED</u> | <u>NUMBER OF ANIMALS USED</u> | <u>NUMBER OF TEETH</u> | <u>FINDINGS</u> |
|-------------|---------------------|------------------------|-----------------------------------|----------------------------|--|
| 1922 | Bauer | Cats | Three | Six | Root stump is grown-over by the newly formed cementum which is then covered by the periodontal membrane |
| 1923 | Euler | Dogs | Not known | - | No instance of complete healing, but various degrees of inflammation and abscess formation is present |
| 1925 | Bauer | Dogs Cats | Three Two | Ten | Several sections show bone regeneration and regeneration of periodontal membrane over the newly laid cementum on the root-stump. A few sections show abscess formation |
| 1929 | Schachtel | Dogs | Three | Ten | In seven specimens - new cementum was deposited, periodontal membrane and bone regenerated. In three sections abscess formation was noticed. |

(II) Histologic observation on human material:

Nobody has so far reported on the histological appearance of an area of root-resection from human autopsy material. Since the source of available and studied human material was mostly the regular office patient on whom root-resection was performed sometime back and such teeth had to be extracted due to one reason or another, no more than the usual amount of tissue as would normally come out with an extracted tooth, could be attempted out. Hence all those who described the histological appearance of this material could report only on the nature of the dental tissue covering the resected root-end and even these findings differ as will be clear from the following:

In 1928 Dr. Rudolf Kronfeld at the University of Vienna histologically examined the root of a second bicuspid on which apicoectomy was performed one year back. He found new deposition of cementum on the cross-section of the old cementum. The dentine showed neither apposition nor absorption and remained bare. Inflammation was also present. He attributes inflammation to the harboring of infection by the dentinal tubules.

In 1929 Cook in Dental Cosmos reports of a case where a granuloma on the resected end of the root was found when the tooth was extracted ten years after apicoectomy.

The granuloma on culture gave streptococci.

In 1930 Dr. Edgar Coolidge presents the histologic report of a case of root-resection after fourteen years showing that the newly formed cementum covered the exposed old dentine and old cementum completely and the dense fibrous connective tissue extends from one side of the canal to the other.

In 1931 Dr. Aisenberg reports of a case four years after apicoectomy. He finds that new cementum is being deposited although round-cell infiltration is present.

In 1934 Parrot and Wellings present, in the odontological section of the Transactions of the Royal Society of Medicine, case of a twenty-five year old girl whose upper right lateral incisor had root-resection and was extracted seven years later. They demonstrate the laying down of new cementum over the old cementum and dentine. The newly laid cementum in its turn is covered by the periodontal membrane. A granuloma is also present.

In 1940 Moen published the histological preparations of root-resected teeth. He demonstrates regeneration of cementum over the entire resected surface except the canal foramen which is covered with connective tissue. The new cementum is then covered by the periodontal membrane.

Herbert in 1941 published the histological findings of the four root-resected teeth. In two cases there was regeneration of cementum on the resected surface. In the other two teeth, the resected surfaces remained bare.

In 1943 Herbert describes the histological picture of the upper left lateral incisor of a thirty-one year old patient six years after apicoectomy. He shows that fresh cementum covers the old cementum and dentine over the resected surface. In one place there has been resorption of dentine prior to the deposition of cementum. The soft tissue overlying the canal shows round-cell infiltration.

Generalization of the report on human material:

So far few investigators have reported histologically on the nature of dental tissues covering the resected end of the root. Their results, varying as they are, range from infection, abscess-formation, to the laying down of cementum in various proportions.

METHODS AND MATERIALS

The material in connection with this project was obtained by experimental surgery on dogs. Ten healthy dogs were selected. They were anesthetized with 5% Nembutal, one cc. per five pounds of body weight intraperitoneally supplemented with local infiltration of the anterior segment of the jaw by 2-3 cc. of a 1% solution of Procain-hydrochloride containing 1:50000 Epinephrine. Under aseptic conditions the incision was made labially extending from mid-line to the distal of the left canine about 2-3 mm. below the crest of the gingiva with a number ten blade. The muco-periosteal flap was reflected down with periosteal elevator. A window was cut with a bur through the bone overlying the apex of the lateral incisor. About 3-4 mm. of the apex of the root of the tooth was cut with the bur. The resected apical end was taken out. The rough edges of the defect thus created were smoothed with a bone-file and the area flushed with normal saline. The muco-periosteal flap was replaced and sutured with 000 silk. The dogs were maintained on Purina dog food and water ad libitum. They were kept under regular periodic observation and sacrificed at the intervals of twenty-four hours, seventy-two hours, nine days, two weeks, one month, two months, three months and six months. The block of the jaw containing the left incisors was sawed out and the specimen submitted to the labora-

tory for the preparation of serial microscopic sections. The sections were stained with hematoxylin and eosin, examined under the microscope and the findings reported.

A brief summary of the dog-work appears below:

| Serial No. | Weight in lbs. | Date of operation | Post-op. | | Casu-ality | Date of Sacrifice | Specimen |
|------------|----------------|-------------------|----------------------|--------------------|-------------------------------------|-------------------|------------|
| | | | Immediate | Follow-up | | | |
| 1 | 17 | 6/21/60 | No compli- cation | Sick on 9th day | | 6/30/60 | 9 days |
| 2 | 19 | 6/24/60 | No compli- cation | Unevent- ful | | 12/25/60 | 6 mos. |
| 3 | 19 | 6/27/60 | No compli- cation | Unevent- ful | | 6/28/60 | 24 hrs. |
| 4 | 25 | 6/27/60 | No compli- cation | Unevent- ful | | 7/12/60 | 2 weeks |
| 5 | 20 | 6/28/60 | No compli- cation | Unevent- ful | | 7/1/60 | 72 hrs. |
| 6 | 20 | 7/1/60 | No compli- cation | Unevent- ful | | 7/30/60 | 1 mo. |
| 7 | 30 | 7/22/60 | No compli- cation | Unevent- ful | | 9/23/60 | 2 mos. |
| 8 | | 7/23/60 | No compli- cation | Unevent- ful | | 10/22/60 | 3 mos. |
| 9. | | 7/29/60 | No compli- cation | Sick on 2nd day | Died of pneumonia | per autopsy | |
| 10. | 24 | 9/1/60 | No compli- cation | Sick | Died of Pneumonia on 10/14/60 | | 1½ mos. |

FINDINGS

The Twenty-four hour specimen:

The stratified squamous epithelium of the oral mucous-membrane shows a break in its continuity at the site of incision. Fibrous connective-tissue and mucous-glands are present in the sub-mucosa.

A blood-clot fills the space formerly occupied by the apex of the root and also covers the resected surface. The clot contains fibrin, haemosiderin (a blood pigment) and red blood cells. A few polymorphonuclear leukocytes are also present in the clot. Some fragments of tooth substance are also entangled in the clot, which at some places is extending into the marrow spaces of the surrounding cancellous bone.

There is no evidence of any change in dentine and cementum on the resected surface. The pulp shows polymorphonuclear leukocytic infiltration.

The periodontal membrane is slightly inflamed and the fibers are unravelled.

The lingual alveolar process consists of normal cancellous bone.

The Seventy-two hour specimen:

The oral epithelium shows a break in its continuity at one point. The sub-mucosa contains the fibrous connective tissue and mucous glands.

A blood-clot is filling the space formerly occupied by the apex of the tooth. Some fragments of the tooth substance are enclosed in the clot. Many red blood cells, some polymorphonuclear leukocytes and a few histiocytes are present in the haemolysed blood. The clot extends into the marrow spaces too.

There is no change in dentine and cementum on the resected surface which is in contact with the blood clot. The pulp shows polymorphonuclear leukocytic infiltration.

The periodontal membrane shows capillaries which are dilated and polymorphonuclear leukocytes in the perivascular spaces.

The connective tissue in the bone marrow shows proliferation of reserve connective tissue cells. Osteoclasts have differentiated and are seen on the cut surface of the bone where there is also evidence of osteoclasia.

The Nine-day specimen:

The oral epithelium is continuous. Fibrous connective tissue and mucous glands are contained in the mucosa.

The defect, created by apicoectomy, is filled with an organizing blood clot. The clot contains haemolysed blood pigment, many polymorphonuclear leukocytes and some histiocytes. New young capillaries are vascularising the periphery of clot. Some fragments of tooth substance are also entangled in the clot.

There is no change in the dentine and cementum on the

resected surface of the tooth which is in contact with the organizing clot. The pulp still shows polymorphonuclear leukocytic infiltration and necrosis of the odontoblasts and reserve connective tissue cells.

Dense collagen fibers are present in the peridental membrane. The periodontal membrane adjacent to the resected area shows inflammation and the presence of polymorphonuclear leukocytes.

A few osteoclasts are seen in the marrow as well as on the cut surface of bone.

The Two-week specimen:

There is a break in the labial mucosa and sinus tract. Generally the mucosa and the sub-mucous structures are normal.

In the peri-apical space some thread-like micro-organisms are seen. The micro-organisms are surrounded by a zone of connective tissue which contains many polymorphonuclear leukocytes, some fibroblasts and a few undifferentiated cells. At one place some epithelial cells are lining the space and show some proliferation.

On the resected surface of the root there is neither resorption of the dentine and cementum nor any evidence of deposition of cementum. The pulp is oedematous, structureless and almost completely necrosed.

Adjacent to the resected area the periodontal membrane is attached lingually but on the labial side it is detached probably due to the plane of section.

There is proliferation of reserve cells in the bone marrow. Remodelling resorption of the alveolar bone characterized by bone resorption and apposition is evident.

The One-month specimen:

The oral mucosa and the sub-mucosa with its contents appear normal.

The defect, created as a result of apicoectomy, is filled with fibrous connective tissue.

There is little resorption of cementum and dentine on the resected surface. The pulp is necrotic.

The periodontal membrane shows some osteogenesis near the resected surface and indicates ankylosis of tooth and alveolar bone. There is evidence of apposition of bone on the superior lip of the defect in the alveolar process.

The One and a half month specimen:

The oral epithelium is continuous. Sub-mucosa with its contents appears to be normal.

The defect, resulting from the apicoectomy, is occupied by loose connective tissue. There are numerous dilated capillaries, plasma cells and some polymorphonuclear leukocytes.

Around the capillaries there are dense collagenous fibers. A residual granuloma surrounded by fibrous connective tissue, some polymorphonuclear leukocytes and histiocytes is also present.

On the resected surface of the root there is slight resorption. The pulp is necrosed.

The periodontal membrane shows loose connective tissue which is continuous on both sides with the connective tissue fibers in the defect.

The labial plate of bone which was cut during the surgical procedure is missing and is replaced by fibrous connective tissue. New bone is forming on the superior wall of the defect in the alveolar process.

The Two-month specimen:

The oral mucosa and the sub-mucosa with its contents appear normal.

The defect, created by the experimental surgery, contains a granuloma surrounded by fibrous connective tissue, collagenous fibers and some polymorphonuclear leukocytes and histiocytes.

On the resected surface of the root a thin layer of cementum has been laid down on the old cementum and a part of the dentine. The pulp canal contains necrotic pulp.

The periodontal membrane is intact on both sides and is

continuous with the fibrous connective tissue which is encircling the granuloma.

Only fibrous connective tissue is replacing the labial plate of bone which was removed during the surgical procedure.

The Three- month specimen:

The oral mucosa and the sub-mucosa with its contents appears to be normal.

The periapical defect is occupied by a granuloma which in its turn is surrounded by fibrous connective tissue. Some polymorphonuclear leukocytes, histiocytes and plasma cells are present. At the periphery of the granuloma there is formation of new bone continuous with old bone of the defect.

On the resected surface of the root a thin layer of cementum has been laid down on the old cementum and a part of the exposed dentine. The pulp is necrotic.

The periodontal membrane is intact on both sides and is continuous with the fibrous connective tissue which encircles the granuloma.

The labial plate of bone removed during the surgical procedure has been replaced by fibrous connective tissue. The lingual plate is, however, intact.

The Six-month specimen:

There is no break in the continuity of the oral epithelium.

The mucosa and the sub-mucosa appear to be normal.

The residual bony defect is not repaired by bone. Overlying the opening of the canal on the resected surface there is amorphous material and many polymorphonuclear leukocytes. There is a lining of stratified squamous epithelium extending from one side to the other. This epithelium blends with the fibers of the periodontal membrane at the periphery on one side. Outside the stratified squamous epithelium there is dense fibrous capsule continuous with the residual bony defect.

A thin layer of cementum has been laid down on the resected surface of the root. There is evidence of resorption of cementum and dentine in that area prior to the laying down of new cementum. The pulp canal contains necrotic pulp.

The periodontal membrane looks normal on the lingual side. On the labial side the periodontal ligament fibers are slightly separated and blend with fibers of the capsule of the periapical cyst.

There is evidence of apposition of bone at the superior lip of the defect in the alveolar process and in the marrow spaces. The surgically created defect in the labial bony plate has been replaced by fibrous connective tissue.

THE BRIEF TABULAR SUMMARY OF THE FINDINGS

| Specimen | Oral Mucosa & the Submucosa | The Surgical Defect | Cementum |
|----------|---|--|--|
| 24 hrs. | Break in the continuity of the oral epithelium. Sub-mucosa slightly oedematous. | Contains blood-clot consisting of fibrin, haemosiderin, some polymorphs and many R.B.Cs. Some tooth fragment is also entangled in the clot. | No change. In contact with the blood-clot |
| 72 hrs. | Break in the continuity of the oral epithelium. Sum-mucosa slightly oedematous. | In addition to the above the blood-clot contains some histiocytes. The histiocytes have phagocytosed the haemosiderin released by the haemolysed blood | As above. |
| 9 days | Oral epithelium is continuous. Submucosa with its contents appears normal | Organization of the clot. New young capillaries are vascularising the clot. | As above. |

cont.

THE BRIEF TABULAR SUMMARY OF THE FINDINGS (Cont.)

| Specimen | Oral Mucosa & the Submucosa | The Surgical Defect | Cementum |
|----------|--|--|------------------------------------|
| 2 weeks | Sinus tract with a break in the continuity of the labial mucosa. | Thread-like micro-organisms surrounded by a zone of connective tissue which contains many polys, some fibroblasts and a few histiocytes. | Neither resorption nor apposition. |
| 1 mo. | Oral mucosa and submucosa look normal. | Filled with fibrous connective tissue. | Little resorption. |
| 1½ mos. | Oral mucosa is continuous. Submucosa looks normal. | Occupied by loose connective tissue; Numerous dilated capillaries, plasma cells and polys present. Dense collagenous fibers present. A residual granuloma surrounded by fibrous connective tissue, some polys and histiocytes present. | Slight resorption. |

cont.

THE BRIEF TABULAR SUMMARY OF THE FINDINGS (Cont.)

| Specimen | Oral Mucosa & the Submucosa | The Surgical Defect | Cementum |
|----------|--|---|--|
| 2 mos. | Oral mucosa and submucosa with its contents appear normal. | Granuloma surrounded by fibrous connective tissue, collagenous fibers and some polys and histiocytes. | A thin layer of cementum laid-down. |
| 3 mos. | As above. | Granuloma surrounded by fibrous connective tissue, some polys, histiocytes and plasma cells also present. | As above |
| 6 mos. | As above. | Amorphous material and polys overlie the opening of the canal on the resected surface. Stratified squamous epithelial lining extending from one side to the other, blends with the fibers of the periodontal ligament at the periphery on one side. Outside the epithelium there is dense fibrous capsule continuous with the residual bony defect. | A thin layer of cementum has been laid down. |

| | The Tooth Dentine | Pulp | Periodontal Membrane | Surrounding Bone |
|--------|--|---|---|---|
| 24 hrs | No change. In contact with the blood-clot | Shows polymor- phonuclear leukocytic in- filtration. | Appears inflamed. Fibers are unravelled. | The blood-clot extends into the marrow space of the sur- rounding cancellous bone. |
| + | | | | |
| 72 hrs | As above | As above | Capillaries dilated and perivascular polymor- phonuclear leukocytic immigration. | Proliferation of Reserve cells in the marrow connec- tive tissue. Differentiation of osteoclasts which are seen on the cut surface of bone. Evidence of osteoclasia. |
| 9 days | As above | As above | Adjacent to the cut sur- face shows inflammation and polys. | Osteoclasts on the cut sur- face of the bone and in the bone-marrow present. |
| 2 wks | Neither re- sorption nor apposition | Oedematous, structureless and almost ne- crosed | Attached lingually but detached labially. | Proliferation of reserve cells in the marrow. Re- modelling resorption of alveolar bone going on. |

cont.

| | The Teeth Dentine | Pulp | Periodontal Membrane | Surrounding Bone |
|--------|---|----------|---|--|
| 1 mo. | Little re- sorption | Necrotic | Evidence of osteogenesis near resected surface. | Bone apposition on the super- ior lip of the defect in the alveolar process. |
| 1½ mos | Slight re- sorption | Necrotic | Shows loose connective tissue continuous on both sides with the con- nective tissue fibers of the defect. | Labial plate of bone, re- moved during surgery, is missing and replaced by fibrous connective tissue. New bone forming on superior wall of the defect in alveo- lar process. |
| 2 mos | A thin lay- er of cemen- tum laid-down on a part | Necrotic | Intact on both sides and continuous with the fi- brous connective tissue encircling granuloma. | Fibrous connective tissue is replacing the labial plate of bone removed during the sur- gery. |
| 3 mos | As above | As above | As above | As above |

cont.

| | The Tooth Dentine | Pulp | Periodontal Membrane | Surrounding Bone |
|-------|---|------------------|--|---|
| 6 mos | A thin layer of cementum laid down on a part of the dentine | Pulp is necrotic | Looks normal on lingual side. On the labial side the periodontal ligament fibers are slightly separated and blend with the fibers of the capsule of the periapical cyst. | Bone apposition on the superior lip of the defect and in the marrow spaces. The surgically removed labial alveolar bony plate has been replaced by fibrous connective tissue. |

DISCUSSION

When apicoectomy is performed on a tooth containing vital pulp, many structures (e.g. mucosa, periodontal membrane, pulp, dentine, cementum etc. are injured. This is followed by an inflammatory response which is primarily defensive. Each affected tissue tries to repair in it's own way.

The trauma inflicted by the surgical instruments during the procedure involves division of numerous small blood vessels and occurrence of corresponding hemorrhage in the operative field. Fibrinogen, a plasma protein, undergoes transformation into a mesh of fine thread of fibers, called fibrin, in which are entangled many types of blood cells and thus a clot is formed. The clot, obliterating the space and glueing the adjacent structures together, sets the stage for repair by protecting the wound from any untoward infection until the arrival of defensive cells (e.g. the polymorphs, macrophages etc.) at the area injured. This is essentially what is seen in the 24-hour specimen --a blood clot filling the surgical defect and in contact with the unchanged cementum and dentine and extending into the marrow spaces. Inevitably many cells in the direct path of the line of incision were destroyed and this accounts for the break in the continuity of the oral mucosa.

As the sequence of events continues the red blood cells are hemolysed into hemosiderin (the iron containing fragment of hemoglobin) and hematoïdin. Histiocytes enter the picture and phagocytose this pigment. There is proliferation of reserve connective tissue cells which are totipotent. Some of these reserve cells differentiate into osteoclasts and osteoclasia becomes evident on the cut surface of the bone as seen in the 72-hour specimen.

Gradually the young fibroblasts from the fixed cells and the sprouting endothelial cells from the adjacent capillaries enter the clot and thus starts the "organization of the clot" by it's vascularisation from the periphery. When the mucoperiosteum is sutured in place the edges of the flap are brought closure together with a thin layer of coagulated blood interposed in between. In course of time, as mentioned above, the clot gets organized and the connective tissue regenerates. The oral epithelium from the apposed edges of the flap advances to bridge the gap and thus the continuity of the oral epithelium is established.


Concurrently with the other injured tissues the pulp initially shows inflammation but, being deprived of it's main source of nutrition as a result of this procedure, the resolution does not seem to follow on. Degenerative process, beginning apically, reaches the coronal portion and involves the entire pulp. Unable to recover from the injury inflicted, obviously due to lack of nutrition, the pulp fails to survive. Finally the pulp becomes

necrosed and acts, being non-viable, as an organic irritant. When the irritant is non-viable it's action is too mild to excite an immediate and severe response. Under such circumstances a chronic inflammatory reaction continues to operate more or less continuously for a long period. The resulting tissue responses assume a more complicated pattern than is found with either acute inflammation or tissue repair alone. In these chronic reactions the degree of local intoxication is seldom sufficient to restrain the reparative reactions of the fixed mesenchymal cells. Hence the phenomena of inflammation and repair may go on hand in hand. This intermingling of defensive and reparative processes naturally adds to the heterogeneity of the local cell population and hence in chronic inflammatory reactions, leukocytes of all kinds histiocytes, fibroblasts, and vascular endothelial cells may all be present in large numbers. This investigator feels that the necrosed pulp, acting as the chronic source of irritation, excites a chronic inflammatory response in the periapical area, hinders the reparative process and has a great influence on the final outcome. Had it not been for the presence of this tissue, the end results might have been satisfactory if not ideal. The exact cause of the persistence of the necrosed pulp is the inability of it's disposal through the body defences. As well known, it is almost impossible to sterilize the Oral cavity. Consequently any wound communicating with it is bound to get infested with the

the oral bacterial flora no matter how perfect the operative technique. The sequele is dependent on the virulence of the organism and the resistance of the host in addition to the local factors involved. Hence the periapical inflammation in apicoectomy should not be ruled out and this may partially explain some of the failures met with in this procedure.

Due to the persistence of the chronic periapical inflammation a residual granuloma surrounded by fibrous connective tissue, some polys, histiocytes and plasma cells was formed. This was walled off and prevented from spreading towards the periphery where some reparative changes are evident. This chronicity incites the epithelial cell rests in the periodontal membrane to proliferate and thus at the end of six months a periapical cyst lined by the stratified squamous epithelium results. It is not meant to apply that every single granuloma would turn into a cyst, although in this particular case it has done so. However the existence of a tendency for cystic transformation under such circumstances must not be overlooked.

The labial alveolar plate of bone removed during the time of surgery has been replaced by fibrous connective tissue. What prevents the regeneration of the plate is not known for sure. The persisting chronic inflammation may be a contributory factor. There is only slight regeneration of bone towards the periphery of the surgical defect.



Compared with the results of the previous experimental work, the result of the present investigation is more akin to the findings of Euler who failed to find any instance of complete healing but met with various degrees of inflammation and abscess formation. Euler sacrificed the experimental animals from six to twelve weeks and found abscess formation at the end of this period. It is quite possible that if he would have let his experiment continue for another three months he would have the results very similar to the present findings. This investigator fails to agree with Bauer and Schachtel who report complete healing by regeneration of bone in some of their specimen.

As far as the fate of dentine and cementum on the resected surface is concerned, this experiment partially confirms the findings of Coolidge and Aisenberg that a thin new layer of cementum is laid down on the old cementum and a part of the dentine following their initial resorption.

Thus we see that a chronic inflammation in the center and reparative activity by proliferation and differentiation peripherally is going on concurrently.

SUMMARY AND CONCLUSION

The histological changes following apicoectomy can be divided into changes involving the

- (I) Cementum and dentine on the resected surface and
- (II) periapical area with special reference to the nature of tissue filling the surgical defect.

As there was no general agreement on the final outcome, the present investigation was undertaken with a view of adding additional information on this topic.

Vital apicoectomy was performed on the lateral incisors of ten healthy dogs. The animals were sacrificed from twenty-four hours to six months. Microscopic sections of the specimen were stained with Hematoxylin and Eosin.

The examination revealed that:

- I) the pulp, devoid of it's source of nutrition, undergoes necrosis, acts as a source of chronic inflammation and interferes with resolution.
- II) on the resected surface of the root resorption of cementum and dentine takes place which is then followed by laying down of a very thin layer of new cementum on the old cementum and a part of the dentine.
- III) the periodontal membrane returns to normal after the initial inflammatory changes.

IV) the labial alveolar bony plate, removed during the surgical procedure, is replaced by fibrous tissue.

V) there is slight apposition of new bone on the superior lip of the defect following osteoclasia.

VI) in the surgical defect a periapical cyst lined by stratified squamous epithelium is formed.

The writer is of the opinion that further investigation in this field should be continued by root-filling the tooth prior to apicoectomy. An attempt then should be made to correlate the histological findings with the radiological observations as big clinical and radiographical results are claimed by some of the workers (e.g. Chapman, Ecky-Adams, Englander etc...) in the field of apicoectomy which have as yet not been substantiated histologically.

Bibliography

Aisenberg, Myron S.,--Root Resection after Four Years:

Report of a case.

The Journal of the American Dental Assn.

18:136-40, 1931.

Bauer, Wilhem.--Histologische Befunde and Zahnen nach Wurzel-

spitzenamputation (Histologic Findings on teeth
Following Root Amputation).

Zeitschrift fur Stomatologie, 20:601-06,1922.

Mikroskopische Befunde an Zahnen und Paradentien
nach experimenteller Wurzelspitzenamputation unter
besonderer Berücksichtigung der Bedeutung func-
tioneller Auswirkungen (Microscopic Findings on
Teeth and Periodontal tissues following Experi-
mental Root Amputation with special consideration
of Functional Factors).

Zeitschrift fur Stomatologie, 23:122-35,1925.

Brophy T.W.--Amputation of the Root--Central Incisor

Dental Review 4:943-44,1890.

Chapman, Arthur.--Two cases of Interest

The Australian Journal of Dentistry 54:208,1950.

Cook, T.J.--Dental Granuloma Ten Years after Apicoectomy

The Dental Cosmos, 71:1065,1929.

Coolidge, Edgar D.,--Root Resection as a Cure for Chronic Periapical Infection:

A Histologic Report of a case showing
Complete Repair.

The Journal of the American Dental Assn.
17:239-49, 1930.

Dunn, C.W.,--Alveolar Abscess treated by Amputation of the Fangs
Archives of Dentistry, 1:121-22, 1884.

Eckes, Howard F. and Adams, Frank L.--Combined Root Canal Therapy
and Apicoectomy: A progress report.

The Journal of the American Dental Association
39:66-73, 1949.

Editorial--Excision of the Ends of Roots of Teeth as a step in
the Treatment of Chronic Alveolar Abscess
Dental Review, 2:739-41, 1888.

Englander, J.A.,--Bone Regeneration following Conservative Root
Canal Treatment.

The Journal of the American Dental Association.
27:1733-40, 1940.

Euler, Hermann.--Experimentelle Studie uber den Heilverlauf nach
Wurzelspitzenresektion und uber den Einfluss
verschiedener Wurzelfullungsmaterialien auf den
Heilverlauf, (Experimental Study about the
Healing following Root Amputation and about the
Influence of Various Root-filling Materials upon

the Healing).

Deutsche Monatsschrift fur Zahnheilkunde,

41:321-34, 1923.

Farrar, J.N.,--Radical and Heroic Treatment of Alveolar Abscess
by Amputation of Roots of the Teeth.

British Journal of Dental Science, 27:467-68, 1884.

Hawes, A.C.--Exposed Pulp and Alveolar Abscess

Transactions of the American Dental Association.

15:55-61, 1863.

Herbert, W.E.--Cases treated by Root Resection

The British Dental Journal. 70:173083, 1941.

Histological Examination of Two Teeth Treated by
Root Resection.

The British Dental Journal. 75:205-08, 1943.

Journalistic Summary--Radical and Heroic Treatment of Alveolar
Abscess by Amputation of Roots.

The Dental, Record 4:187, 1884.

Kronfeld, Rudolf,--Zur Frage der Wurzelspitzenamputation (The
Question of Root Amputation).

Zeitschrift fur Stomatologie 26:1105-22, 1928.

Lodge, E.B.,--The Apical Amputation of Roots

Ohio Dental Journal 17:219-21, 1897.

Obed, Moen H.,--Verification of Results of Root Resection by
Photomicrographs.

The Journal of the American Dental Assn.

27:1071-79., 1940.

Rhein, M.L.,--Amputation of Roots as a Radical Cure in Chronic
Alveolar Abscess, Complicated with Pyorrhoea
Alveolaris.

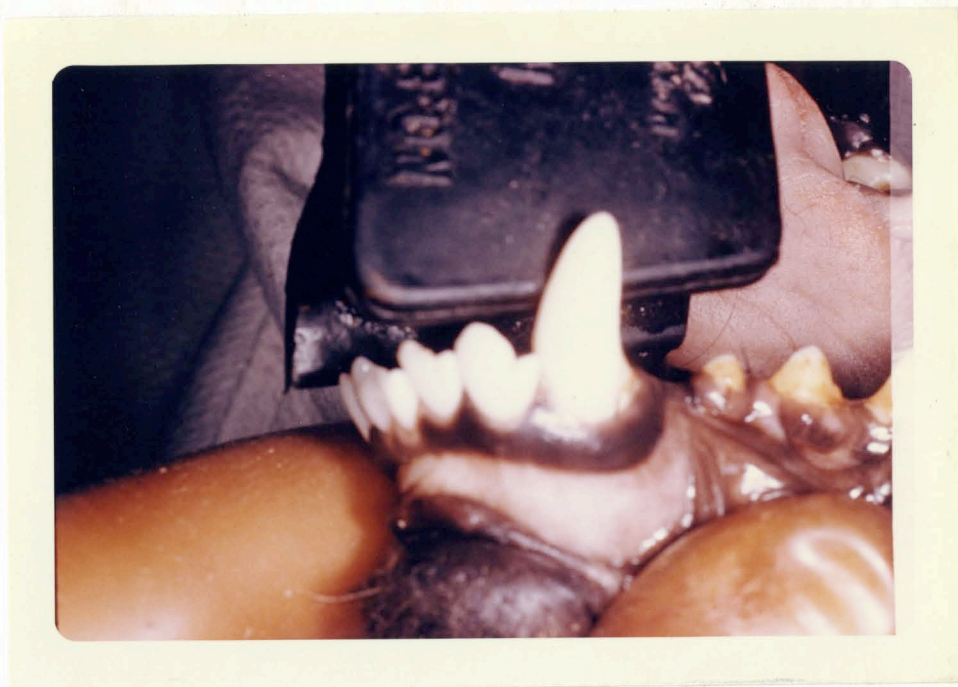Dental Register, 34:505, 1890.

Schachtel, Eli.,--Uber die Heilungsvorgange nach Wurzelspitzen-
-resektion (The Healing Process following
Root Amputation).

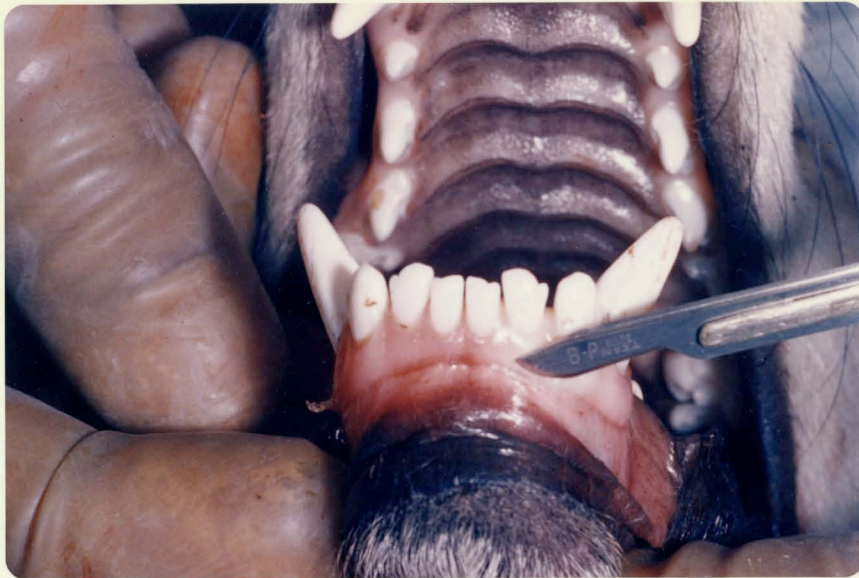
Deutsche Monatsschrift fur Zahnheilkunde.,
47:618-30, 1929.

White.

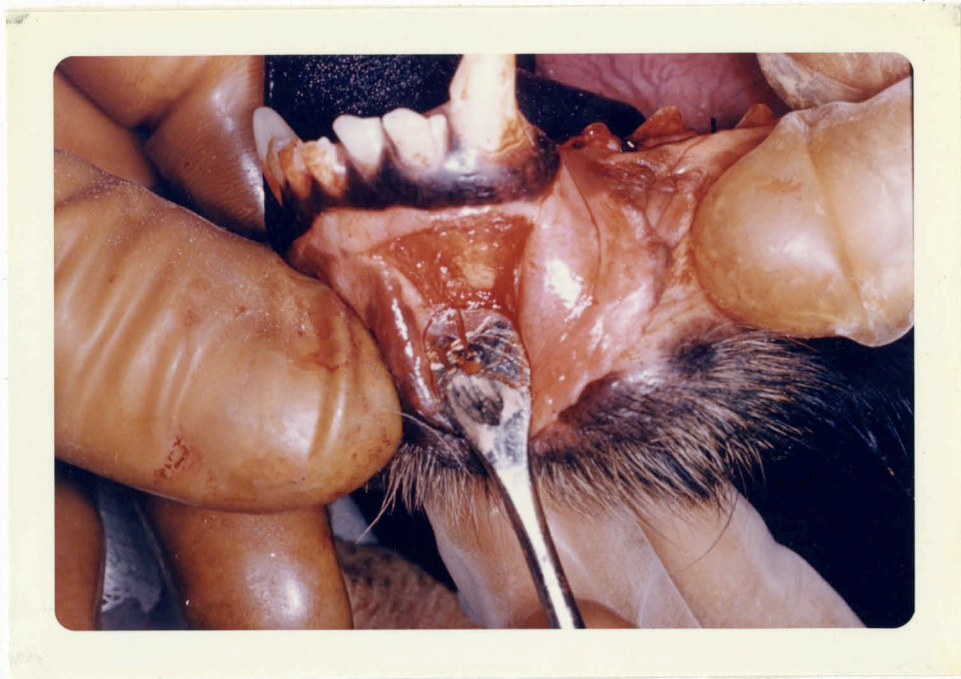Treatment of Alveolar Abscess
Register., 9:104-05, 1855.



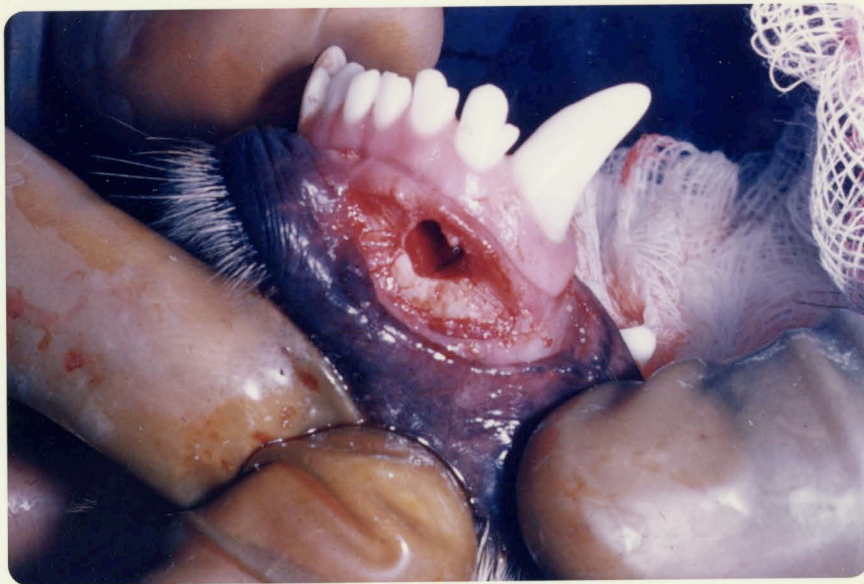Photograph I showing the site of operation extending from the median line to the distal side of the canine.



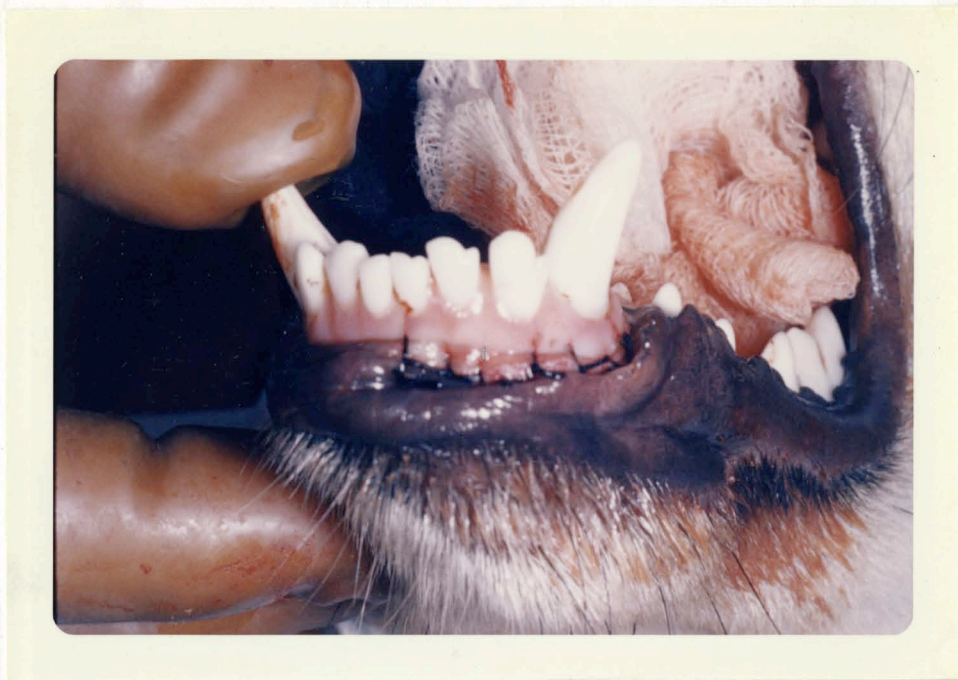Photograph II showing the beginning of the incision in the
left anterior segment of the jaw.



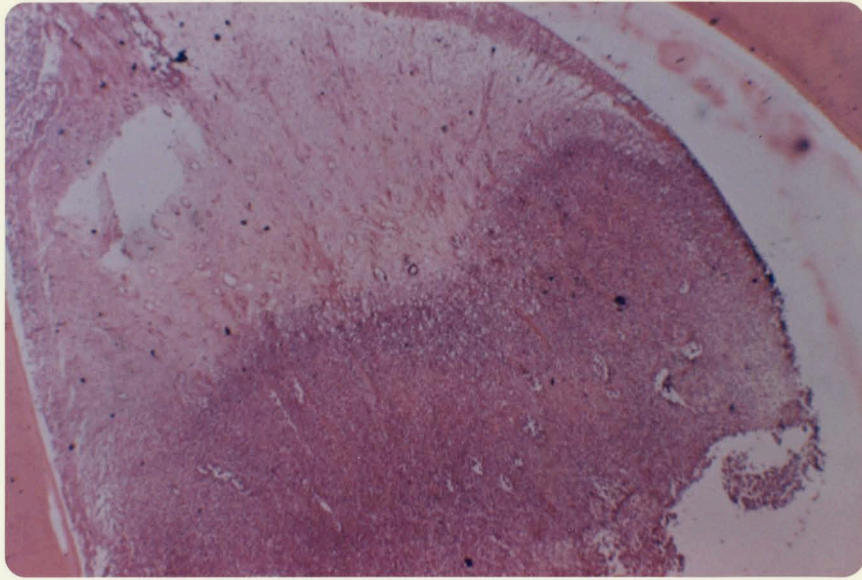
Photograph III showing the muco-periosteal flap reflected.



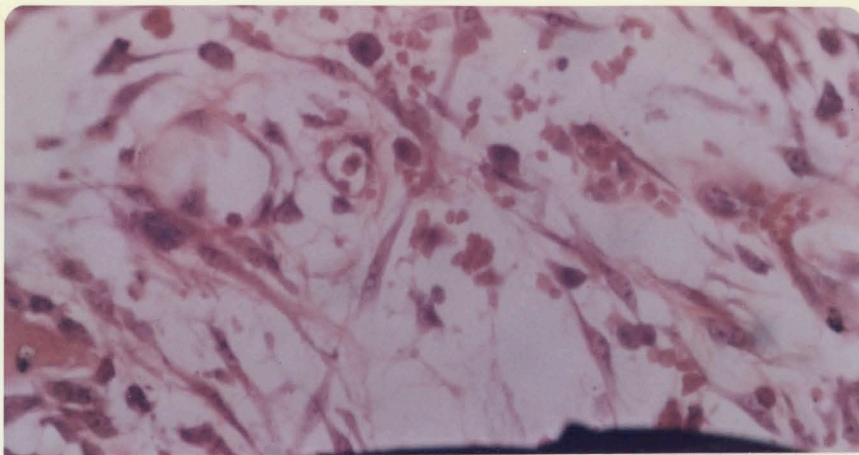
Photograph IV showing the lateral (3rd) incisor after apicoectomy and the overlying alveolar plate of bone removed.



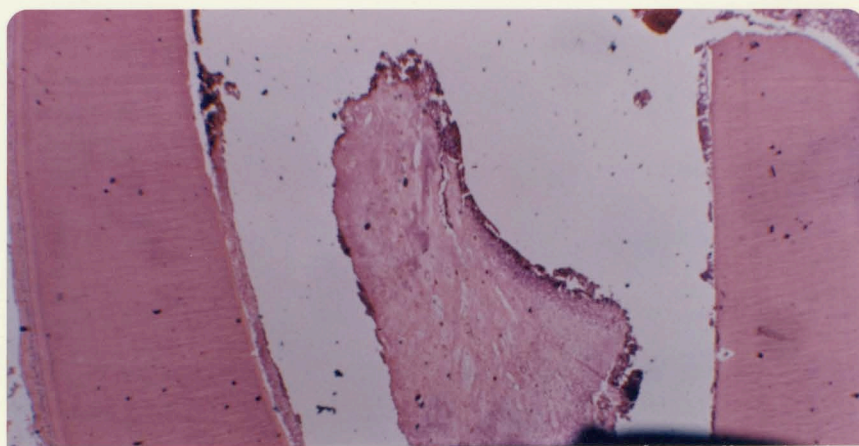
Photograph V showing the wound sutured with 000 silk.



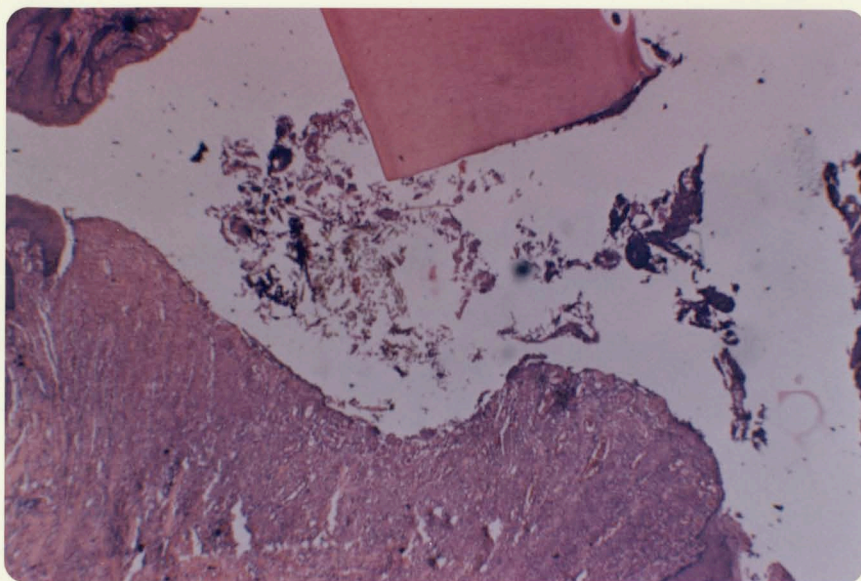
Photomicrograph I showing the severe edema of the coronal portion with nuclear degeneration and the polymorphonuclear leukocytic infiltration of the more apical portion of the pulp.



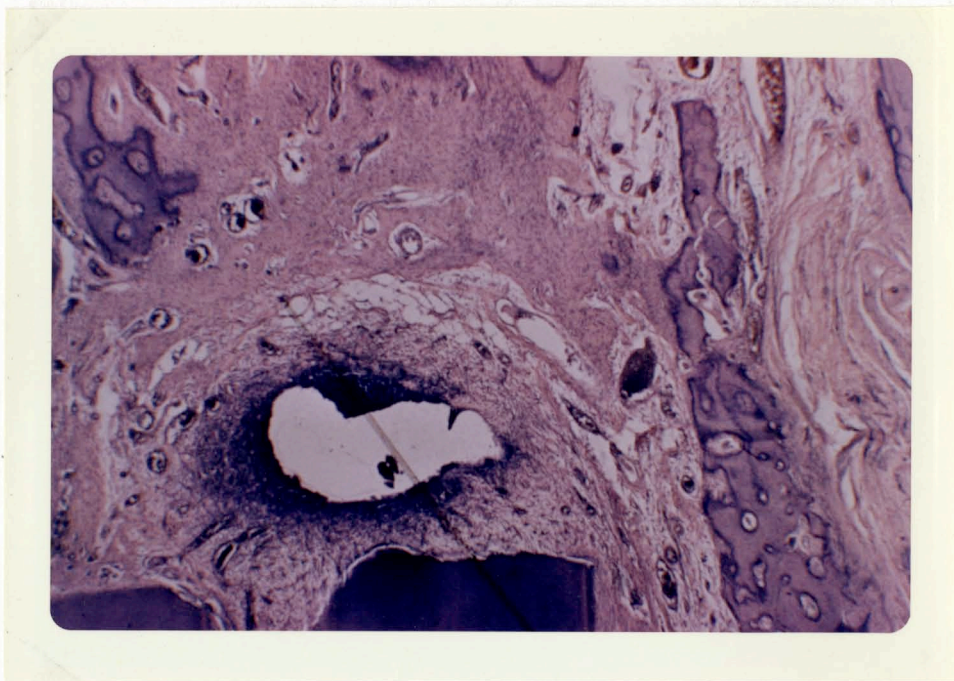
Photomicrograph II A high power view of the periapical area after 72-hours showing undifferentiated cells and young capillaries at the periphery of the clot.



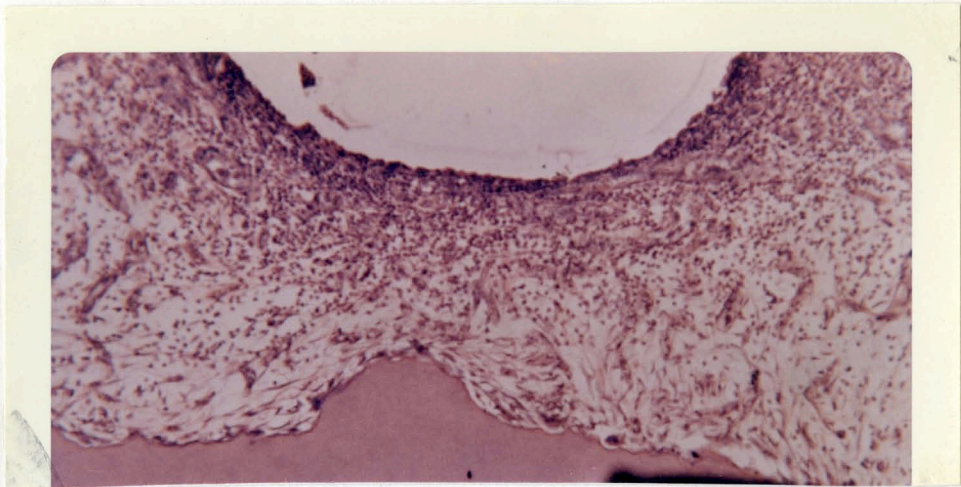
Photomicrograph III --Nine day old specimen showing the necrosed pulp.



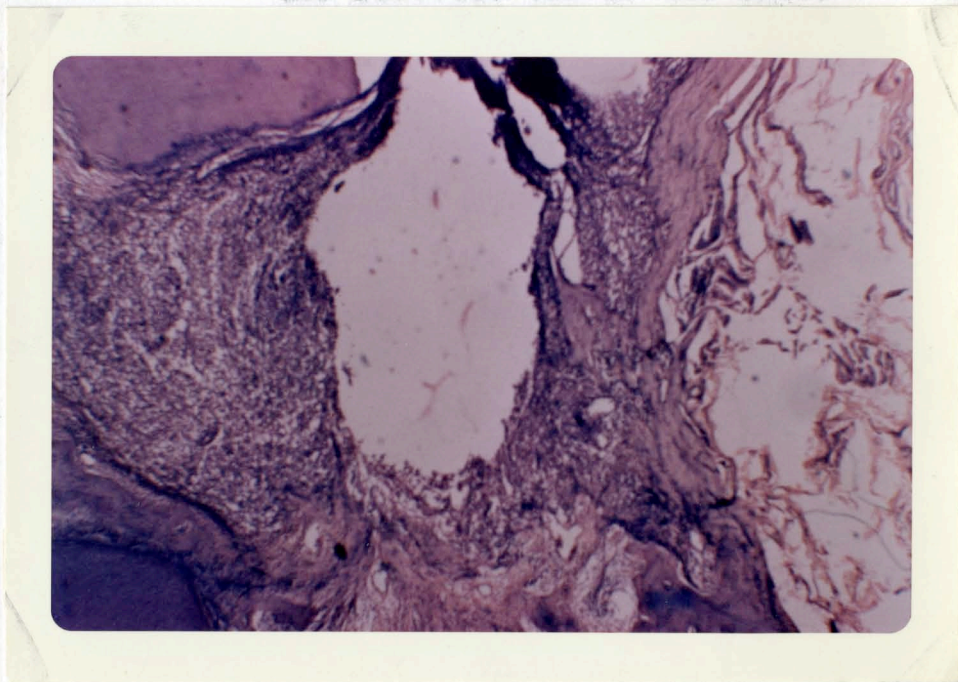
Photomicrograph IV --A portion of the two-week old specimen
the break in the labial mucosa, sinus-
tract and some thread-like micro-organisms.



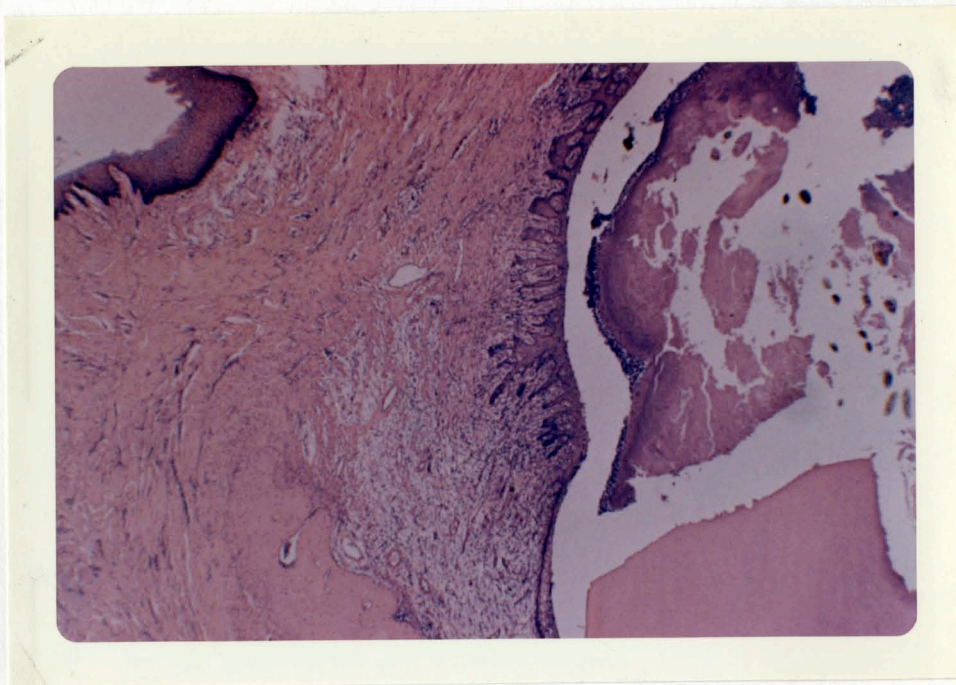Photomicrograph V -- A low power view of the one and a half month slide showing a granuloma on the resected end of the root.



Photomicrograph VI -- A low power view of the one and a half month specimen showing resorption of the resected end of the root.



Photomicrograph VII --A view of the three-month specimen showing a granuloma in the periapical area overlying the resected end of the root and fibrosis on the labial side.



Photomicrograph VIII --A view of the six month slide showing a cyst on the cut end of the root lined with stratified squamous epithelium. The cyst wall is attached to the periodontal membrane on one side. The continuity of the Oral Epithelium has been established. There is fibrosis on the labial side.

APPROVAL SHEET

The thesis submitted by Dr. Gokul D. Ojha has been read and approved by three members of the Department of Oral Anatomy.

The final copies have been examined and the signature which appears below verifies the fact that any necessary changes have been incorporated, and that the thesis is now given final approval with reference to content, form and mechanical accuracy.

The thesis is therefore accepted in partial fulfillment of the requirements for the Degree of Master of Science.

Date 5/26/61

Nicholas C. Choukas
Signature of Adviser