



1966

Hypothalamic Blood Flow and Temperature in the Unanesthetized Normal and Febrile Cat

Rocco Anthony Marrese
Loyola University Chicago

Follow this and additional works at: https://ecommons.luc.edu/luc_theses

 Part of the [Medicine and Health Sciences Commons](#)

Recommended Citation

Marrese, Rocco Anthony, "Hypothalamic Blood Flow and Temperature in the Unanesthetized Normal and Febrile Cat" (1966). *Master's Theses*. 2094.
https://ecommons.luc.edu/luc_theses/2094

This Thesis is brought to you for free and open access by the Theses and Dissertations at Loyola eCommons. It has been accepted for inclusion in Master's Theses by an authorized administrator of Loyola eCommons. For more information, please contact ecommons@luc.edu.



This work is licensed under a [Creative Commons Attribution-NonCommercial-No Derivative Works 3.0 License](#).
Copyright © 1966 Rocco Anthony Marrese

**AN EXPERIMENTAL INVESTIGATION OF THE EFFECTS OF CORTISONE
ON THE KERATINIZATION PROCESS IN THE ORAL EPITHELIUM
OF THE RAT AND ITS RELATION TO THE PROCESS OF
PRECOCIOUS ERUPTION**

by

Diane Grace Mangine



**A Dissertation Submitted to the Faculty of the Graduate School
of Loyola University in Partial Fulfillment of
the Requirements for the Degree of
Master of Science**

June

1967

BIOGRAPHY

Diane Grace Mangine was born on April 18, 1942, in Chicago, Illinois.

She was graduated from the Academy of Our Lady High School, Chicago, Illinois in May of 1960. She attended Mount Mary College, Milwaukee, Wisconsin, and received the degree of Bachelor of Science in May, 1964.

In September 1964 she began her graduate studies in the Department of Anatomy, Loyola University Stritch School of Medicine, Chicago, Illinois. She was awarded the degree of Master of Science in June, 1967. She was a Graduate Student Teaching Assistant in Anatomy from 1965 to 1967.

ACKNOWLEDGEMENT

To Dr. Lincoln V. Domm, Professor of Anatomy and Chairman of the Department of Anatomy, who suggested the problem and under whose guidance and support this investigation was conducted, I wish to express my sincere appreciation and gratitude for his untiring counsel. The experience of working with Dr. Domm on this research project has been a valuable and enriching part of my graduate student experience.

I also wish to extend my appreciation to the members of the faculty of the Department of Anatomy, especially to Dr. Leslie A. Emmert for his counsel on some of the techniques employed and assistance in the interpretation of results.

The constant encouragement of my husband, Francis, and of my parents for their unending help and loyal support have made possible the completion of this program.

The study was supported in part by USPHS., NIH, Research Grant DE - 00694, and a USPHS., NIH, General Research Support Grant. Grants administered by Dr. Lincoln V. Domm.

TABLE OF CONTENTS

	Page
INTRODUCTION.....	14
LITERATURE REVIEW.....	45
MATERIALS AND METHODS.....	11
OBSERVATIONS.....	15
BODY WEIGHT.....	157
INCISOR ERUPTION.....	16
KERATIN EPITHELIAL RATIO.....	16
NATURE OF KERATIN LAYER.....	18
STRATUM MUCOSUM.....	18
GLYCOGEN DEPOSITION.....	20
ALKALINE PHOSPHATASE DEPOSITION.....	21
DISCUSSION.....	22
SUMMARY AND CONCLUSIONS.....	29
LITERATURE CITED.....	31
TABLES.....	34
FIGURES AND PLATES.....	40

LIST OF TABLES

Table	Page
1. SUMMARY OF EXPERIMENTS.....	34
2. WEIGHT CHART.....	35
3. AVERAGE THICKNESS OF KERATIN AND EPITHELIUM IN MUCOSA OF HARD PALATE.....	36
4. AVERAGE THICKNESS OF KERATIN AND EPITHELIUM IN MUCOSA OF GINGIVA.....	37
5. AVERAGE KERATIN EPITHELIAL RATIO IN MUCOSA OF HARD PALATE.....	38
6. AVERAGE KERATIN EPITHELIAL RATIO IN MUCOSA OF GINGIVA.....	39

LIST OF FIGURES

Figure	Page
1. GRAPH SHOWING THE EFFECT OF CORTISONE INJECTIONS ON BODY WEIGHT OF YOUNG POSTNATAL RATS.....	40
2. GRAPH SHOWING GAIN OR LOSS IN BODY WEIGHT OF YOUNG POSTNATAL CONTROL RATS.....	41
3. GRAPH SHOWING THE EFFECT OF CORTISONE INJECTIONS ON THE THICKNESS OF THE STRATUM CORNEUM AND STRATUM MUCOSUM IN HARD PALATE OF YOUNG RATS.....	42
4. GRAPH SHOWING THE THICKNESS OF THE STRATUM CORNEUM AND STRATUM MUCOSUM IN HARD PALATE OF CONTROL RATS.....	43
5. GRAPH SHOWING THE EFFECT OF CORTISONE INJECTIONS ON THE THICKNESS OF THE STRATUM CORNEUM AND STRATUM MUCOSUM IN GINGIVA OF YOUNG RATS.....	44
6. GRAPH SHOWING THE THICKNESS OF THE STRATUM CORNEUM AND STRATUM MUCOSUM IN GINGIVA OF CONTROL RATS.....	45
7. MICROSCOPIC SECTION OF PALATAL ORAL EPITHELIUM OF A NORMAL POSTNATAL RAT AGE 14 DAYS.....	46
8. MICROSCOPIC SECTION OF PALATAL ORAL EPITHELIUM OF A POSTNATAL RAT AGE 14 DAYS WHICH HAD RECEIVED 2 DAILY INJECTIONS OF CORTISONE FOR 3 DAYS.....	46
9. MICROSCOPIC SECTION OF PALATAL ORAL EPITHELIUM OF A NORMAL POSTNATAL RAT AGE 15 DAYS.....	47
10. MICROSCOPIC SECTION OF PALATAL ORAL EPITHELIUM OF A POSTNATAL RAT AGE 15 DAYS WHICH HAD RECEIVED 2 DAILY INJECTIONS OF CORTISONE FOR 4 DAYS.....	47
11. MICROSCOPIC SECTION OF PALATAL ORAL EPITHELIUM OF A NORMAL POSTNATAL RAT AGE 5 DAYS.....	48
12. MICROSCOPIC SECTION OF PALATAL ORAL EPITHELIUM OF A POSTNATAL RAT AGE 5 DAYS WHICH HAD RECEIVED 1 INJECTION OF CORTISONE.....	48

Figure

Page

13.	MICROSCOPIC SECTION OF PALATAL ORAL EPITHELIUM OF A NORMAL POSTNATAL RAT AGE 7 DAYS.....	49
14.	MICROSCOPIC SECTION OF PALATAL ORAL EPITHELIUM OF A POSTNATAL RAT AGE 7 DAYS WHICH HAD RECEIVED 1 INJECTION OF CORTISONE.....	49
15.	MICROSCOPIC SECTION OF PALATAL ORAL EPITHELIUM OF A NORMAL POSTNATAL RAT AGE 10 DAYS.....	50
16.	MICROSCOPIC SECTION OF PALATAL ORAL EPITHELIUM OF A POSTNATAL RAT AGE 10 DAYS WHICH HAD RECEIVED 4 INJECTIONS OF CORTISONE OVER A 2 DAY PERIOD.....	50
17.	MICROSCOPIC SECTION OF GINGIVAL ORAL EPITHELIUM OF A NORMAL POSTNATAL RAT AGE 14 DAYS.....	51
18.	MICROSCOPIC SECTION OF GINGIVAL ORAL EPITHELIUM OF A POSTNATAL RAT AGE 14 DAYS WHICH HAD RECEIVED 2 DAILY INJECTIONS OF CORTISONE FOR 3 DAYS.....	51

ABSTRACT

The purpose of this investigation was to determine whether the precocious eruption of incisors, observed in cortisone-treated newborn rats, is brought about or facilitated by the shrinkage of gums, due to an increased keratinization of the gingival mucosa, or if cortisone acts in some other way to bring about a premature eruption.

Rats of two age groups were used in these experiments; In the younger group the initial injection of cortisone was administered on the third, fourth, fifth, sixth or seventh day postnatally. These received a total of from 0.5 to 1.5 mg. In the older age group, the initial injection was administered on days 8 to 13 postnatally. This group received total dosages ranging from 2.0 to 8.0 mg. The intervals from initiation to termination of individual experiments also varied in both groups. The effects observed were determined by the dose administered and the age at which injections were given.

Cortisone-treated animals in all cases showed an increased degree of keratinization when compared with their litter mate controls. The most significant increases were observed in the older groups which had received the larger dosages of cortisone.

While the stratum corneum of the oral mucosa increased in thickness in cortisone-treated animals, the underlying non-keratinized layer of the epithelium decreased. The ratio of the stratum corneum to the stratum mucosum was greater in treated animals. This was true for palatal as well as gingival tissues.

Weight retardation or actual loss of weight occurred in all experimental rats. In the older animals, the weight gains in controls far surpassed those of the treated. There were only slight increases in the weight of these treated animals. In the younger rats there was an actual loss of weight in treated animals, i.e., these weighed less at the end of the experiment than at its initiation.

The incisors of cortisone-treated rats in all cases showed a greater advance in eruption than their corresponding litter mate controls.

The character of the keratinized layer in treated rats generally was less dense and frequently more fragmented as compared to the more compact nature of this layer in the controls. Glycogen deposition was much less pronounced in the cortisone-treated rats than in the control animals. There was no evidence of alkaline phosphatase activity in any of our animals.

Our results have shown that the administration of cortisone in young postnatal rats causes a shrinkage of the gingiva and an increase in keratinization of the gingival mucosa thereby decreasing the depth of tissue through which the tooth must travel before erupting into the oral cavity.

INTRODUCTION

The effect of cortisone on tooth eruption has interested a number of investigators in recent years. While it has been shown that cortisone-treated rats show premature eruption of the incisors, the mode of action or the factors involved in this process are not so clearly understood.

The purpose of this investigation was to determine whether precocious eruption is brought about or facilitated by gum shrinkage, caused by an increase in keratinization resulting from cortisone treatment, or if cortisone acts in some other way to bring about eruption prematurely.

Cortisone has been found to have pronounced effects on young postnatal rats (Parmer, Katonak, and Angrist, 1951, and others). One of the most frequent effects observed is its action as a growth inhibitor. And yet it has also been found to act as a potent stimulus for the eruption of teeth.

The experiments performed during this investigation focused mainly on the histology of the oral mucosa in the rat, which is everywhere lined by a keratinized epithelium, with special attention being given to the keratinized or cornified layer of the hard palate. Our study was made with the purpose

of correlating changes in the degree of keratinization in treated and control rats with the rate of eruption of the incisors.

Since the process of keratinization was the principal point of interest in this investigation, the presence of keratin granules in the epithelial layer of the oral mucosa was treated as an important phase of the study. The primary reason for interest in this area arose from the work in electron microscopy by Laden, Gerthner, and Erickson (1957); and Matoltsy and Parakkal (1965) which showed that the contents of the granules spread over the cell surface, forming a thickened, coated cell envelope which resists the action of keratinolytic agents. This membrane coating granule is regarded by these authors as a specific differentiation product of the keratinizing epithelium. It was seen to contain numerous inner membranes and is assumed to engage in synthetic activities, such as, perhaps the formation of polysaccharides. The work of Mar-Yohana (1957) showed that there was an increase in the number of granules in the epithelial layer of the oral mucosa in cortisone-treated rats and that this was associated with a decrease in the rate of desquamation or an increase in the formation of keratinized cells.

"Keratinization is a specific form of cell differentiation in which metabolically highly active epithelial cells pass through various cytomorphic and physiologic changes while they

reach the terminal stage and become filled with a resistant and considerably soluble horny material. In initiation and maintenance of the process, the entire tissue is involved; exogenous factors such as dermal effects, vitamins, and hormones also seem to play an important role. Most important phase of the keratinization process is the production of differentiation products and their utilization in formation of the terminal horny material. It is characteristic of all keratinizing epithelia that they are built up of three different cell types, namely, germinative, specialized and terminal horny cells" (Matoltsy, 1960).

A number of theories have been proposed to account for the process of tooth eruption. These vary as significantly as the work done by Constant (1900) who postulated that blood pressure played a role in eruption to the theory proposed by Goldsmith and Ross (1954) who believed that eruption was due to an acceleration in growth of the facial bones.

By means of a study on keratinization, we undertook to investigate the possibility that precocious eruption is in some manner associated with the fact that cortisone affects the epithelial and connective tissue layers of the oral mucosa, by causing a shrinkage, which may be due to excessive keratinization, and that this in turn is responsible for the precocious eruption of the incisors observed in cortisone-treated rats.

LITERATURE REVIEW

Parmer, Katonak, and Angrist (1951) reported that cortisone has a pronounced effect on the development of young post-natal rats. Their investigations have shown that newborn rats are markedly sensitive to cortisone as compared to other adrenal hormones studied. Their findings show that this hormone stimulates the eruption of teeth, the opening of the eyelids, and the development of the gingiva. The younger the rat at the time of the first injection, the more marked was the effect observed. Cortisone-treated rats were found to be more susceptible to infection, as judged by the occurrence of subcutaneous infections at injection sites. The growth of hair was also retarded according to these investigators. Some of the treated animals even consumed more food than the controls, but were still underweight. When cortisone was administered in the amount of 2.5 mg daily for four days beginning on the tenth or eleventh day to pregnant rats and mice, there was a reduction in litter size and in the weight of the newborns (Goldby and Harrison, 1961). Domm and Leroy (1955) also reported significant results in young rats following cortisone treatment. Their experiments were performed on rats in

the latter half of pregnancy, on fetuses and on postnatal rats. Even though the mode of action was not determined, they definitely showed that there was a precocious eruption of the incisors in postnatal cortisone-treated rats.

Berlin, Johnson, Hawk and Lawrence (1952) found that prolonged cortisone treatment in mice resulted in the occurrence of bacteremia and death. A progressive decrease in weight and a decrease in spleen size to one-half or less that of the controls also occurred.

Since the epithelium of the hard palate is bound to a dense connective tissue, Asboe-Hansen (1952) thought it significant that Fibroblasts, located in the connective tissue layer, were smaller and more pyknic in healing wounds of cortisone-treated individuals (humans). This investigator also found that the mast cells of dermal connective tissue decreased in number and became degranulated when exposed to the action of cortisone. Vacuolization occurred and changes were noticed in the number and distribution of the granules. The form and outlines of the cells also varied. Michael and Whorton (1951) used croton oil and trauma to induce inflammation in the study of certain bacterial infections in mice. The inflammatory response involved the migration of leukocytes and the formation of edema and fibrin. It was found

that the inflammatory response was less intense in cortisone-treated mice than in controls. This reaction in the treated animals was delayed and reduced and the total number of cells was also reduced.

The oral histologist, according to Butcher and Sognnaes (1962), has not studied the oral cavity of the rodent, which they say is everywhere lined by keratinized epithelium. A relationship was observed to exist between keratinization and glycogen, the latter frequently being deposited in the gingival epithelium. Complete keratinization is rare in the presence of either glycogen or inflammation and does not occur at all when inflammation is severe or when glycogen is present in large quantities (Butcher and Sognnaes, 1962). In the rodent the use of hematoxylin stains showed the entire oral epithelium to be keratinized and uniformly stained throughout (Butcher and Sognnaes, 1962). Weinmann, Meyer and Medak (1960) correlated differences in granular and keratinous layers in the oral mucosa of the mouse. It appeared that differences in the keratin were related to the differences in keratohyaline granule formation. In the palate the keratin layer was more strongly positive for sulfhydryl groups, than the cellular layers, and in the cheek it was less positive.

The work of Matoltzy and Parakkal (1965) reported that

small cytoplasmic granules (1000-5000Å) develop within differentiating epithelial cells, move toward the periphery of the cell, and after fusion empty their contents into the intercellular spaces. The contents of the granules was observed to spread over the cell surfaces forming a thickened, coated, cell envelope which resisted the action of keratinolytic agents. The membrane coating granule is regarded as a specific product of keratinizing epithelia. Chemical studies have shown the envelope to consist of a variety of common amino acids. The shape and inner structure of these granules can be seen most clearly in the oral and tongue epithelium of the mouse (Matoltsy and Parakkal, 1965).

Zelickson (1961) made a comparison of normal keratinizing and non-keratinizing epithelia in mice. The skin and oral mucosa were fixed, embedded and stained with the following results. The horny cell was shown to be formed by a binding together of filaments in an electron dense, sulfur containing cement substance. Filaments were present in the basal layer which gradually increased in diameter as the cell neared the surface. Keratohyalin was laid down and bound the filaments together thus forming compact bundles. It was found that the diameter of the tonofilaments increased as they moved toward the surface.

Montagna (1964) showed that there was a resistance of keratins and proteins to proteolytic enzymes and to acid and alkaline hydrolysis in mammals. Both the proliferation of epidermal cells and the shedding of horny cells were found to be accelerated by thyroid hormone and retarded by adrenal cortical steroids. This investigator postulates the presence of a tissue-specific, local hormone which inhibits mitosis; thus, the thickness is regulated by a fine regulatory mechanism which determines whether the newly formed cell in the basal layer will divide mitotically or will differentiate into a horny cell and be shed as a single cell. When the concentration of this hormone is low, the cells produce proteins promoting mitosis; when it is high the cells differentiate. Rothman (1954) reported the presence of alkaline phosphatase and glycogen in the transitional layer of the epidermis clearly outside the granules in human skin. Both glycogen and alkaline phosphatase are absent in the horny layer and in other horny materials. These findings again point to the possible role of glycogen as a source of energy in keratinization. He observed that as cells start to keratinize, they lose their glycogen and that all glycogen is used up by the time keratinization is complete. Cytoplasmic proteins are transformed into keratin fibers. Complete disintegration of

the keratinizing cell, including cytoplasm and nucleus, occurs. Depressed mitotic activity, observed by Rothman (1954), involves a decreased rate of keratinization.

Butcher and Klingsberg (1962) reported a definite significance of glycogen in the wound healing of the oral mucosa of the rat. Wounds were made in the midline between the two most anterior rugae of the palate. Glycogen content was determined by fixing biopsies in an alcoholic-acetic-formalin solution and staining by the PAS method using diastase. They found that epithelial growth was associated with glycogen disappearance and that injury to the epithelium brought about an accumulation of glycogen.

Jarrett, Spearman, Riley and Cane (1965) reported that the chief function of the alkaline phosphatase of the granular layer, which is capable of utilizing lecithin as a substrate, is probably the removal of the phospholipids from the granular layer during normal keratinization. They believe that alkaline phosphatase may be related to the deposition of mineral salts in keratin. Hence, the alkaline phosphatase would release phosphate ions in the region of the granular layer which would precipitate any calcium present in this site. In parakeratotic human oral epithelium in which keratohyaline

granules are absent, no phosphatases were found and the phospholipids were not broken down. By microbiological methods it was shown that keratinization is connected with hydrolytic decomposition of choline-containing phospholipids (Frithiof, Lars and Wersall, 1965).

MATERIALS AND METHODS

Albino rats of the Sprague-Dawley strain¹ were used in these experiments. Since rats of a very young age were the subjects of this investigation, the pregnant mother was watched carefully and acclimated as much as possible to the new laboratory conditions. The best results were obtained when the young litters were left alone as much as possible.

The rats varied from three to eleven days in age when the first injection was given. A careful account of weights was kept, weighing each rat before the injection(s) and prior to sacrifice. Exsanguination was by decapitation without the use of an anesthetic. The anterior region of the hard palate was always examined, when the animals were handled, for possible incisor eruption. The gum region in the area of the lower incisors was also examined and the observations recorded.

The cortisone² (Cortone acetate) was injected subcutaneously in all treated animals, while an equal volume of

¹Purchased from the Hormone Assay Laboratories, Inc., Chicago, Illinois.

²The Cortisone, (Cortone acetate) was generously supplied to Dr. L. V. Domm by Sharpe and Dohme, Division of Merck and Company, Philadelphia, Pa.

distilled water was similarly injected in the control animals. The cortisone was a saline suspension containing 25 mg/cc. A quarter cc capacity syringe, scale 1/100 cc, was used with a number twenty-six needle. For purposes of identification various body areas of the cortisone-treated animals were marked with gentian violet and the controls with picric acid.

After decapitation the oral mucosa of the hard palate was dissected free and in some instances also the gingiva. The tissues to be stained for glycogen were placed in a 10% formalin solution, while those to be stained for alkaline phosphatase were placed into 80% cold alcohol. These tissues were also fixed in the same manner for a histological study of keratin. In some instances the palate was divided in half and one part fixed for glycogen and the other for alkaline phosphatase. A low melting point paraffin (53° - 55°) was used for embedding. All sections were cut at 7 μ . unless otherwise stated.

A simple and effective procedure was used for staining keratin which in some instances even showed the fibrillar nature of the protein and the presence of keratohyaline granules. This consisted of passing the sections from xylene through water into hematoxylin and eosin y. The keratinized tissues were stained by this procedure.

The PAS reaction was employed to demonstrate the presence of glycogen. This was accomplished by passing paraffin embedded sections through xylene and the alcohol series, followed by an oxidation step in a 1% periodic acid solution and treatment with Schiff's reagent. The method used was that outlined by Lillie (1954). If glycogen is present, it will stain red. Harris hematoxylin was used as a counterstain. A control slide plus an experimental slide were prepared simultaneously with the control slide being digested in malt diastase in order to free the section of glycogen. This was done to digest the glycogen so as to simplify the identification of glycogen by retained color on the experimental slide. A 0.5% diastase was used to incubate the controls at 37° C for one hour after the sections had been passed from xylene through alcohols to water.

Gomori's method (Lillie, 1954) was utilized in staining for alkaline phosphatase. Tissues were fixed in 80% cold alcohol for at least twenty-four hours. Because of the minute dimensions of these tissues at this early age, forty-eight to fifty hours was the maximum time for fixation. The tissues were incubated for two hours in a sodium glycerophosphate substrate at a pH of 9.4-9.5. If alkaline phosphatase was present, a blackish precipitate appeared. Eosin B was used as

a counterstain. In this procedure a control slide was also passed through an inactivating substrate.

In general the investigative procedures may be divided into two groups: one in which a single injection was administered and one in which more than one injection was given.

On the day of sacrifice, the erupting incisors were examined and the observations recorded. Results were tabulated by the following symbols: a plus (+) if eruption had occurred, a minus (-) if no eruption had occurred, and greater (>), or less than (<), the latter denoting whether degree of eruption in cortisone-treated animals was greater or less than in the corresponding control litter mates.

The data given in tables 5 and 6 were obtained as follows: measurements were made under high power magnification of the keratin layer and the underlying non-keratinized layer of the epithelium in all animals. Fractions of the form K/Epi (Keratin/Non-keratinized layer) were multiplied by $X/100$ to set all ratios to a common base. The ratios, thus obtained, were added and their sum divided by the number of animals in the experimental group. This was done on all slides of treated and control animals. All measurements were made by use of an ocular micrometer divided into 200 units.

OBSERVATIONS

Since we were interested in factors responsible for the precocious eruption of the incisors observed in cortisone-treated postnatal rats, our study focused on the keratinization process of the oral epithelium in the hope that it might shed new light on the problem of eruption. Keratin, an insoluble protein (White, Handler and Smith, 1954), forms the outermost layer of the oral mucosa in the albino rat, as well as in other rodents. It was the purpose of this investigation, therefore, to study the effect of cortisone on this insoluble protein, which is formed exclusively by the epithelial cells, and its relation to the process of eruption of the incisor.

Body Weight

As shown in table 2, there was a noticeable effect on weight in all treated animals. In most instances this involved an actual loss of weight as compared to a weight gain in control animals as shown in figures 1 and 2. Examination of these figures will show that the keratin increases in thickness with increased dosages of cortisone and the weight of the rat was either retarded in relation to the corresponding controls or there was an actual loss of weight in the treated animal; i.e., they weighed less at the time of sacrifice than at the

initiation of the experiment. The most significant results were found in the older age groups which had received larger dosages over a longer period of time. Nonetheless, a loss in weight was consistently observed in the younger rats.

The ages at which cortisone treatment was begun was an important factor in our results as was the number of injections administered. When single injections of 1.5, 1.0, and 0.5 were administered to rats of 4 days (Exps. 11, 12, 13) the weight losses increased as the dosage injected was increased. Those rats receiving 1.5 mg lost an average of 1.3 mg, those receiving 1.0 mg lost 1.2 mg, and those receiving 0.5 mg lost 0.3 mg respectively.

Incisor Eruption

Our results concerning precocious eruption confirm those of previous investigators, since in all cases the incisors of cortisone-treated animals showed a greater degree of eruption than the control litter mates. In the youngest animals, 3 and 4 days of age when initially injected, these observations were made simply by examining the overlying gingiva for breakage or punctures from the erupting tooth while in the older ones macroscopic examination of the gingiva revealed whether or not eruption had occurred.

Keratin Epithelial Ratio

Cortisone, a corticosteroid produced by the adrenal

glands, appears to have had an effect on the degree of keratinization in the oral mucosa (tables 3, 4). This is believed to have a direct relationship to the thickness of the non-keratinized epithelial layer of the mucosa (figs. 13, 14, 17, 18).

Since the keratinized cells are formed solely from epithelium, the ratio of the stratum corneum to the stratum mucosum is significant in our work. In practically all of our experiments the ratio of keratin to epithelium was considerably greater in the controls than in the treated animals. As seen in figures 3 and 5, as the keratin/epithelial ratio increases the thickness of the keratin layer increases. This result would appear to be in accordance with Montagna (1964) who reported that keratin cells are produced from epithelium. The plot of control findings on the corresponding graphs are steadier suggesting that cortisone does cause an increased production of keratin in treated animals.

The most significant results concerning ratios were observed in rats ranging from eight to eleven days in age at the time injections were begun. These injections varied from a total of 2.0 to 8.0 mg (table 1). The higher ratios (46, 40, 43, 60) were seen in palatal epithelium of experiments 1 to 4, (figs. 7, 8, 9, 10). At the age of seven days postnatally ratios obtained from experimental animals were considerably less and remained so subsequently as seen in experiments 5 to

14, (tables 5, 6). Rats in the younger groups did not receive such large dosages because the effects of short term, single injections were also of interest.

Nature of Keratin Layer

Since it was the purpose of our study to investigate the possibility of cortisone causing gum shrinkage and, if so, its effect on precocious eruption, differences in the keratin layer of treated animals as opposed to the control animals were studied. The oral mucosa of the cortisone-treated rats was fragmented in some cases, i.e., the cornified outer layer was not smooth as was the case in the control rats. Since the fragmented condition was not always seen in cortisone-treated animals, this could conceivably be an artifact. The age of the rats did not seem to be a factor in this particular result. The results clearly indicate that cortisone has a pronounced effect on the character of the oral mucosa of the albino rat since in most cases the keratinized layer in the treated animals was not as compact as in the corresponding controls.

Stratum Mucosum

Since keratinized cells are formed solely by epithelium (Montagna, 1964), the effect of cortisone administration on the entire epithelial layer was also of significance. As indicated above the thickness of the stratum mucosum was reduced in cortisone-treated animals. This effect is correlated with an

increase in the thickness of the keratin layer as well as an increase in the degree of granulation in the upper epithelial cells, i.e., cells of the stratum granulosum. These granules were seen to vary considerably in size (figs. 7, 8).

As stated above, measurements were made on the keratin and epithelial layers of the palatal and gingival mucosae. Results are given in tables 3 and 4. Figures 3, 4, 5, 6 show the relationship between the thickness of the epithelium and the keratin in treated and control animals. In all instances the average thickness of the keratin in treated groups was greater than that of the corresponding controls (figs. 15, 16). The epithelium was found to be thicker in treated animals suggesting that the epithelial cells have probably been stimulated to proliferate as a result of cortisone treatment. Nonetheless, the ratios were greater in control animals.

Figures 1 and 2 show the relationship between keratin thickness and weight variations in control and treated animals. As stated above there was always a loss or a retardation in the weight of treated animals with a corresponding increase in keratin.

It was not possible to determine through these procedures whether the increase in keratin was due to an increase in the rate of formation of keratinized cells or a decrease in the rate of desquamation. However, since there was always a

concomitant decrease in thickness of the underlying epithelial layer it seems logical to assume that the former is the case even though we have no evidence to rule out the latter.

In either case the result would obviously be a thicker keratinized layer.

Glycogen Deposition

Our study was also concerned with a possible correlation between glycogen deposition and the degree of keratinization following cortisone administration. It should be noted that significantly greater amounts of glycogen were always found in the controls than in the treated animals. The PAS method was used for these determinations.

In animals of 11 days (older age group), receiving a total of 6.0 to 8.0 mg over a three or four day period, traces of glycogen were found. However, these amounts, when compared with those found in the controls, were insignificant. It is also of interest to note that the same condition was seen to exist in the gingiva, but to a greater degree: very little glycogen in treated and a considerable amount in controls. In some cases it was very difficult to determine the occurrence of glycogen in treated animals showing significant amount of keratin.

It is of interest to note that rats injected at seven days of age, receiving two 0.5 mg injections, or a total of

1.0 mg of cortisone per day and killed 24 hours later, showed an increase in the amount of glycogen in the epithelial layer of the palatal and gingival mucosae.

Rats receiving a single injection of 1.0 mg of cortisone on the fourth day and sacrificed twenty-four hours later showed results comparable to those observed in older rats having undergone longer treatments, i.e., treated animals showed a noticeably smaller amount of glycogen than their litter mate controls.

Alkaline Phosphatase Deposition

Epithelial tissues of the palatal and gingival mucosae were also stained for the presence of alkaline phosphatase. Our study showed no evidence of this enzyme in any of these tissues. Age could be the factor for this apparent absence of alkaline phosphatase since it was not present in the uterine epithelium of young postnatal rats of 10 days (Pritchard, 1948).

DISCUSSION

The mucosa of the hard palate and gingiva was studied in our investigation, particular attention being given to the keratinized covering of this tissue. All cavities and canals of the body that connect with the exterior are lined by a mucous membrane possessing the same general structural pattern: this consists of a surface epithelium having a moist surface, a basement membrane, and a stratum of connective tissue, the lamina propria (Copenhaver, 1964). Mucous glands need not necessarily be present. The oral cavity is lined throughout by a mucous membrane, except over the teeth, bearing a stratified squamous epithelium and having a rather dense lamina propria. A submucosa exists in the palate except in the midline raphe and near the gum. There are neither glands nor a submucosa in the gingiva.

In the albino rat and other rodents the oral mucous membrane, or mucosa, is covered by a cornified, keratinized layer produced from the underlying epithelial layer. Our study concerned the tissue of the anterior portion of the hard palate because we were interested in studying the possible relationship between the process of keratinization and the precocious eruption of the incisors. The hard palate furnishes a roof,

separating the mouth from the nasal passages and nasopharynx. The oral side bears the above described keratinized mucosa, whereas, the nasal side bears the respiratory or pseudo-stratified ciliated type (Arey, 1963). The squamous epithelium of the palate is indented with tall vascular papillae extending from a densely fibrous lamina propria. Between the two mucosae there exists a middle lamina of bone, or muscle if considering the soft palate. It was our purpose to study the keratinized palatal mucosa since we were interested in the effect of cortisone on this tissue when precocious eruption of the incisors occurred.

Our findings confirm the results of Berlin, Gerthner, and Erickson (1957) who reported a weight retardation in cortisone-treated rats. The rats in our older age group, the group in which injections were begun on the eleventh day, did gain weight, but this gain was not of the same magnitude as that observed in the control animals. Rats in the younger age bracket did show a definite loss in weight even though most of these experiments lasted for a shorter period of time. The reason for this loss of weight in cortisone-treated animals was not, however, the purpose of our investigation so we will not concern ourselves with an explanation for its occurrence. However, if cortisone causes gum shrinkage and flaking as observed in many of our treated animals, this might have some-

thing to do with the animals' eating habits as well as with other variables such as the metabolic effect of cortisone. Our observations concerning the weight variance as reported in table 2 are also in agreement with the findings of Berlin, Johnson, Hawk and Lawrence (1952) who noticed a marked and progressive decrease in the weight of cortisone-treated animals, especially in young postnatal rats.

The keratinization process is not an all-or-none process as was once thought, since it occurs in varying degrees in different epithelia. "Parakeratosis" as defined by Weinmann, Meyer and Medak (1960), full keratinization of the cytoplasm but persistence of nuclear remnants, does not occur in the mouse, nor are any unkeratinized regions present in the oral mucosa of the mouse, according to Butcher and Sognnaes (1962). Hematoxylin and eosin preparations of the oral mucosa in our experiments showed a uniformly stained keratinized layer. In rodents it has been found that the turnover rate of cells in the palate is less than that of buccal tissues. This further substantiates the fact according to Arey (1963) that in the palate the keratinization process is carried to completeness.

A definite increase in thickness of the keratinized layer of the oral mucosa in cortisone-treated animals was evident in most of our experiments (tables 3, 4). The most noticeable increases were seen in the older animals which had

undergone longer cortisone treatment, but an increase was also noted in younger animals receiving smaller dosages for shorter periods of time. The fact that there were some animals who did not show the increased degree of keratinization generally observed in our rats may suggest a variation in individual susceptibility to this hormone.

The main purpose of our investigation was to study the effect of cortisone on the process of keratinization of the oral mucosa, in order to determine whether cortisone caused an increase in the degree of keratinization of this tissue and, if so, did it facilitate eruption. Our finding, as shown in tables 3 and 4, indicates that cortisone-treated animals did show an increase in thickness of the keratin layer of the oral mucosa. These results would seem to indicate that a combination of factors were responsible for precocious eruption of incisors in cortisone-treated rats as reported by Domm and Leroy (1955) and others. Our experiments have also shown that cortisone treatment causes premature eruption of incisors even in rats injected with a single 0.5 mg dose of cortisone on the 4th day and sacrificed on the 5th.

Parmer, Katonak and Angrist (1951) reported that cortisone stimulated the eruption of teeth and the opening of the eyelids. They observed that the younger the animal at the time the injections began, and the higher the dose, the more marked

was the growth failure and the more dehydrated the rat became. Fell (1962) reported in his studies on tissue cultures of skin explants of chick and rat embryos (Weissmann and Fell, 1962) that the addition of hydrocortisone to the culture medium hastened keratinization. The amount of keratin finally produced, however, was usually no greater than in the untreated controls and the cells were seen to be smaller.

We observed an increase in degree of granulation in the epithelial layer of our experimental animals. The electron microscope has given information concerning the nature of the keratinization process, especially its chemical aspects. In such studies DeBersaques and Rothman (1962) reported that these granules seem to be in the lower most border of the keratin, which is thought to be formed from proteins, and that they appear to be transforming directly into keratin fibers. Laden, Gerthner, and Erickson (1957) found these granules to be present exclusively in keratinizing epithelium. The more developed the granules, the stronger and harder was the resulting keratin. They reported that when cornification stops, as occurs in Vitamin A deficiency or under the influence of estrogenic hormones, keratohyaline granules are not seen; yet, when the epithelium regains its cornifying potentiality, the granules reappear.

The keratohyaline granules of the palatal epithelium of

rats are formed in a compact layer of squamous cells following many layers of spinous cells (Rothman, 1954). They vary considerably in size. Intercellular spaces, progressive flattening of cells between the basal layer and the stratum corneum, are characteristic of palatal epithelium. The fibrillar as well as the eleidin precursors of keratin are distinctly elaborated in the palate (Butcher and Sognnaes, 1962).

Our results showed a noticeably higher glycogen content in control animals as opposed to those having undergone cortisone treatment. Similar findings were reported by Weinmann, Meyer, Mardfin and Weiss (1959) who observed an increase in glycogen deposition in the course of inflammatory and reparative processes. These investigators also concluded that epithelia which keratinize do not contain significant amounts of glycogen, whereas those that do not, contain large amounts. It was also suggested that the presence of glycogen in the alveolar mucosa may have a structural function in maintaining the integrity of the cells. Therefore, when a significant amount of glycogen is noted, it suggests that keratinization is not so severe.

Rothman (1954) reported that the presence of alkaline phosphatase and glycogen in the transitional layers of the skin clearly outside the granules is significant. He reports that both glycogen and alkaline phosphatase are absent in the horny

layer of the skin and in other horny materials. These findings again point to the possible role of glycogen as a source of energy utilized in the process of keratinization and explain its absence in epithelia showing pronounced keratinization.

The fact that there was a more compact layer of keratin in most of the control animals than in the treated suggests a direct relationship to precocious eruption, the reason for this being that the layer is less dense (in cortisone-treated animals) which thereby facilitates eruption. Our results showed an increase in degree of keratinization following cortisone administration in the palatal and gingival mucosae.

SUMMARY AND CONCLUSIONS

Rats of two age groups were used in these experiments. In those of the younger group the initial injection was administered on the third, fourth, fifth, sixth and seventh days post-natally. These received a total of from 0.5 mg to 1.5 mg. The older group comprised those animals ranging in age from eight to ten days when experiments were begun. This group received total dosages of 2.0 to 8.0 mg. The intervals from initiation to termination of individual experiments varied in both groups as shown in table 1.

The effects of cortisone depended on the administered dose as well as the age at which injections were given.

Weight retardation or actual loss of weight occurred in all experiments. In older animals the weight gains in controls far surpassed those of the treated animals. In younger animals there was an actual loss of weight in treated animals since they weighed less at the end of the experiment than at initiation.

Cortisone-treated animals showed an increased degree of keratinization as compared to their litter mate controls. The most significant increases were observed in older rats who had received the larger doses of cortisone.

The thickness of the stratum corneum of the oral mucosa increased in cortisone-treated animals, while the underlying

non-keratinized layer of the epithelium decreased in thickness.

The ratio of the stratum corneum to the stratum mucosum was greater in treated animals. This was true for palatal as well as gingival tissues.

Glycogen deposition in the non-keratinized layer of the control animals was greater than in the treated animals.

No evidence of alkaline phosphatase activity was noted in either control or treated animals in ages studied.

These results clearly indicate that cortisone administration causes an increase in degree of keratinization and a decrease in the thickness of the non-keratinized epithelial layer. These conditions indicate that the erupting incisor has a less dense area of stratum corneum through which to travel or erupt in cortisone-treated than in normal rats.

LITERATURE CITED

- Arey, Leslie Brainerd 1963 Human Histology, 2 Edition. W. B. Saunders Company, Philadelphia.
- Asboe-Hansen, G. 1952 The mast cell. Cortisone action on connective tissue. Proc. Soc. Exp. Biol. Med., 80: 677-679.
- Berlin, Byron S., Charles Johnson, Walter D. Hawk and A. Gene Lawrence 1952 The occurrence of bacteremia and death in cortisone-treated mice. J. Lab. Clin. Med., 40: 82-89.
- Butcher, Earl O. and Jules Klingsberg 1962 Glycogen and succinic dehydrogenase in wound healing of the oral mucosa of the rat. Proc. Soc. Exp. Biol. Med., 111: 783-786.
- Butcher, Earl O. and Reidar Sognaes 1962 Fundamentals of Keratinization. Am. Assoc. Adv. Sci. Publ., No. 70, Washington, D. C.
- Constant, T.E. 1900 The eruption of teeth. 3rd Congres Dentaire Internat., Paris, 2: 180:194.
- Copenhaver, Wilfred M. 1964 Bailey's Textbook of Histology, 15 Edition. The Williams & Wilkins Company, Baltimore.
- DeBersaques, J. and Stephen Rothman 1962 Mechanism of keratin formation. Nature, 193: 147-148.
- Dommm, L.V. and Pierre Leroy 1955a Etude sur l'effet de la cortisone sur la croissance des incisors chez le rat nouveaune et le foetus. VIe Congres Federatif. International B'Anatomie, 60-61.
- _____ 1955b New observations on the action of cortisone injected into rats during their pregnancy. Comptes Rendus des Seances de L'Academie des Science, 241: 1514-1516.
- Fell, H.B. 1962 The influence of hydrocortisone on the meta-plastic action of vitamin A on the epidermis of embryonic chicken skin in organ culture. J. Embryol. Exptl. Morphol., 10: 389.

- Frithiof, Lars and Jan Wersall 1965 A highly ordered structure in keratinizing human oral epithelium. J. Ultrastruct. Res., 12: 371-379.
- Goldby, F. and R. J. Harrison 1961 Recent Advances in Anatomy. Little, Brown and Company, Boston.
- Goldsmith, E.D. and L. Ross 1954 A histologic study of the effects of cortisone on the lower incisors of newborn rats. J. Clinical Endo. and Met., 14(7): 824-825.
- Jarrett, A., R.I.C. Spearman, P.A. Riley and A.K. Cane 1965 The distribution of epidermal phospholipids and their relation to the alkaline phosphatase activity of the granular layer. J. Invest. Dermatol., 44: 311-319.
- Laden, E.L., P. Gerthner and J.O. Erickson 1957 Electron microscopic study of keratohyalin in the formation of keratin. J. Invest. Dermatol., 28: 325-327.
- Lille, R.D. 1954 Histopathologic Technic and Practical Histochemistry. The Blakiston Company, Inc., New York.
- Mar-Yohana, Genia 1957 Histological effects of cortisone on the maxillary incisors and associated tissues in the albino rat. M.S. Thesis (unpublished). The Library, Loyola University Stritch School of Medicine, Chicago.
- Matoltsy, A. Gedeon and Paul F. Parakkal 1965 Membrane-coating granules of keratinizing epithelia. J. Cell. Biol., 24: 297-307.
- Michael, Max Jr. and C. Merrill Whorton 1951 Delay of the early inflammatory response by cortisone. Proc. Soc. Exp. Biol. Med., 76: 754-756.
- Montagna, William and W. C. Lobitz, Jr. 1964 The Epidermis. Academic Press, New York.
- Parmer, Leo G., Frances Katonah and Alfred A. Angrist 1951 Comparative effects of ACTH, cortisone, corticosterone, desoxycorticosterone, pregnenolone on growth and development of infant rats. Proc. Soc. Exp. Biol. Med., 77: 215-18.
- Pritchard J.J. 1948a Distribution of alkaline phosphatase in the pregnant uterus of the rat. J. Anat., Lond., 81: 352-64.

1948b Alkaline phosphatase in the uterine epithelium of the rat. J. Anat., Lond., 83: 10-24.

Rothman, Stephen 1954 Physiology and Biochemistry of the Skin. University of Chicago Press, Chicago.

Weinmann, J.P., J. Meyer, Dorothy Mardfin and M. Weiss 1959 Occurrence and role of glycogen in the epithelium of the alveolar mucosa and of the attached gingiva. Am. J. Anat., 104: 381-401.

Weinmann, J.P., J. Meyer and H. Medak 1960 Correlated differences in granular and keratinous layers in the oral mucosa of the mouse. J. Invest. Dermatol., 34: 423-431.

Weissman, G. and H.B. Fell 1962 The effect of hydrocortisone on the response of fetal rat skin in culture to ultra violet irradiation. J. Exptl. Med., 116: 365.

White, Abraham, Philip Handler and Emil Smith 1954 Principles of Biochemistry, 3 Edition. McGraw-Hill Book Company, New York.

Zelickson, Alvin S. 1961 Normal human keratinization processes as demonstrated by electron microscopy. J. Invest. Dermatol., 37: 369-379.

Zelickson, Alvin S. and J. Francis Hartmann 1962 An electron microscope study of normal human non-keratinizing oral mucosa. J. Invest. Dermatol., 38: 99-107.

TABLE I
SUMMARY OF EXPERIMENTS

Exp.	No. C	No. Tr	Age begun dys	Age killed dys	No. of injs	Amt.per inj mg	Tot.amt. of inj mg	Duration exp. dys-hrs
1	2	2	11	14	6	1.0	6.0	3 d
2	1	2	11	15	8	1.0	8.0	4 d
3	0	1	11	13	4	1.0	4.0	2 d
4	4	4	8	10	4	0.5	2.0	2 d
5	5	5	7	8	2	0.5	1.0	1 d
6	2	3	7	7	1	1.0	1.0	7½ h
7	1	2	6	7	1	1.0	1.0	14 h
8	1	1	6	7	1	0.5	0.5	14 h
9	1	3	5	6	1	1.0	1.0	13 h
10	1	3	5	6	1	0.5	0.5	13 h
11	4	5	4	5	1	1.5	1.5	24 h
12	2	2	4	5	1	1.0	1.0	19 h
13	2	4	4	5	1	0.5	0.5	26 h
14	5	5	3	4	1	0.5	0.5	24 h

TABLE II
WEIGHT CHART

Exp.	Age begun dys	Age killed dys	Average wt. gms		Gain or loss in gms		Tot.dose mg
			C	Tr	C	Tr	
			Beg.	End	Beg.	End	
1	11	14	20.3	23.8	18.5	18.8	+3.8 +0.3 6.0
2	11	15	16.6	21.2	19.5	20.3	+4.6 +0.8 8.0
3	11	13	----	----	12.0	12.6	---- +0.6 4.0
4	8	10	19.3	21.9	20.5	19.6	+2.6 -0.9 2.0
5	7	8	14.3	15.7	14.5	14.0	+1.4 -0.5 1.0
6	7	7	8.7	9.0	8.0	8.7	+0.5 +0.7 1.0
7	6	7	12.1	13.5	11.6	11.0	+1.4 -0.6 1.0
8	6	7	11.5	12.3	13.0	13.0	+0.8 0.0 0.5
9	5	6	10.8	11.5	12.9	11.9	+0.7 -1.0 1.0
10	5	6	12.9	13.6	13.0	11.3	+0.7 -1.7 0.5
11	4	5	10.5	11.2	10.8	9.5	+1.0 -1.3 1.5
12	4	5	13.1	14.8	14.3	13.1	+1.7 -1.2 1.0
13	4	5	11.3	13.4	11.8	11.5	+2.1 -0.3 0.5
14	3	4	9.1	10.7	8.9	8.5	+1.6 -0.4 0.5

TABLE III

AVERAGE THICKNESS OF KERATIN AND EPITHELIUM IN PALATAL MUCOSA

Exp.	Age begun in dys	Age killed in dys	Dosage mg	Measured units		Measured units	
				Keratin		Epithelium	
				C	Tr	C	Tr
1	11	14	6.0	33	50	108	120
2	11	15	8.0	10	40	80	100
3	11	13	4.0		60		140
4	8	10	2.0	34	45	145	83
5	7	8	1.0	15	16	75	86
6	7	7	1.0	10	17	105	102
7	6	7	1.0	8	20		100
8	6	7	0.5	10	20	60	120
9	5	6	1.0	5	10	20	53
10	5	6	0.5	10	15	65	67
11	4	5	1.5	6	11	85	85
12	4	5	1.0	10	15	105	110
13	4	5	0.5	11	15	105	118
14	3	4	0.5	7	12	55	115

TABLE IV

AVERAGE THICKNESS OF KERATIN AND EPITHELIUM IN MUCOSA OF GINGIVA

Exp.	Age begun in dys	Age killed in dys	Dosage mg	Measured units		Measured units	
				Keratin		Epithelium	
				C	Tr	C	Tr
1	11	14	6.0	20	20	85	50
3	11	13	4.0		20		160
4	8	10	2.0	45	55	139	100
5	7	8	1.0	25	33	48	84
6	7	7	1.0	5	12	23	53
12	4	5	1.0	9	18	75	40
13	4	5	0.5	15	8	180	80

TABLE V

AVERAGE KERATIN: EPITHELIAL RATIO IN MUCOSA OF HARD PALATE

<u>Experiment</u>	<u>Treated</u>	<u>Control</u>
1	46	31
2	40	13
3	43	
4	60	27
5	21	21
6	29	10
7	20	
8	17	17
9	20	25
10	26	15
11	13	9
12	16	11
13	15	15
14	14	10

TABLE VI

AVERAGE KERATIN:EPITHELIAL RATIO IN MUCOSA OF GINGIVA

Experiment	Treated	Control
1	42	34
3	6	
4	30	19
5	16	25
6	23	20
12	45	14
13	11	8

PLATE 1

EXPLANATION OF FIGURE

- 1 Graph showing the effect of cortisone injections on gain or loss in body weight of young postnatal rats.**

Abbreviations: SC - Stratum corneum (keratinized layer)
SM - Stratum mucosum (non-keratinized layer)
SC + SM - Stratum corneum plus stratum
mucosum

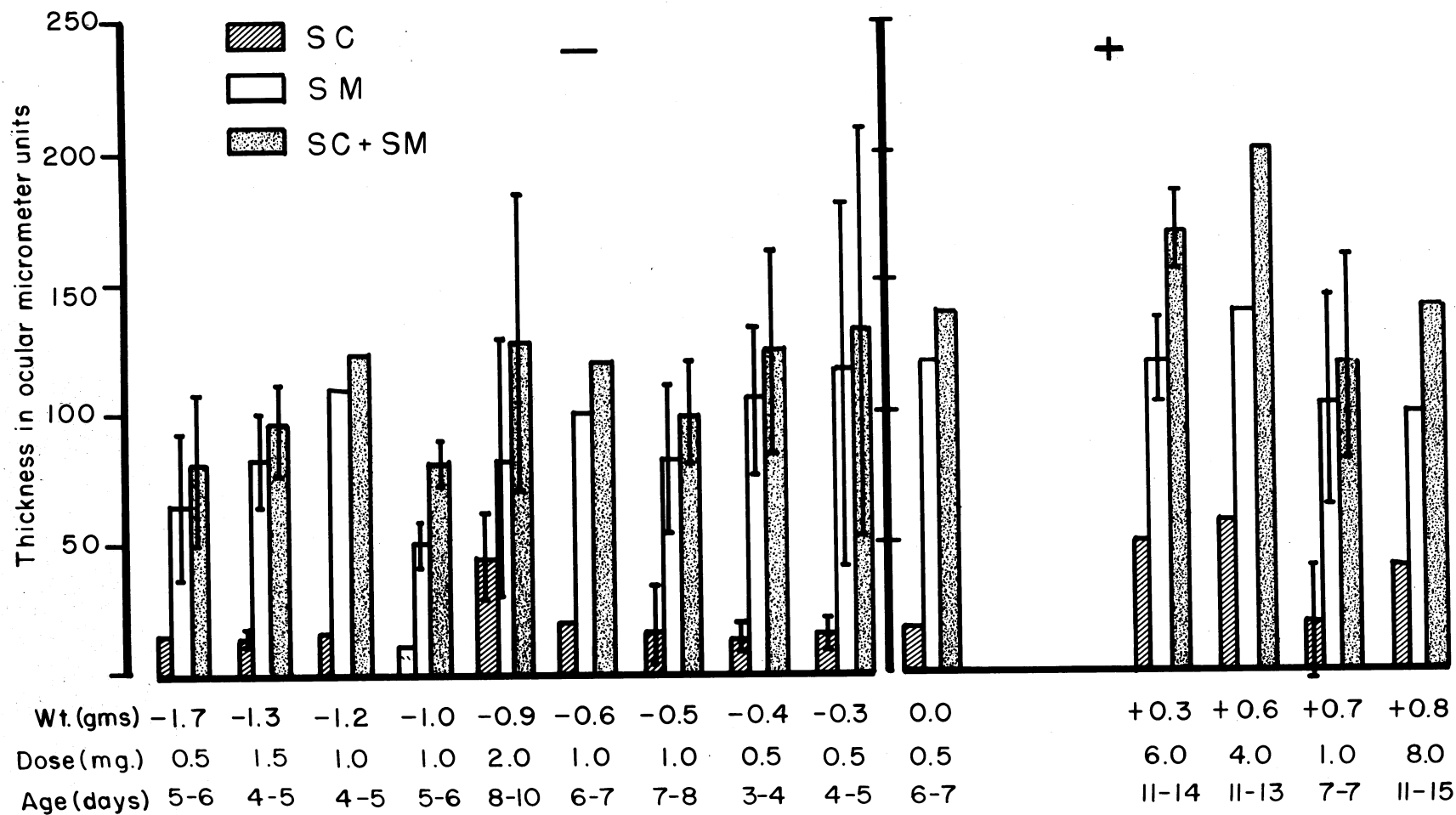


PLATE 2

EXPLANATION OF FIGURE

- 2 Graph showing gain or loss in body weight of young postnatal control rats.

Abbreviations: SC - Stratum corneum (keratinized layer)
SM - Stratum mucosum (non-keratinized layer)
SC + SM - Stratum corneum plus stratum mucosum

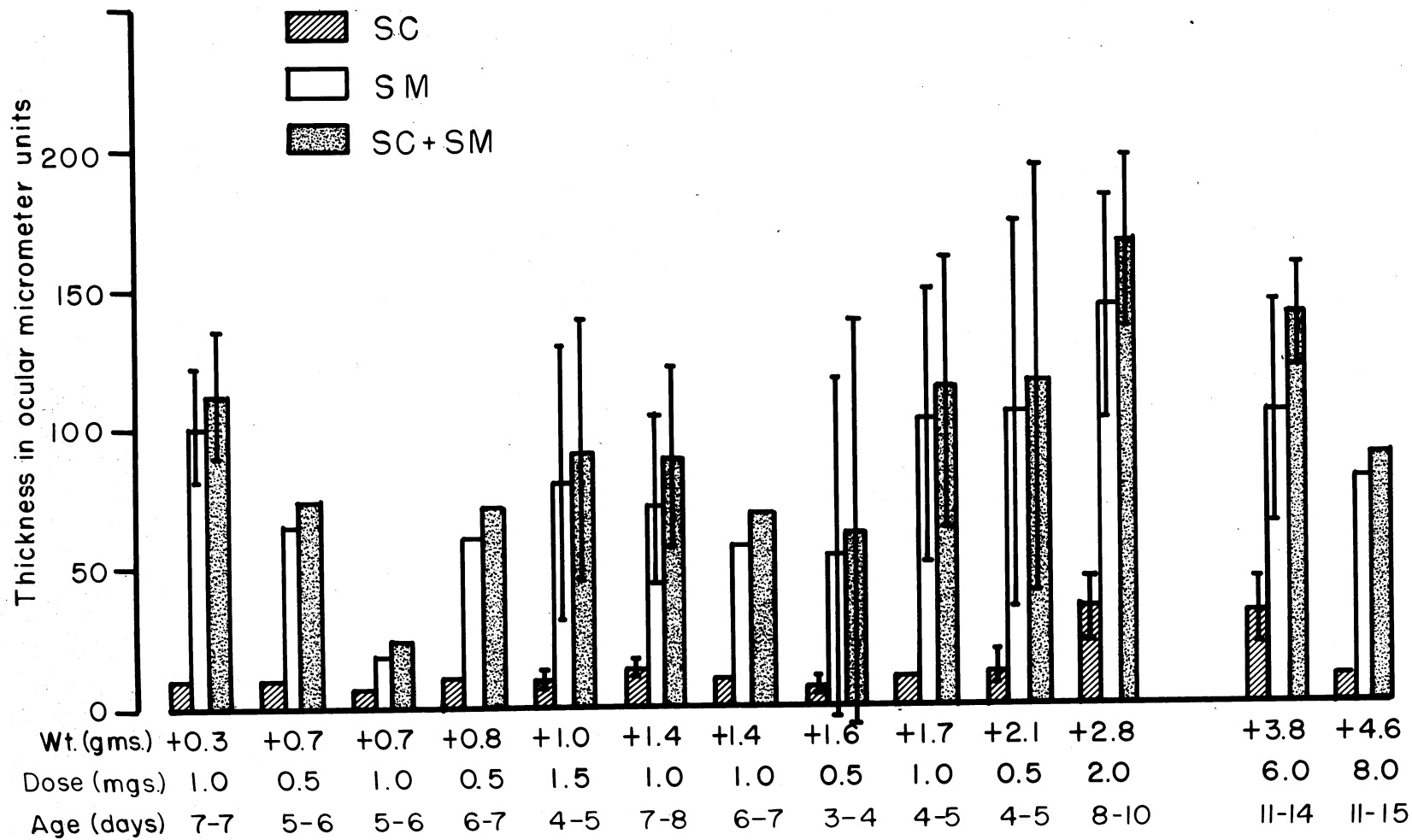


PLATE 3

EXPLANATION OF FIGURE

- 3** Graph showing the effect of cortisone injections on the thickness of the stratum corneum, the stratum mucosum, and the stratum corneum plus the stratum mucosum in the hard palate of young postnatal rats.

Abbreviations: SC - Stratum corneum (keratinized layer)
SM - Stratum mucosum (non-keratinized layer)
SC + SM - Stratum corneum plus stratum
mucosum

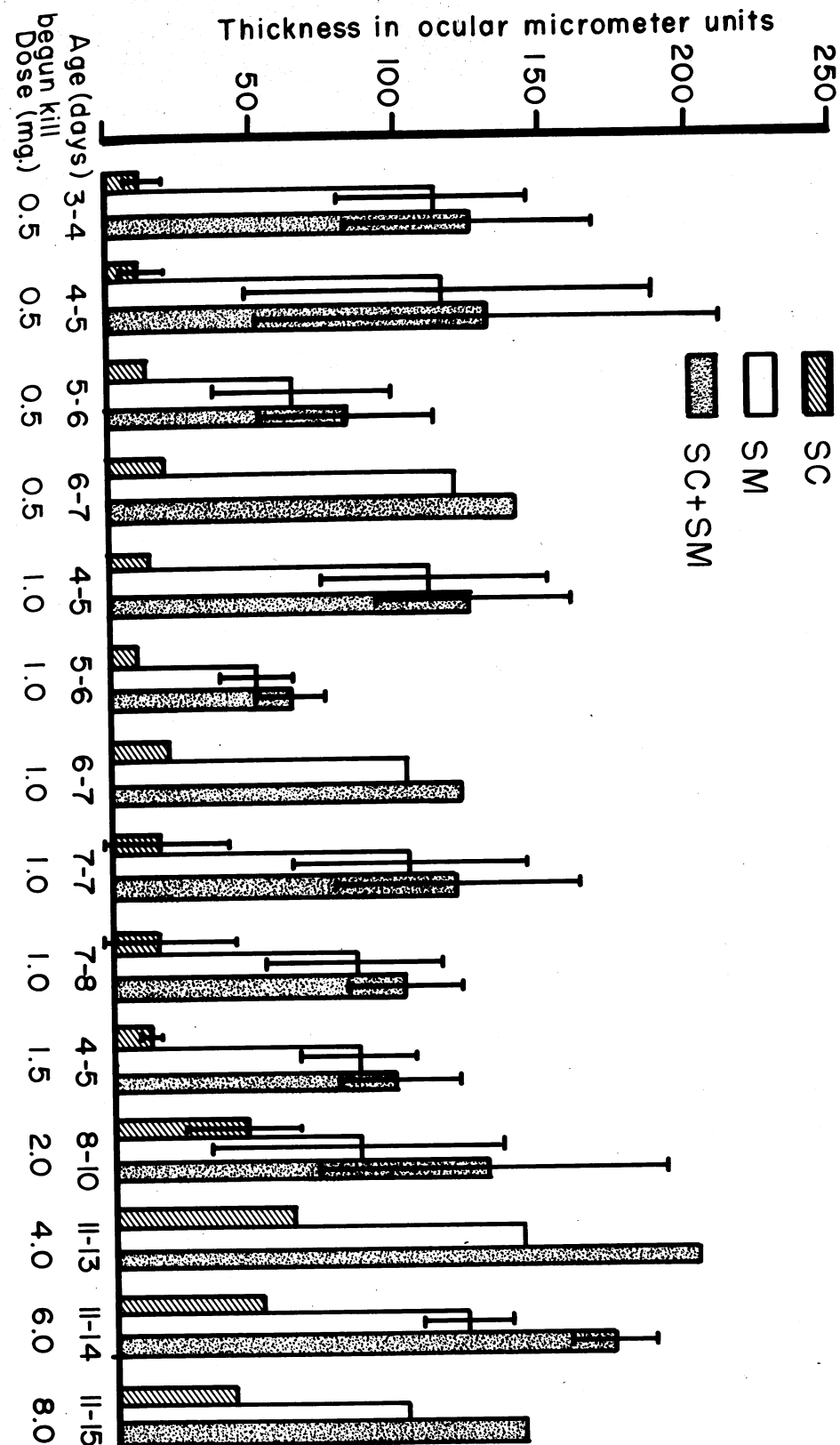


PLATE 4

EXPLANATION OF FIGURE

- 4** Graph showing the thickness of the stratum corneum, the stratum mucosum, and the stratum corneum plus the stratum mucosum of the hard palate in normal young postnatal rats.

Abbreviations: SC - Stratum corneum (keratinized layer)
SM - Stratum mucosum (non-keratinized layer)
SC + SM - Stratum corneum plus stratum
mucosum

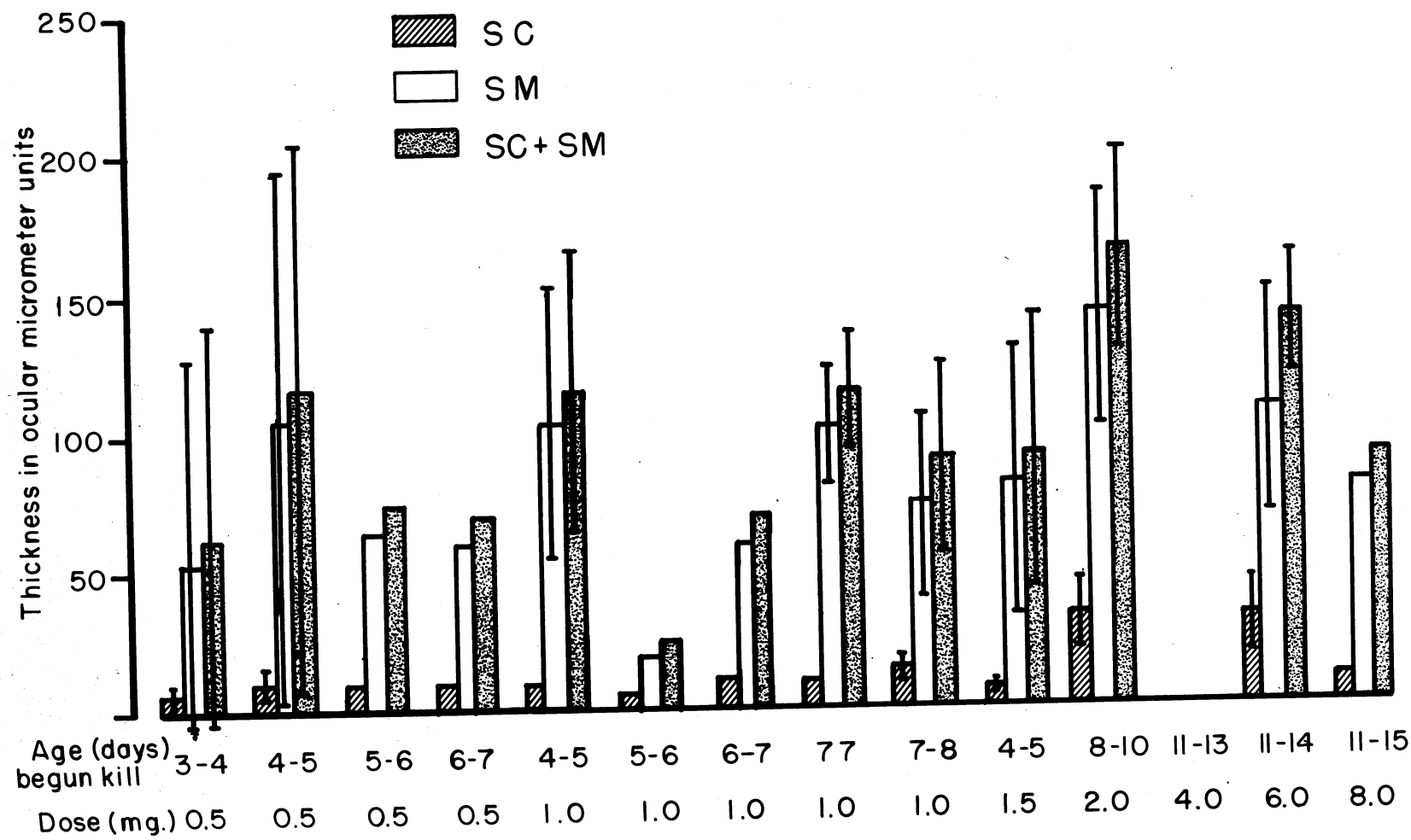


PLATE 5

EXPLANATION OF FIGURE

- 5 Graph showing the effect of cortisone injections on the thickness of the stratum corneum, the stratum mucosum, and the stratum corneum plus the stratum mucosum in the gingiva of young postnatal rats.

Abbreviations: SC - Stratum corneum (keratinized layer)
SM - Stratum mucosum (non-keratinized layer)
SC + SM - Stratum corneum plus stratum
mucosum

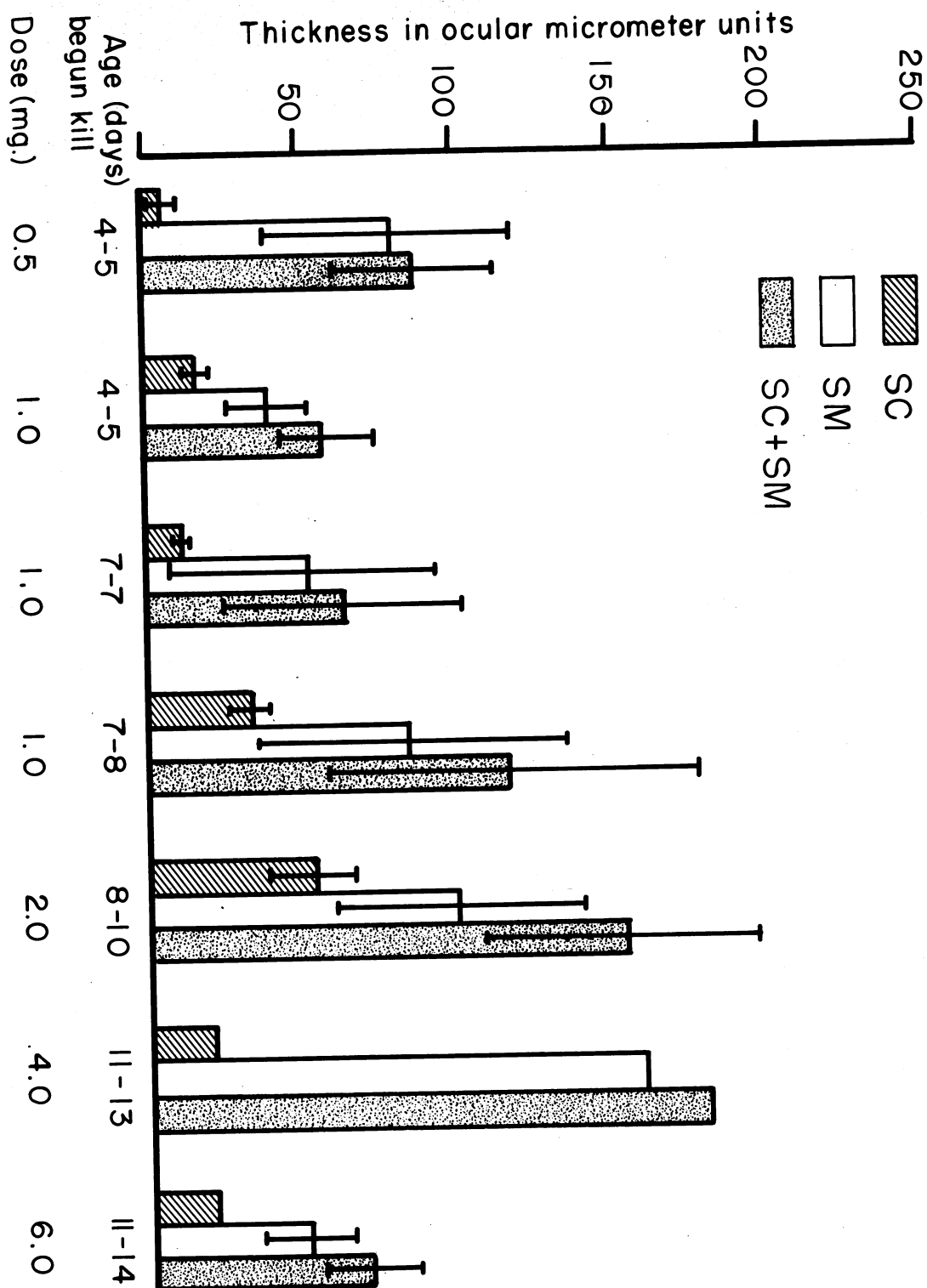


PLATE 6

EXPLANATION OF FIGURE

- 6 Graph showing the thickness of the stratum corneum, the stratum mucosum, and the stratum corneum plus the stratum mucosum of the gingiva in normal young postnatal rats.

Abbreviations: SC - Stratum corneum (keratinized layer)
SM - Stratum mucosum (non-keratinized layer)
SC + SM - Stratum corneum plus stratum
mucosum

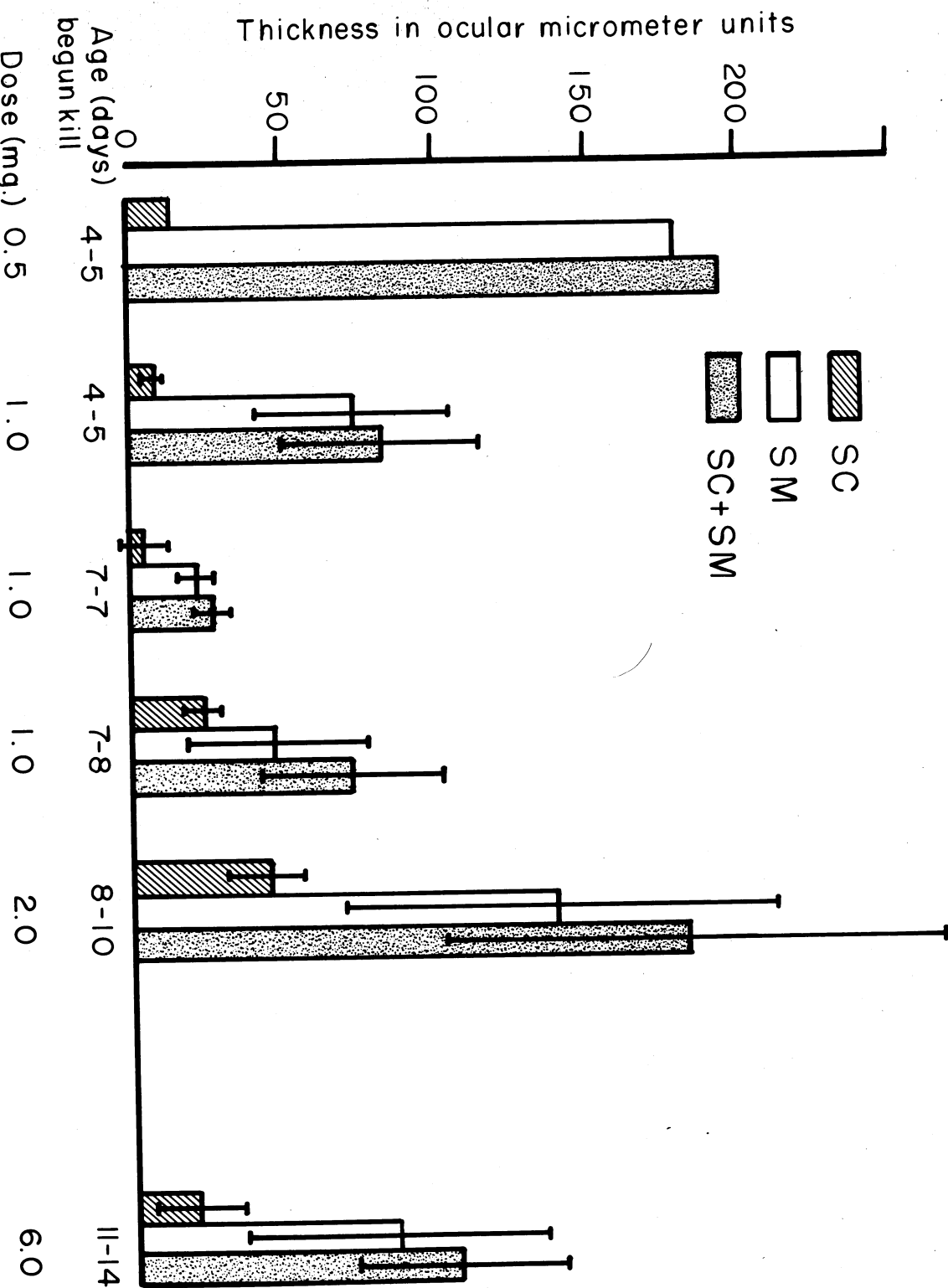


PLATE 7

EXPLANATION OF FIGURES

- 7 The palatal oral epithelium of a normal postnatal rat age 14 days. The animal was 11 days old when the experiment was begun. Note the thin compact layer of stratum corneum as compared to the thicker corresponding layer in figure 8. (x200)
- 8 The palatal oral epithelium of a postnatal rat age 14 days which had received 2 daily injections of cortisone for 3 days beginning on the 11th day after birth. Dosage 1 mg/injection. Note the thick stratum corneum and large granules. (x200)

Abbreviations: SC - Stratum corneum
G - Granules
OC - Oral cavity
SM - Stratum mucosum

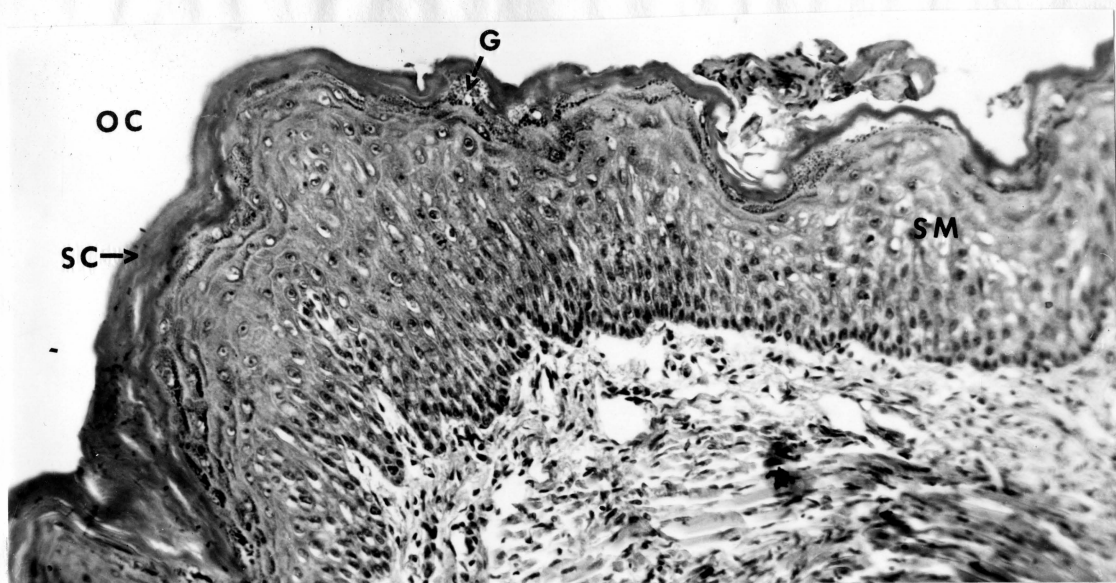


FIGURE 7

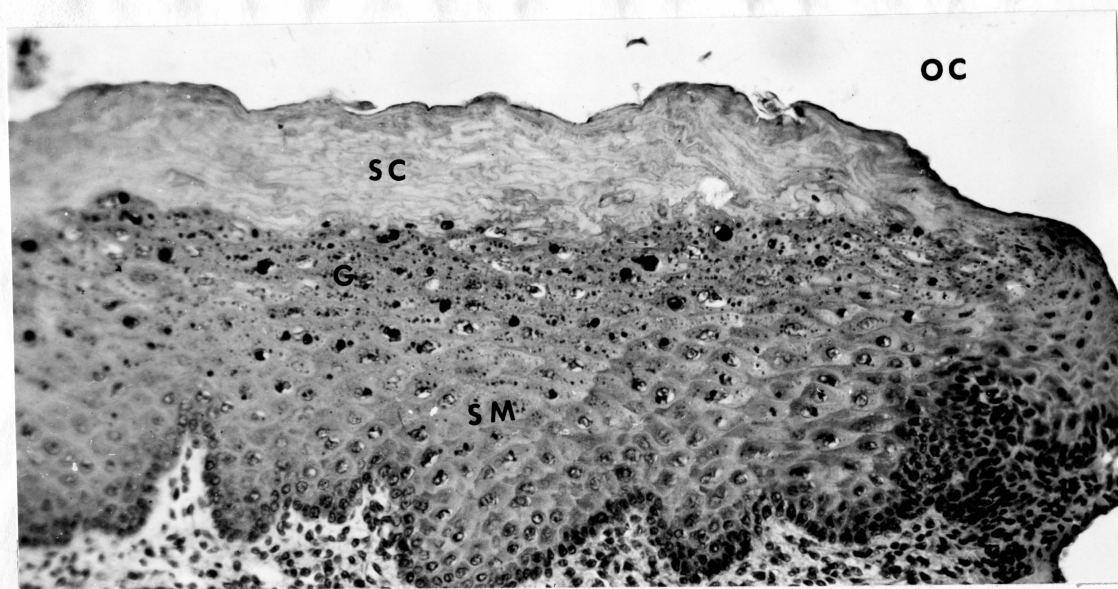


FIGURE 8

PLATE 8

EXPLANATION OF FIGURES

- 9 The palatal oral epithelium of a normal postnatal rat age 15 days. The rat was 11 days old when the experiment was begun. Note the thin stratum corneum and relatively thicker stratum mucosum when compared with the corresponding layer shown in figure 10. (x200)
- 10 The oral epithelium of a postnatal rat age 15 days which had received 2 daily injections of cortisone for 4 days. The dosage was 1 mg/injection starting on the 11th day after birth. Note the thick stratum corneum and relatively thinner stratum mucosum when compared with figure 9. (x200)

Abbreviations: SC - Stratum corneum
G - Granules
OC - Oral cavity
SM - Stratum mucosum

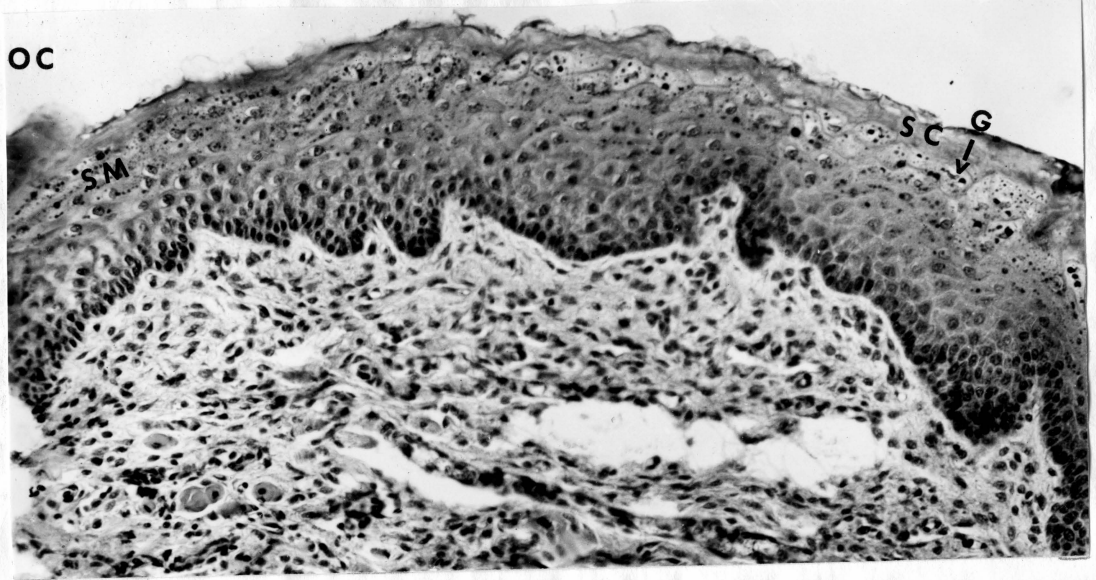


FIGURE 9

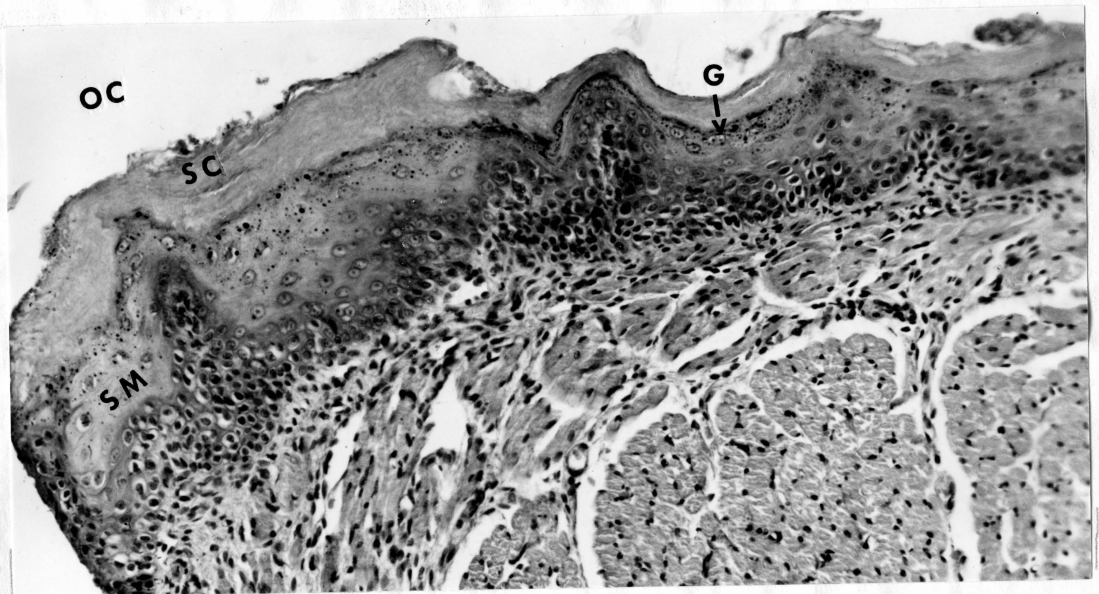


FIGURE 10

PLATE 9

EXPLANATION OF FIGURES

- 11 The oral epithelium of a control postnatal rat age 5 days. The rat was 4 days old when the experiment was begun. Note the compact character of the stratum corneum. (x200)
- 12 The oral epithelium of a postnatal rat age 5 days which had received 1 injection of cortisone. The dosage administered was 1 mg on the 4th day. The animal was sacrificed 19 hours later. Note that the stratum corneum is not as compact as that seen in the control shown in figure 11. (x200)

Abbreviations: SC - Stratum corneum
G - Granules
OC - Oral cavity
SM - Stratum mucosum

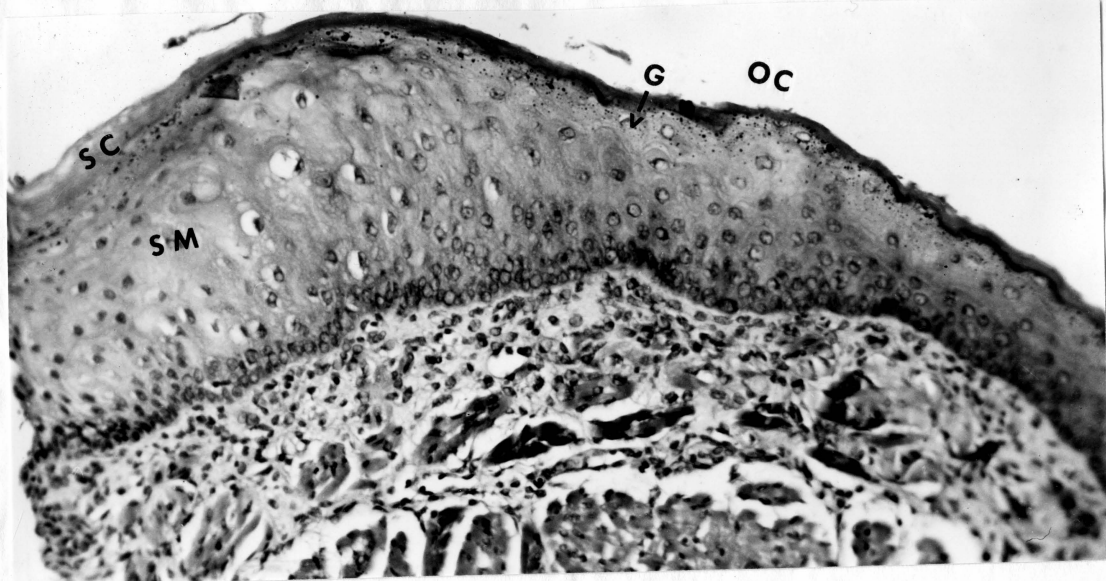


FIGURE 11

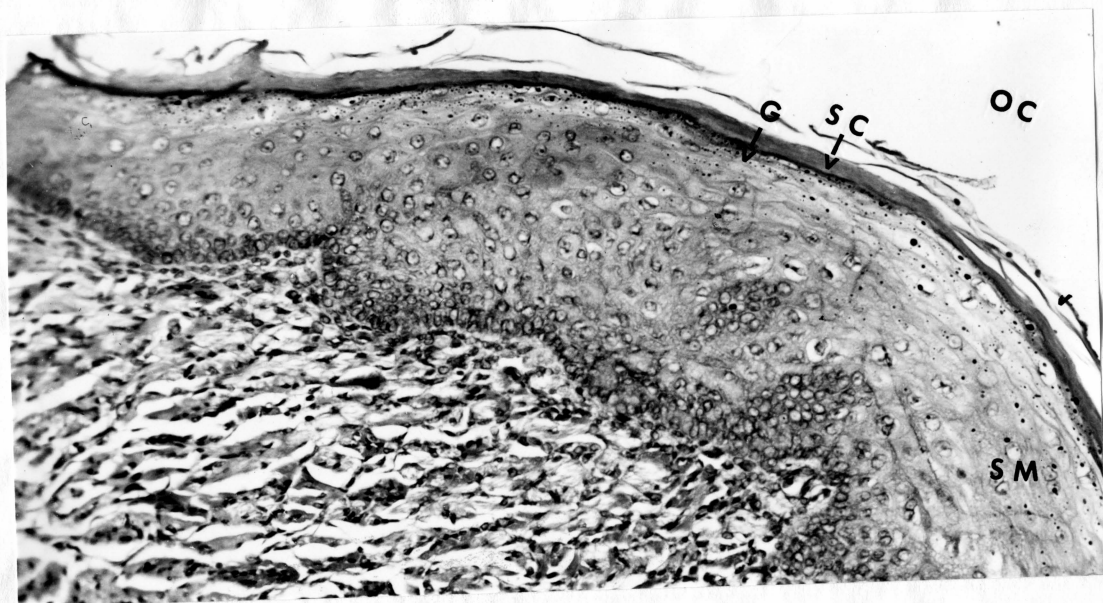

FIGURE 12

PLATE 10

EXPLANATION OF FIGURES

- 13 The oral epithelium of a control postnatal rat age 7 days. Note the thin layer of stratum corneum and thick stratum mucosum. (x200)
- 14 The oral epithelium of a postnatal rat age 7 days which had received 1 injection of cortisone on the 7th day after birth and was sacrificed 8 hours later. The dose administered was 1 mg. Note the thick stratum corneum and thinner stratum mucosum when compared with figure 13. (x200)

Abbreviations: SC - Stratum corneum
G - Granules
OC - Oral cavity
SM - Stratum mucosum

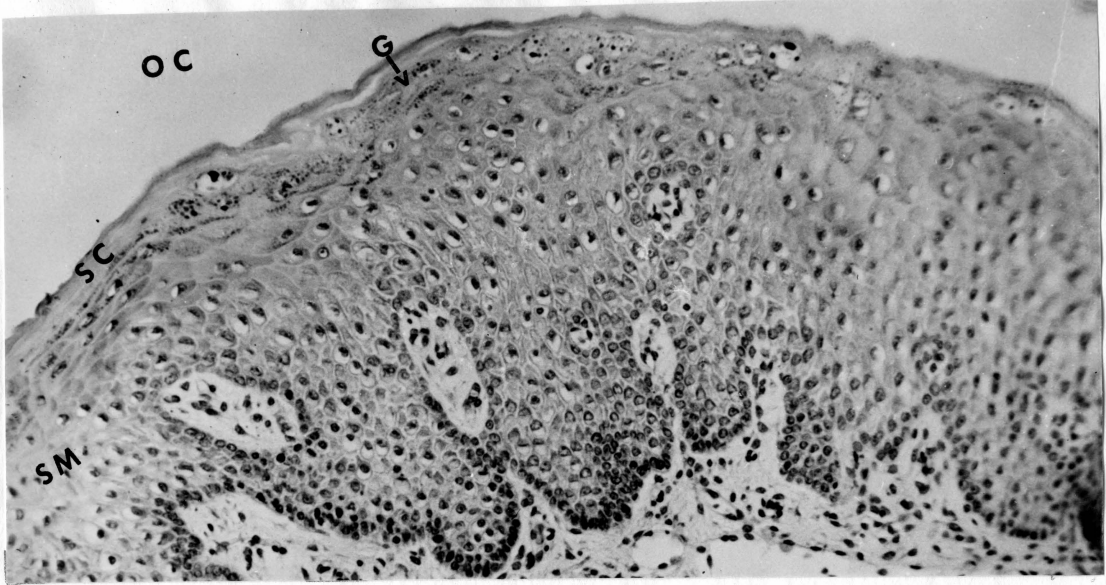


FIGURE 13

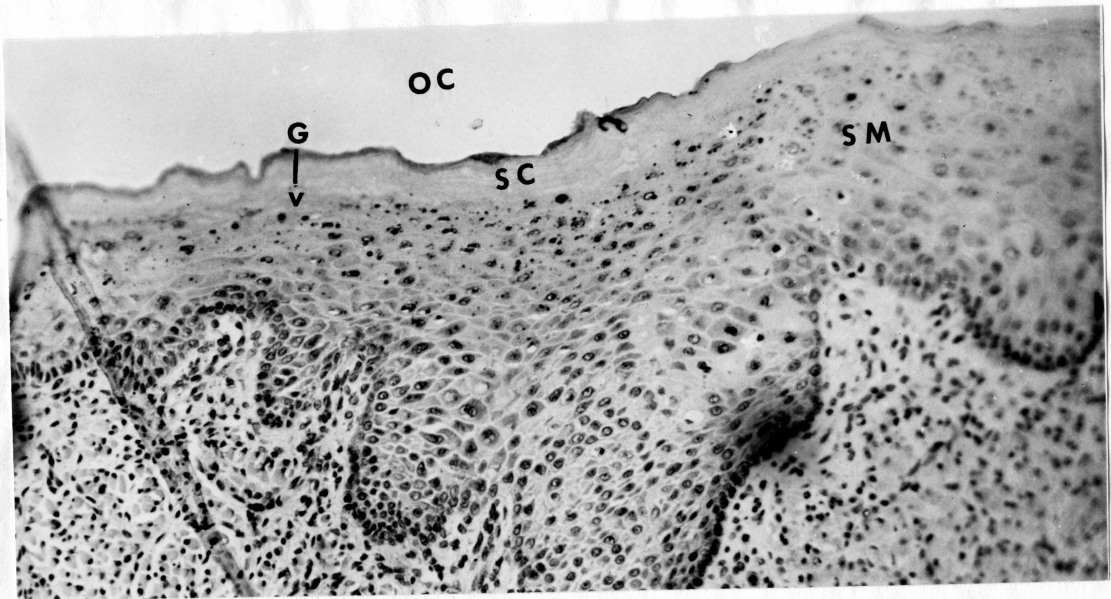


FIGURE 14

PLATE 11

EXPLANATION OF FIGURES

- 15 The oral epithelium of a control postnatal rat age 10 days. The animal was 8 days old when the experiment was begun. Note the thin stratum corneum and thick stratum mucosum when compared with figure 16. (x200)
- 16 The oral epithelium of a postnatal rat age 10 days which had received a total of 2.0 mg of cortisone over a 2 day period. The dose per injection was 0.5 mg twice daily. The experiment was begun on the 8th day after birth. Note the thickened stratum corneum. (x200)

Abbreviations: SC - Stratum corneum
G - Granules
OC - Oral cavity
SM - Stratum mucosum

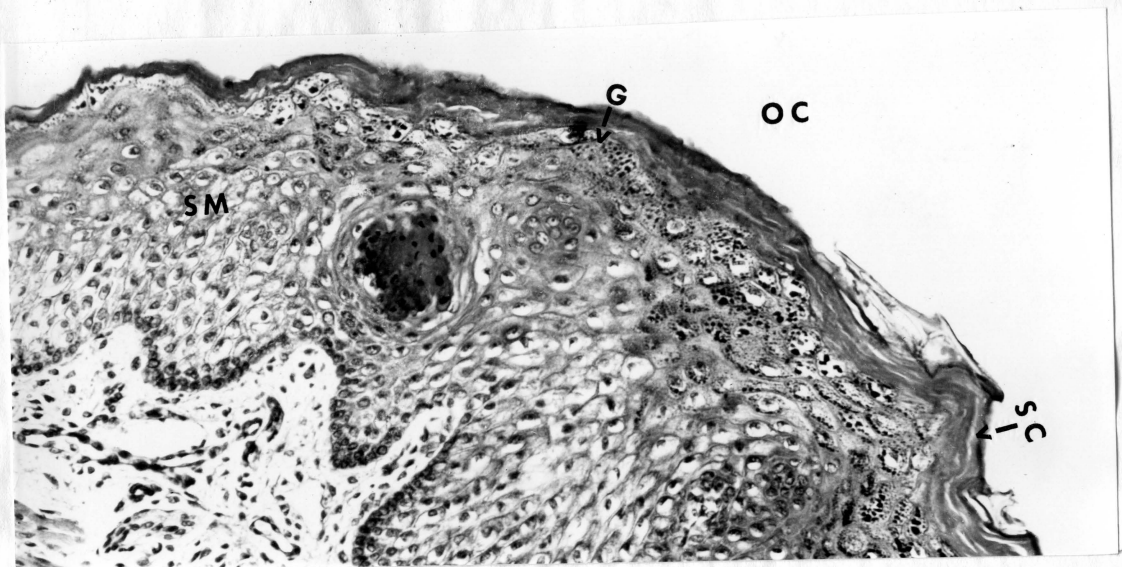


FIGURE 15

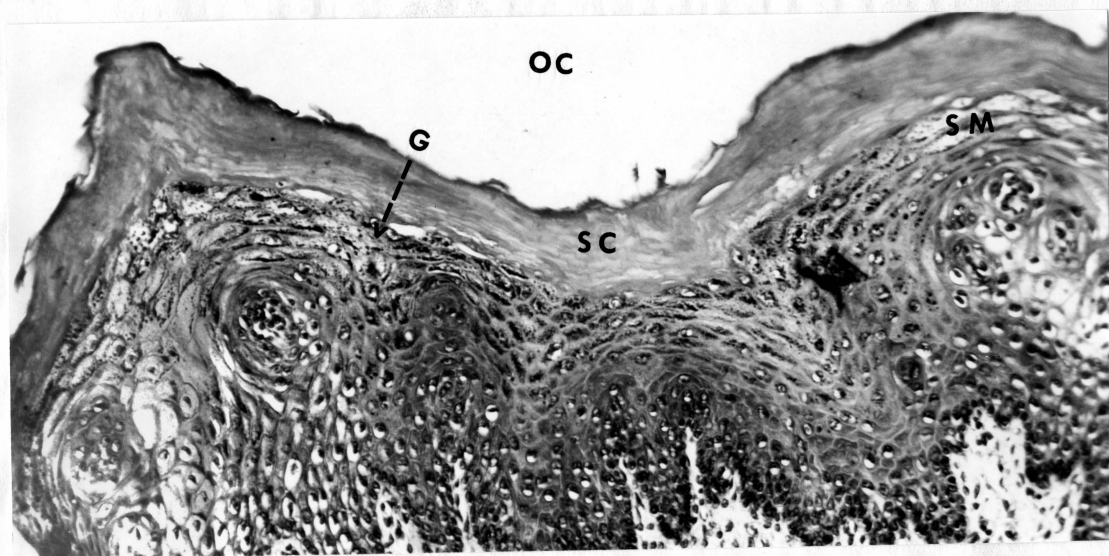


FIGURE 16

PLATE 12

EXPLANATION OF FIGURES

- 17 The gingival oral epithelium of a control postnatal rat age 14 days. The rat was 11 days old when experiment was begun. Note the very thin layer of stratum corneum and thick stratum mucosum. (x200)
- 18 The gingival oral epithelium of a rat age 14 days which had received 2 daily injections of cortisone for 3 days starting on the 11th day after birth. The dosage was 1 mg/injection. Note the thick stratum corneum, the thin stratum mucosum, and the character of the stratum corneum which is not as compact when compared with figure 17. (x200)

Abbreviations: SC - Stratum corneum
G - Granules
OC - Oral cavity
SM - Stratum mucosum

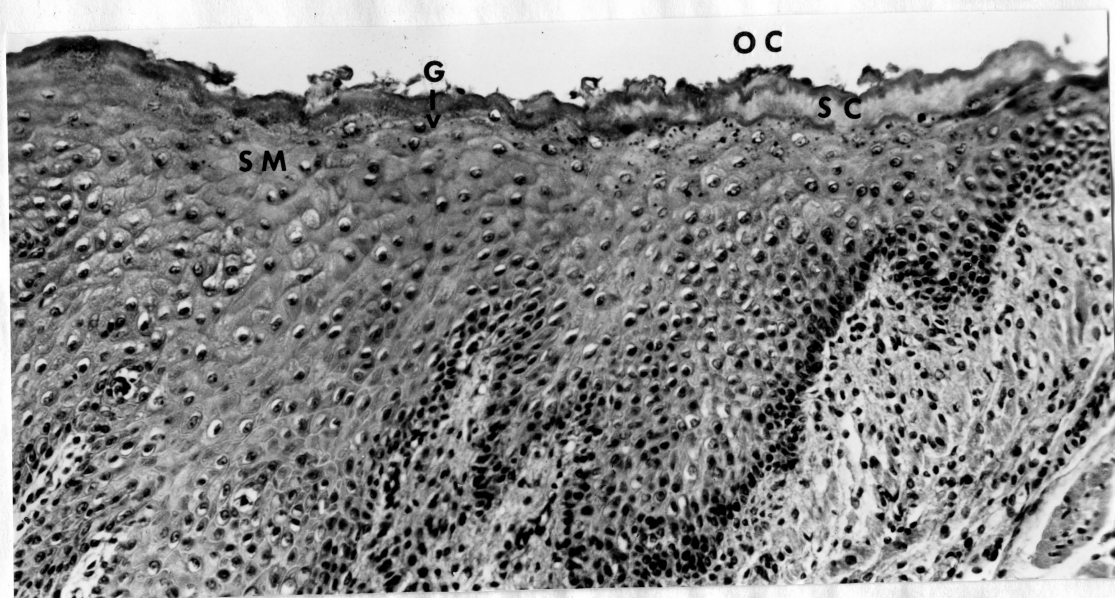


FIGURE 17

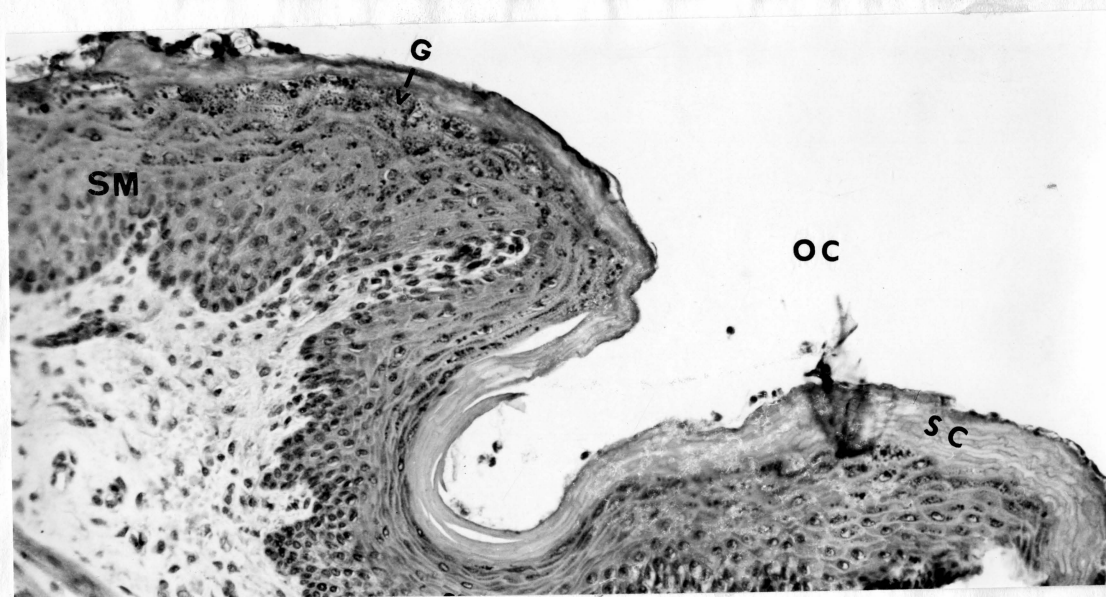


FIGURE 18

APPROVAL SHEET

The dissertation submitted by Diane Grace Mangine has been read and approved by two members of the Department of Anatomy.

The final copies have been examined by the director of the dissertation and the signature which appears below verifies the fact that any necessary changes have been incorporated, and that the dissertation is now given final approval with reference to content, form, and mechanical accuracy.

The dissertation is therefore accepted in partial fulfillment of the requirements for the Degree of Master of Science.

May 29, 1967
Date

L. V. Doremus
Signature of Adviser